

Expression of cytokeratin 34 β E12 is a good indicator of tumor progression in esophageal squamous cell carcinoma

Masashi ONO^{1,2}, Hiroshi KIJIMA², Hiroko SEINO², Kenichi HAKAMADA³, and Yoshinori IGARASHI¹

¹Division of Gastroenterology and Hepatology, Department of Internal Medicine, Toho University Omori Medical Center, Tokyo, Japan;

²Department of Pathology and Bioscience, Hirosaki University Graduates School of Medicine, Aomori, Japan; and ³Department of Surgery, Hirosaki University School of Medicine, Aomori, Japan

(Received 14 March 2012; and accepted 6 April 2012)

ABSTRACT

Esophageal squamous cell carcinoma (ESCC) is considered one of the most aggressive cancers with poor prognosis. The high molecular weight cytokeratin 34 β E12 (CK34 β E12) is recognized by the antibody, that is expressed in the cytoplasm of epithelial basal cells, and has been considered as a potential marker for prostate cancer, breast cancer, and basaloid carcinoma of the lung. However, there are no clinicopathological studies investigating CK34 β E12 expression at the invasive front of ESCC. In this study, we examined 170 surgically resected cases of ESCC to clarify the clinicopathological significance of CK34 β E12 expression. CK34 β E12 expression was found in 85.3% (145/170) of ESCC cases and was significantly correlated with lymph node metastasis (66.2% [96/145], $P = 0.034$), depth of tumor invasion (57.9% [84/145], $P = 0.042$), and differentiation (82.1% [119/145], $P = 0.013$). These results indicated that CK34 β E12 expression is a good indicator of lymph node metastasis, depth of tumor invasion, and differentiation in case of ESCC.

Esophageal squamous cell carcinoma (ESCC) exhibits geographic and ethnic variation throughout the world, with the highest incidences (> 50 per 100,000 population) recorded in northern Islamic Republic of Iran, various provinces of eastern China (Henan, Jiangsu, and Shanxi), and certain areas of Kazakhstan (2). The prognosis for patients with ESCC is poor, and 5-year survival rates are about 10% (2). In Japan, > 90% of all esophageal cancers are squamous cell carcinomas (6), and the incidence of esophageal cancer is 20.0 per 100,000 population in males and 3.8 in females (13), with the mortality rate of 15.4 per 100,000 population in males and 2.7 in females (15). Despite advanced surgical strategies and postoperative management, ESCC is considered

one of the most aggressive cancers with poor prognosis (1, 17). One reason for the poor survival rate is that most patients present with advanced stages of the disease and lymph node metastasis, even in the early phase of esophageal wall invasion (8). The lymph node metastasis is the crucial parameter for predicting survival (10, 25, 28). The spread of cancer cells through the lymphatic system to regional lymph nodes is an important early event during tumor progression, and lymph node metastasis is an important factor in the staging of human cancers (21, 23). Moreover, depth of invasion and presence of nodal or distant metastases are independent predictors of survival in ESCC patients (7, 9, 12).

Cytokeratin is one of the main structural proteins about the human epithelial cell, and divided into the two groups; acidic type (type 1) and a (neutral-to-) basic type (type 2). Moreover, cytokeratin is classified into the two groups about the molecular weight. The low molecular weight protein groups are 40 to 54 kD: CK7, 8, 17–20, and the high molecular weight protein groups are 48 to 67 kD: CK1–6, 9–16 (3).

Address correspondence to: Hiroshi Kijima, MD,
Department of Pathology and Bioscience, Hirosaki University Graduates School of Medicine, 5 Zaifu-cho,
Hirosaki, Aomori, 036-8562, Japan
Tel: +81-172-39-5029, Fax: +81-172-39-5030
E-mail: hkijima@cc.hirosaki-u.ac.jp

The high molecular weight cytokeratin 34 β E12 (CK34 β E12) is recognized by the antibody, that is identified as human cytokeratins 1, 5, 10, and 14 of Moll's catalogue (16), is useful for the detection of epithelial basal cells, such as prostatic basal cells, and stratified squamous epithelium. CK34 β E12 is expressed in the cytoplasm of basal cells, and has been used as a marker of the basal layer to distinguish benign from malignant processes in prostate cancer (5, 27), breast cancer (14, 22), and basaloid carcinomas of the lung (24). Although a correlation between primary small cell carcinomas of the esophagus and CK34 β E12 has been studied (11, 29), no studies have investigated CK34 β E12 expression at the invasive front of ESCC. In this study, we report the clinicopathological relationship of CK34 β E12 in ESCC.

MATERIALS AND METHODS

Patient and tissue samples. All tissue specimens were obtained from surgically resected ESCCs at the Hirosaki University Hospital with informed consent from the patients. All patients underwent subtotal esophagectomy and dissection of lymph nodes. In this study, we examined 170 patients (153 males and 17 females) with a mean age of 64.5 years (range, 37–83 years). All patients were diagnosed with esophageal cancer, of which 53 patients had superficial cancers (mucosal or submucosa-invasive cancer) and 117 patients had advanced cancers (invades beyond the muscularis propria). Curative resection and regional lymph node dissection depended on the location of the primary tumors.

Histopathological and immunohistochemical examinations. For histological examination, ESCC tissue specimens were routinely fixed with formalin, embedded in paraffin, thin-sectioned, and stained with hematoxylin and eosin (H&E). The pathological stage of each case at the time of operation was defined according to the TNM classification (22), and the lesions were graded histologically according to the Guidelines for Clinical and Pathologic Studies on Carcinoma of the Esophagus (26). The TNM (tumor, node, metastasis) system with its four degrees of T, three degrees of N, and two degrees of M. T categories divided into following four groups: T1, tumor invades lamina propria or submucosa; T2, tumor invades into, but not beyond, the muscularis mucosa; T3, tumor invades the adventitia; T4, tumor invades adjacent structures. Moreover, M categories divided into following two groups: M0, no distant

metastases; M1, distant metastases (22). The degree of lymphatic, venous invasion was classified as: 0, no invasion; 1, mild invasion; 2, moderate invasion; and 3, severe invasion according to the Guidelines for Clinical and Pathologic Studies on Carcinoma of the Esophagus. The patterns of infiltrative growth pattern (INF) were classified into the three groups: INFa, the tumor shows expanding growth and a distinct border from the surrounding tissue; INFb, the tumor shows intermediate growth between INFa and INFc; INFc, the tumor shows schirrhous growth and an indistinct border with the surrounding tissue (18).

In each patient, one representative histological specimen at the deepest invaded area of the esophageal cancer lesion was selected for immunohistochemistry. Paraffin sections measuring 4 μ m in thickness were mounted on silane-coated glass slides. Immunohistochemical examination was performed on deparaffinized sections using the standard avidin-biotin-peroxidase complex (ABC) method with an automated immunostainer (Benchmark XT; Ventana Medical Systems, Tucson, AZ), using anti-human CK (clone 34 β E12, mouse monoclonal, 1 : 50 dilution; DakoCytomation, Denmark). Heat-induced antigen retrieval was performed for each section.

Immunohistochemical evaluation. Two investigators (OM and KH) simultaneously assessed the immunostaining results without previous knowledge of the patients' clinicopathological details. Expression of CK34 β E12 was evaluated at the invasive front of each tumor, given a score, and divided into following four groups: Score 0, no reactivity or faint reactivity in < 10% of tumor cells. Score 1+, faint or barely perceptible cytoplasmic reactivity in \geq 10% of tumor cells. Score 2+, moderate and focal cytoplasmic reactivity in \geq 10% of tumor cells. Score 3+, throughout the cytoplasm is stained in \geq 10% of tumor cells (Fig. 1). Moreover, CK34 β E12 is expressed in basal and spinous layers of normal stratified squamous epithelium (Fig. 1).

Statistical analysis. Univariate statistical analysis was performed using the Pearson chi-square test or Fisher's exact test. The *P* values were two-sided, and *P* values of < 0.05 were considered statistically significant. All statistical analyses were performed using the SPSS Software (version 17.0; SPSS, Inc., Chicago, IL).

RESULTS

We detected positive CK34 β E12 expression in

85.3% (145/170) of the primary ESCCs examined. Typical immunohistochemical expression patterns of CK34 β E12 are demonstrated in Fig. 1. CK34 β E12 expression was predominantly detected at the cell membrane and/or in the cytoplasm of tumor cells. In 97.9% (142/145) of CK34 β E12-positive cases, expression was detected at the invasive front as well as in the majority of tumor cells, whereas only 3 cases did not show expression at the invasive front. These results suggested that majority of CK34 β E12-positive cells are located at the tumor invasive front.

The results of univariate analysis between lymph node metastasis and clinicopathological factors, including CK34 β E12 expressions, are summarized in Table 1. Lymph node metastasis was observed in 62.9% (107/170) cases. The gender and mean age were not significantly different ($P = 0.368$ and $P = 0.381$, respectively). ESCCs with lymph node metastasis exhibited significant differences in depth of tumor invasion, lymphatic invasion, infiltrative growth pattern (INF), and distant organ metastasis (pM) ($P = 0.003$, $P = 0.001$, $P < 0.001$, and $P < 0.001$,

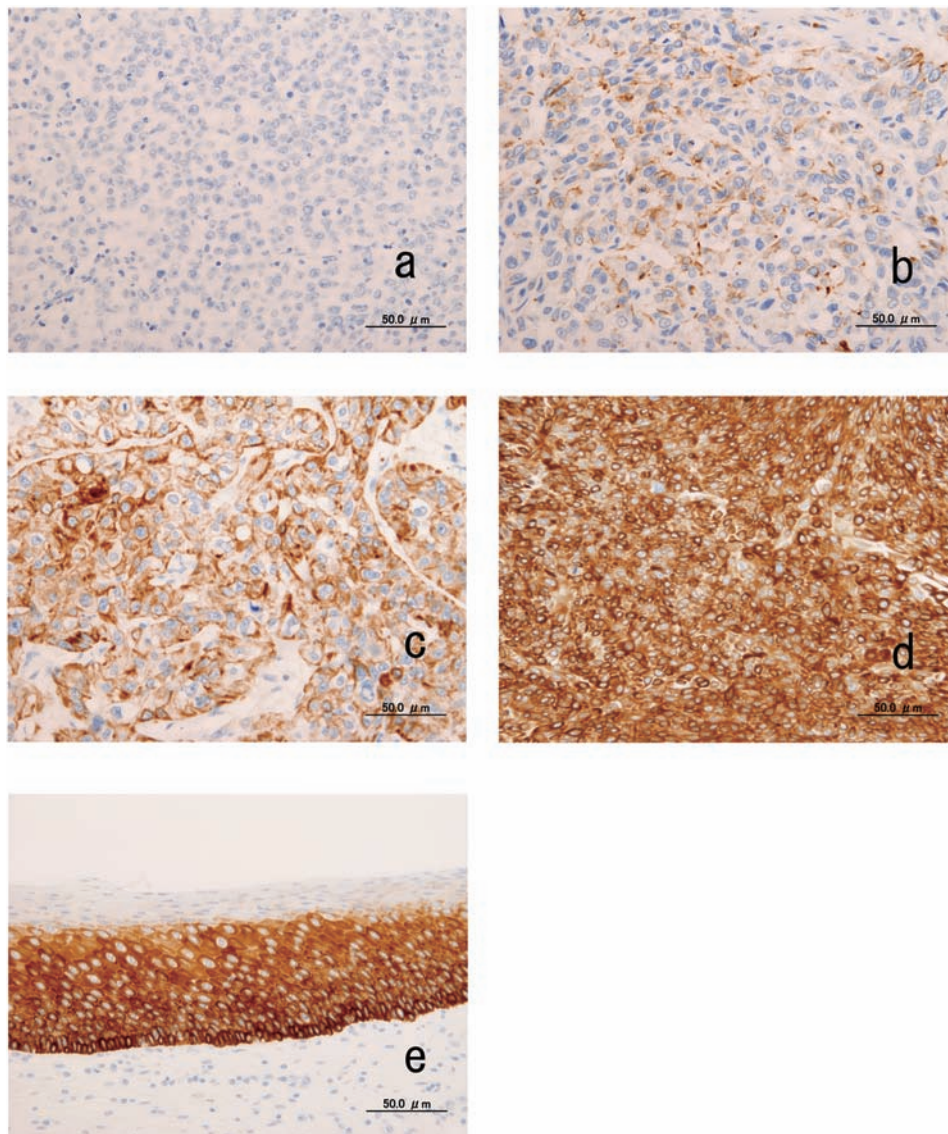


Fig. 1 Immunohistochemical analysis of CK34 β E12 expression in esophageal squamous cell carcinoma (ESCC) and normal stratified squamous epithelium. (a) Score 0: no reactivity or faint reactivity in $< 10\%$ of tumor cells. (b) Score 1+: faint or barely perceptible cytoplasmic reactivity in $\geq 10\%$ of tumor cells. (c) Score 2+: moderate and focal cytoplasmic reactivity in $\geq 10\%$ of tumor cells. (d) Score 3+: whole cytoplasm is stained in $\geq 10\%$ of tumor cells. (e) Normal stratified squamous cell epithelium. Basal and spinous layers have positive expression.

Table 1 Lymph node metastasis and clinicopathological factors of esophageal squamous cell carcinoma (n = 170)

	No. of Patients	Lymph node metastasis		P
		Positive (n = 107)	Negative (n = 63)	
Gender				0.368
	Male	153	98	55
	Female	17	9	8
Age (years)				0.381
	< 65	83	55	28
	≥ 65	87	52	35
pT categories*				0.003***
	T1 & T2	77	39	38
	T3 & T4	93	68	25
Differentiation				0.301
	poor	36	20	16
	well & mod	134	87	47
Lymphatic invasion**				0.001***
	ly0 & 1	86	44	42
	ly2 & 3	84	63	21
Vessel invasion				0.237
	v0 & 1	98	58	40
	v2 & 3	72	49	23
INF				< 0.001***
	a	29	10	19
	b & c	141	97	44
pM				< 0.001***
	0	141	79	62
	1	29	28	1
CK34βE12				0.034***
	0 & 1	25	11	14
	2 & 3	145	96	49

*T1/T2, T3/T4; depth of tumor invasion, according to TNM classification.

**ly0, 1, 2, 3; v0, 1, 2, 3; INFa, b, c: according to the Guidelines for Clinical and Pathologic Studies on Carcinoma of the Esophagus.

***Statistically significant difference.

respectively), but exhibited no significant differences in venous invasion and histological differentiation. The cases also revealed CK34βE12 expression (Score 2 and 3) to be a significant indicator of the incidence of lymph node metastasis ($P = 0.034$).

The results of CK34βE12 expression (Score 2 and 3) in primary tumors are summarized in Table 2. Positive CK34βE12 expression was identified in 85.3% (145/170) cases, with no significant differences in gender and mean age ($P = 0.139$ and $P = 0.437$, respectively). ESCCs with CK34βE12 expression exhibited significant differences in lymph node metastasis, depth of tumor invasion, and differentiation ($P = 0.034$, $P = 0.042$, and $P = 0.013$, respectively), but exhibited no significant difference in lymphatic/venous invasion, INF, and pM. There was a tendency that CK34βE12-positive cases corre-

sponded to well or moderately differentiated squamous cell carcinoma, whereas the CK34βE12-negative cases corresponded to poorly differentiated squamous cell carcinoma.

DISCUSSION

CK34βE12 has been studied as potential marker for urothelial cancer, breast cancer, and basaloid carcinoma of the lung (5, 14, 19, 24, 27). It was shown that primary small cell carcinoma of the esophagus correlated with CK34βE12 expression (29); however, the relevance and expression of CK34βE12 in carcinoma cells have not yet been clarified in ordinary ESCC. This is the first study to demonstrate that CK34βE12 expression is a good indicator of lymph node metastasis in ESCC.

Table 2 CK34βE12 expression and clinicopathological factors of esophageal squamous cell carcinoma (n = 170)

		No. of Patients	CK34βE12		P
			Positive (n = 145)	Negative (n = 25)	
Gender					0.139
	Male	153	133	20	
	Female	17	12	5	
Age (years)					0.437
	< 65	83	69	14	
	≥ 65	87	76	11	
Lymph node metastasis					0.034***
	(-): negative	63	49	14	
	(+): positive	107	96	11	
pT categories*					0.042***
	T1 & T2	77	61	16	
	T3 & T4	93	84	9	
Differentiation					0.013***
	poor	36	26	10	
	well & mod	134	119	15	
Lymphatic invasion**					0.146
	ly0 & 1	86	70	16	
	ly2 & 3	84	75	9	
Vessel invasion					0.116
	v0 & 1	98	80	18	
	v2 & 3	72	65	7	
INF					0.773
	a	29	24	5	
	b & c	141	121	20	
pM					0.576
	0	141	119	22	
	1	29	26	3	

*T1/T2, T3/T4; depth of tumor invasion, according to TNM classification.

**ly0, 1, 2, 3; v0, 1, 2, 3; INFa, b, c: according to the Guidelines for Clinical and Pathologic Studies on Carcinoma of the Esophagus.

***Statistically significant difference.

Our statistical analysis showed that ESCCs with lymph node metastasis were significantly different in depth of tumor invasion, lymphatic invasion, INF, and pM ($P = 0.003$, $P = 0.001$, $P < 0.001$, and $P < 0.001$, respectively). In addition, our study revealed CK34βE12-positive carcinoma cells to be a significant factor for lymph node metastasis ($P = 0.034$). In ESCC, lymph node metastasis is the crucial parameter for predicting survival (10, 25, 28). Our study demonstrated that lymph node metastasis exhibited a varying correlation with clinicopathological factors and CK34βE12 expression in ESCC.

Other than lymph node metastasis, our results indicate that CK34βE12 expression in ESCC was significantly associated with depth of tumor invasion, and differentiation ($P = 0.042$, and $P = 0.013$, respectively), but showed no significant differences

in lymphatic/venous invasion, INF, and pM. Depth of tumor invasion and presence of nodal or distant metastases have been shown to be independent predictors of survival in ESCC patients (7, 9, 12), although histological differentiation is a poor prognostic factor. ESCC grading has traditionally been based on parameters of mitotic activity, nuclear atypia, and degree of squamous differentiation. However, according to the American Joint Committee on Cancer 2009 prognostic groupings (4), grading is a controversial method to determine prognosis (23). Our present study demonstrated that CK34βE12 expression, as well as lymph node metastasis and depth of tumor invasion, can be considered as good prognostic indicators of ESCC.

In the present study, CK34βE12 expression was detected at the invasive front and the majority of tu-

mor cell membranes and cytoplasm. Histologically, the normal esophagus is lined by 500- to 800- μ m thick mucosa, composed of non-keratinizing stratified squamous epithelium with subjacent lamina propria, which rests on the underlying muscularis mucosae. The stratified squamous epithelium has a basal layer and spinous layer. The basal layer and spinous layer in the stratified squamous epithelium normally express CK34 β E12. When the cancer becomes advanced, cell proliferation occurs predominantly in the basal layer and the invasive front at the vertically deep areas, leading to a correlation between CK34 β E12 expression and depth of tumor invasion. Interestingly, CK34 β E12 is expressed in not only normal basal layer and spinous layer of stratified squamous epithelium, but also the cancer cells in ESCC.

In conclusion, we demonstrated that CK34 β E12 expressed in the invasive areas of human ESCC is significantly correlated with lymph node metastasis, depth of tumor invasion, and differentiation. Lymph node metastasis and depth of tumor invasion are crucial parameters for predicting survival. Taken together, our findings suggest CK34 β E12 to be a novel histological indicator of ESCC.

REFERENCES

- Ando N, Ozawa S, Kitagawa Y, Shinozawa Y and Kitajima M (2000) Improvement in the results of surgical treatment of advanced squamous esophageal carcinoma during 15 consecutive years. *Ann Surg* **232**, 225–232.
- Bosman FT, Carneiro F, Hruban RH and Theise ND (2009) *WHO Classification of Tumours of the Digestive System*. 4th Edition. IARC Press, Lyon.
- Cooper D, Schermer A and Sun TT (1985) Classification of human epithelia and their neoplasms using monoclonal antibodies to keratins: strategies, applications, and limitations. *Lab Invest* **52**, 243–256.
- Edge SB, Byrd DR, Compton CC, Fritz AG, Greene FL and Trotti A (2009) *AJCC Cancer Staging Manual*. Springer, New York.
- Hedrick L and Epstein JI (1989) Use of keratin 903 as an adjunct in the diagnosis of prostatic carcinoma. *Am J Surg Pathol* **13**, 389–396.
- Hongo M, Nagasaki Y and Shoji T (2009) Epidemiology of esophageal cancer: orient to occident. Effects of chronology, geography and ethnicity. *J Gastroenterol Hepathol* **24**, 729–735.
- Ide H, Nakamura T, Hayashi K, Endo T, Kobayashi A, Eguchi R and Hanyu F (1994) Esophageal squamous cell carcinoma: pathology and prognosis. *World J Surg* **18**, 321–330.
- Igaki H, Kato H, Tachimori Y, Sato H, Daiko H and Nakanishi Y (2001) Prognostic evaluation for squamous cell carcinomas of the lower thoracic esophagus treated with three-field lymph node dissection. *Eur J Cardiothorac Surg* **19**, 887–893.
- Kato H, Tachimori Y, Watanabe H and Iizuka T (1993) Evaluation of the new (1987) TNM classification for thoracic esophageal tumors. *Int J Cancer* **53**, 220–223.
- Kolh P, Honore P, Gielen JL, Degauque C, Azzam C, Legrand M and Jacquet N (1999) Analysis of factors influencing long-term survival after surgical resection for oesophageal squamous cell carcinoma. *Acta Chir Belg* **99**, 113–118.
- Lu J, Xue LY, Lu N, Zou SM, Liu XY and Wen P (2010) Superficial primary small cell carcinoma of the esophagus: clinicopathological and immunohistochemical analysis of 15 cases. *Dis Esophagus* **23**, 153–159.
- Lu YK, Li YM and Gu YZ (1987) Cancer of esophagus and esophagogastric junction: analysis of results of 1,025 resections after 5 to 20 years. *Ann Thorac Surg* **43**, 176–181.
- Matsuda T, Marugame T, Kamo K, Katanoda K, Ajiki W and Sobue T; Japan Cancer Surveillance Research Group (2008) Cancer incidence and incidence rates in Japan in 2002: based on data from 11 population-based cancer registries. *Jpn J Clin Oncol* **38**, 641–648.
- Mehta R, Jain RK, Sneige N, Badve S and Resetkova E (2010) Expression on high-molecular-weight cytokeratin (34betaE12) is an independent predictor of disease-free survival in patients with triple-negative tumors of the breast. *J Clin Pathol* **63**, 744–747.
- Ministry of Health, Labour and Welfare (2005) *Vital Statistics of Japan*. <http://mhlw.go.jp/toukei/saikin/hw/jinkou/suii05/index.html>
- Moll R, Franke WW and Schiller DL (1982) The catalog of human cytokeratins: patterns of expression in normal epithelia, tumors and cultured cells. *Cell* **31**, 11–24.
- Morita M, Yoshida R, Ikeda K, Egashira A, Oki E, Sadanage N, Kakeji Y, Yamanaka T and Maehara Y (2008) Advances in esophageal cancer surgery in Japan: an analysis of 1000 consecutive patients treated at a single institute. *Surgery* **143**, 499–508.
- Okada K, Kijima H, Imaizumi T, Hirabayashi K, Matsuyama M, Yazawa N, Oida Y, Dowaki S, Tobita K, Ohtani Y, Tanaka M, Inokuchi S and Makuuchi H (2009) Stromal laminin-5gamma2 chain expression is associated with the wall-invasion pattern of gallbladder adenocarcinoma. *Biomed Res* **30**, 53–62.
- Raju U, Crissman JD, Zarbo RJ and Gottlieb C (1990) Epitheliosis of the breast. An immunohistochemical characterization and comparison to malignant intraductal proliferations of the breast. *Am J Surg Pathol* **14**, 939–947.
- Sarbia M, Bittinger F, Porschen R, Dutkowski P, Willers R and Gabbert HE (1995) Prognostic value of histopathologic parameters of esophageal squamous cell carcinoma. *Cancer* **76**, 922–927.
- Sleeman JP (2000) The lymph node as a bridgehead in the metastatic dissemination of tumors. *Recent Results Cancer Res* **157**, 55–81.
- Sobin LH and Wittekind CH (2002) *TNM Classification of Cancer (UICC)*. Wiler-Liss, New York.
- Stacker SA, Achen MG, Jussila L, Baldwin ME and Alitalo K (2002) Lymphangiogenesis and cancer metastasis. *Nat Rev Cancer* **2**, 573–583.
- Sturm N, Lantuéjoul S, Laverrière MH, Papotti M, Brichon PY, Brambilla C and Brambilla E (2001) Thyroid transcription factor 1 and cytokeratins 1, 5, 10, 14 (34betaE12) expression in basaloid and large-cell neuroendocrine carcinomas of the lung. *Hum Pathol* **32**, 918–925.
- Tachikawa D, Inada S, Kotoh T, Futami K, Arita S and Iwashita A (1999) An evaluation of malignancy and prognostic factors based on mode of lymph node metastasis in

- esophageal carcinoma. *Surg Today* **29**, 1131–1135.
26. The Japan Esophageal Society (2007) *Guide Lines for the Clinical and Pathologic Studies on Carcinoma of the Esophagus*. 10th Edition. Kanehara Press Inc., Tokyo.
 27. Varma M, Morgan M, Amin MB, Wozniak S and Jasani B (2003) High molecular weight cytokeratin antibody (clone 34betaE12): a sensitive marker for differentiation of high-grade invasive urothelial carcinoma from prostate cancer. *Histopathology* **42**, 167–172.
 28. Wang LS, Chow KC, Chi KH, Liu CC, Li WY, Chiu JH and Huang MH (1999) Prognosis of esophageal squamous cell carcinoma: analysis of clinicopathological and biological factors. *Ann J Gastroenterol* **94**, 1933–1940.
 29. Yamamoto J, Ohshima K, Ikeda S, Iwashita A and Kikuchi M (2003) Primary esophageal small cell carcinoma with concomitant invasive squamous cell carcinoma or carcinoma in situ. *Hum Pathol* **34**, 1108–1115.