

東邦大学学術リポジトリ



OPAC

東邦大学メディアセンター

タイトル	A treatment strategy using subcutaneous fondaparinux followed by oral rivaroxaban is effective for treating acute venous thromboembolism
別タイトル	皮下注射フォンダパリヌクスと経口リバーロキサバンを利用した治療ストラテジーは急性静脈血栓症治療において有効である
作成者（著者）	冠木, 敬之
公開者	東邦大学
発行日	2017.03.28
掲載情報	東邦大学大学院医学研究科 博士論文. 17.
資料種別	学位論文
内容記述	主査：東丸貴信 / タイトル：A treatment strategy using subcutaneous fondaparinux followed by oral rivaroxaban is effective for treating acute venous thromboembolism / 著者：Takayuki Kabuki, Rine Nakanishi, Shinji Hisatake, Takahiro Fujii, Shintaro Dobashi, Shingo Wakakura, Syunsuke Kiuchi, Tadashi Fujino, Takanori Ikeda / 掲載誌：Journal of Cardiology / 巻号・発行年等：70(2):163-8, 2017 / 本文ファイル: 出版者版
著者版フラグ	ETD
報告番号	32661甲第844号
学位記番号	甲第570号
学位授与年月日	2017.03.28
学位授与機関	東邦大学
DOI	info:doi/10.1016/j.jjcc.2016.10.013
その他資源識別子	https://www.sciencedirect.com/science/article/pii/S0914508716302805
メタデータのURL	https://mylibrary.toho-u.ac.jp/webopac/TD76450606



Original article

A treatment strategy using subcutaneous fondaparinux followed by oral rivaroxaban is effective for treating acute venous thromboembolism[☆]



Takayuki Kabuki (MD)^{*}, Rine Nakanishi (MD, PhD), Shinji Hisatake (MD, PhD), Takahiro Fujii (MD), Shintaro Dobashi (MD), Shingo Wakakura (MD), Shunsuke Kiuchi (MD, PhD), Tadashi Fujino (MD, PhD), Takanori Ikeda (MD, PhD, FJCC)

Department of Cardiovascular Medicine, Toho University Faculty of Medicine, Tokyo, Japan

ARTICLE INFO

Article history:

Received 7 May 2016

Received in revised form 16 October 2016

Accepted 27 October 2016

Available online 12 December 2016

Keywords:

Venous thromboembolism

Deep vein thrombosis

Direct Xa inhibitor

Fondaparinux

Rivaroxaban

ABSTRACT

Background: The factor Xa inhibitors have been widely used for the treatment and prevention of venous thromboembolism (VTE). However, the efficacy of factor Xa inhibitors in Japanese patients with VTE has not been well examined. In this study, we investigated the effect of the sequential use of two factor Xa inhibitors in patients with acute VTE.

Methods: We conducted an observational study of 87 consecutive patients diagnosed with VTE. As an initial treatment, we administered subcutaneous fondaparinux to the patients for 7–10 days, and then switched to oral rivaroxaban. The symptoms and findings were assessed after the initial treatment and after using rivaroxaban for 7–14 days. We evaluated the deep vein thrombosis (DVT) in the legs using our own scoring system [quantitative ultrasound thrombosis (QUT) score].

Results: Of the 87 patients, 33% had symptoms, half had pulmonary embolism (PE), and 95% had DVT of the legs. Out of the 87 patients, VTE worsened during the administration of fondaparinux in 4 patients. All of them had experienced malignancy, and died within 6 months. Of two patients developing bleeding, one patient required a transfusion. Eventually, this strategy was effective in 80 patients and had no change in one. The D-dimer level was significantly reduced by fondaparinux ($17.8 \mu\text{g/ml} \pm 16.0 \mu\text{g/ml}$ vs. $8.3 \mu\text{g/ml} \pm 7.2 \mu\text{g/ml}$, $p < 0.0001$), followed by rivaroxaban ($8.3 \mu\text{g/ml} \pm 7.2 \mu\text{g/ml}$ vs. $5.5 \mu\text{g/ml} \pm 4.9 \mu\text{g/ml}$, $p < 0.0001$). Similarly, the QUT score was improved by fondaparinux (4.7 ± 2.6 vs. 2.5 ± 2.5 , $p < 0.0001$), and further reduced by rivaroxaban (2.5 ± 2.5 vs. 1.9 ± 1.8 , $p < 0.0001$).

Conclusions: A treatment strategy using subcutaneous fondaparinux followed by oral rivaroxaban is effective for treating acute VTE in Japanese patients.

© 2016 Japanese College of Cardiology. Published by Elsevier Ltd. All rights reserved.

Introduction

The incidence of venous thromboembolism (VTE) has been increasing for decades because of the aging population, obesity, Western dietary habits, advances in the diagnostic skills, increasing social awareness, and heart failure [1,2]. A standard anticoagulant therapy, the initial use of unfractionated heparin (UFH) with

a transition to warfarin, has been developed and broadly utilized in treating acute VTE [1]. However, this treatment requires an intravenous injection, frequent blood sampling due to dosage adjustments, cautious food intake, and concern over interactions with warfarin when using other medications, and heparin is known for heparin-induced-thrombocytopenia problems [3]. Also sometimes 2–3 days are required until the activated partial thromboplastin time (APTT) reaches its target range during the initial stage of UFH treatment. Despite the frequent monitoring, almost 40% of patients do not reach the target range [4].

The anticoagulant drugs, factor Xa inhibitors, can be given at a fixed dose without routine monitoring and intravenous routes. Fondaparinux is a synthetic pentasaccharide, which is a small anticoagulant molecule of heparin saccharide. The anticoagulant effect is created by specifically bonding to antithrombin and

[☆] This manuscript was supported in part by Grants-in-Aid (24591074 and 15K09103 to T.I.) for Scientific Research from the Ministry of Education, Culture, Sports, Science and Technology of Japan.

^{*} Corresponding author at: Department of Cardiovascular Medicine, Toho University Faculty of Medicine, 6-11-1 Omorinishi, Ota-ku, Tokyo 143-8541, Japan. Fax: +81 3 3766 7810.

E-mail address: onthedge3@gmail.com (T. Kabuki).

blocking the factor Xa inhibitor [5]. Only a once a day hypodermic injection is necessary, and the bioavailability is relatively high. It also does not bond with any other plasma protein than antithrombin, and thus a stable anticoagulation effect reflecting the dosage is expected, no routine blood sampling is required for monitoring, and there is no need to ensure an intravenous route. Also patients receiving Xa inhibitors reach the target range from day one, and thus the anticoagulant effect is ensured from the beginning of the treatment.

However, the efficacy of the newer anticoagulant drugs in Japanese patients with VTE has not been well examined [6]. In this study, we investigated the effect of the sequential use of two factor Xa inhibitors, subcutaneous fondaparinux and oral rivaroxaban in patients with acute VTE.

Methods

Study population

We conducted a retrospective study of 87 consecutive inpatients with VTE (mean age 68.5 ± 12.8 years, 33% male) between January 2013 and December 2014 at our institution (Omori Hospital, Toho University Faculty of Medicine, Tokyo, Japan). Among all patients, acute symptoms and/or newly increased D-dimer concentrations were confirmed, and VTE was evident on venous ultrasound, contrast computed tomography, or pulmonary perfusion. Patients with massive pulmonary embolism (PE), those under 18 years of age, a CCr level < 30 ml/min, or complications associated with bleeding risks were excluded. This study was approved by the Institutional Review Board of Toho University Faculty of Medicine (No. 27–247).

VTE management

As an initial treatment, we administered fondaparinux to patients who received a diagnosis of acute VTE, according to the patient's body weight (5 mg for < 50 kg or 7.5 mg for 50–100 kg) for 7–10 days. After the treatment with subcutaneous fondaparinux, they were switched to oral rivaroxaban. The symptoms and findings were assessed after the initial treatment and subsequent rivaroxaban treatment for 7–14 days (Fig. 1).

This strategy only requires a few blood samples. The frequent blood sampling, precise dosing, and a continuous IV as in the

standard treatment are not necessary. The anticoagulant therapy was discontinued when major bleeding occurred. Major bleeding was defined as follows: (1) fatal bleeding, (2) symptomatic bleeding in a critical area or organ, such as intracranial, intraspinal, intraocular, retroperitoneal, intraarticular, pericardial, or intramuscular bleeding with compartment syndrome, and (3) bleeding causing a fall in the hemoglobin requiring a transfusion of two or more units of whole blood or red cells, in accordance with the International Society on Thrombosis and Haemostasis [7].

Efficacy outcomes of DVT in the legs

We evaluated the DVT in the legs using a simple unique scoring method that we first reported in the current study for DVT assessment by an ultrasound examination [quantitative ultrasound thrombosis (QUT) score]. The QUT scoring method was derived based upon our own scoring system as follows: two points were given for an occlusion by a thrombus in the inferior vena cava, pelvic vein, femoral vein, or below-knee vein. Since the below-knee vein included the 3 veins, the anterior tibial vein, posterior tibial vein, and peroneal vein, a score was given for each vein. One point was given for the presence of a thrombus but no occlusion in any of those veins. We evaluated the sum of the points in each area before and after the anticoagulant therapy (Fig. 2).

Statistical analysis

The continuous variables are expressed as the mean \pm standard deviation. Comparisons of the D-dimer level and QUT score transitions were performed using a one-way analysis of variance followed by *z* Bonferroni's multiple comparison. A significance level was set at a *p*-value of 0.05.

All statistical analyses were performed using a commercially available computer software program (IBM SPSS Statistics, Version 19, Armonk, NY, USA).

Results

Patient characteristics

The baseline characteristics in this study are summarized in Table 1. Fifty-eight (66.7%) were women and the mean age was

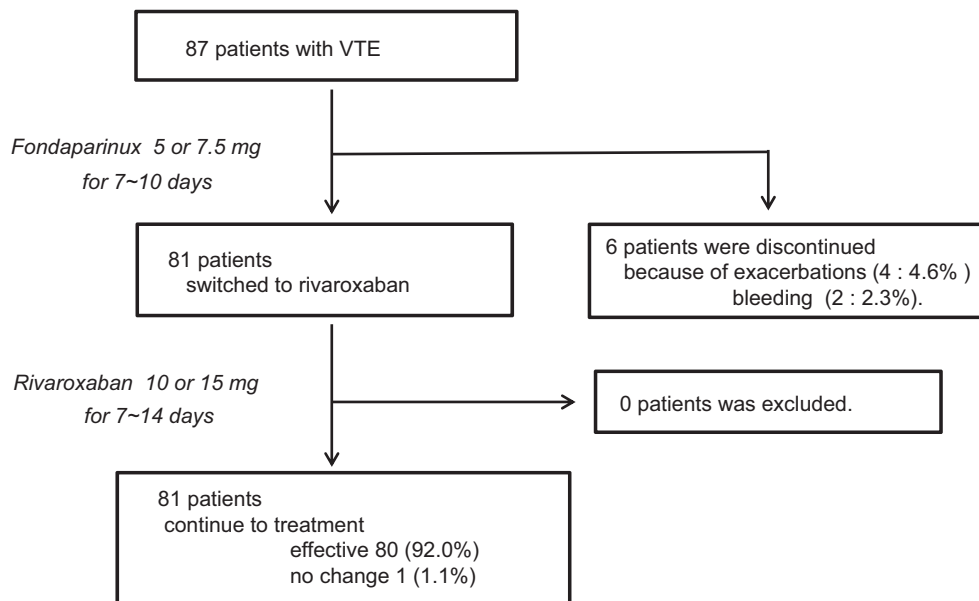


Fig. 1. The patient enrollment. VTE, venous thromboembolism.

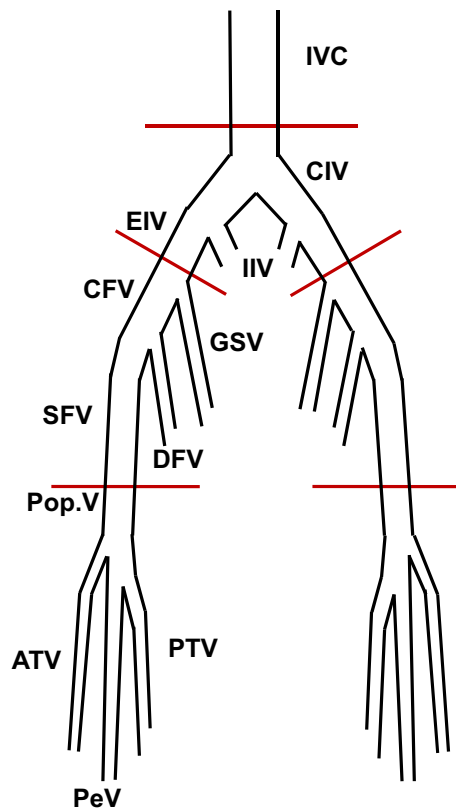


Fig. 2. Measurement of quantitative ultrasound thrombosis (QUT) score. We separated the 11 deep veins including IVC, right pelvic vein, left pelvic vein, right femoral vein, left femoral vein, 3 right below-knee veins, and 3 left below-knee veins. Two points were given for an occlusion by a thrombus, and one point for the presence of a thrombus but no occlusion. We evaluated the sum of the points in each segment (maximum scores: 22). IVC, inferior vena cava; CIV, common iliac vein; EIV, external iliac vein; IIV, internal iliac vein; CFV, common femoral vein; GSV, great saphenous vein; SFV, superficial femoral vein; DFA, deep femoral vein; Pop.V, popliteal vein; ATV, anterior tibial vein; PTV, posterior tibial vein; PeV, peroneal vein.

68.5 years. The mean body weight and body mass index were 56.3 ± 12.9 kg and 23.1 ± 4.5 kg/m², respectively.

Eighty-six patients (99%) underwent venous ultrasound and 81 (93%) underwent contrast computed tomography, pulmonary perfusion scanning, or both. Of the 87 patients, 33% had symptoms associated with VTE such as dyspnea or lower extremity edema. The rest were diagnosed with a VTE through screening or a high D-dimer value. Half of the patients had PE and 95% had DVT (proximal 22%). The suspected causes of the VTE in the current study are summarized in Table 2. Mostly, they were malignant tumors (26%) or post-operative complications (32%). Two patients had thrombophilia.

Patient enrollment

The mean dose of fondaparinux was 6.7 ± 1.2 mg and the mean administration period was 7.5 ± 1.4 days. Regarding rivaroxaban therapy, 13.9 ± 2.1 mg was used during 10.2 ± 3.3 days. Out of 87 patients, in 4 patients the VTE became worse during the administration of subcutaneous fondaparinux. All of them experienced a malignancy including lung cancer, cancerous peritonitis with cancer of an unknown origin, or esophageal cancer, and died within 6 months. Of the 4 patients, UFH was used after discontinuing fondaparinux therapy in 2 patients, whereas no improvement of VTE was observed. The other 2 patients could not continue fondaparinux therapy because of their malignant end-stage conditions. Two

Table 1
Subject characteristics.

Variables	Value
Female, No.	58 (66.7%)
Age (years)	68.5 ± 12.8
Weight (kg)	56.3 ± 12.9
BMI (kg/m ²)	23.1 ± 4.5
Systolic BP (mmHg)	124.0 ± 18.0
Diastolic BP (mmHg)	69.3 ± 12.7
PR (beats/min)	80.1 ± 12.8
SpO ₂ (roomair) (%)	95.9 ± 3.57
s-Cr (mg/dl)	0.73 ± 0.23
eGFR (ml/min/1.73 m ²)	72.1 ± 21.8
D-dimer (μg/ml)	18.1 ± 16.1
PE with DVT, No.	41 (47.1%)
PE without DVT, No.	3 (3.4%)
DVT only, No.	43 (49.4%)
PESI (n=44)	
Score	97.7 ± 29.4
Class I, No.	3 (6.8%)
Class II, No.	17 (38.6%)
Class III, No.	9 (20.5%)
Class IV, No.	8 (18.2%)
Class V, No.	7 (15.9%)
Hypertension, No.	35 (40.2%)
Diabetes mellitus, No.	18 (20.6%)
Smoking, No.	16 (18.4%)
Stroke, No.	2 (2.3%)
Ischemic heart disease, No.	3 (3.5%)

BMI, body mass index; s-Cr, serum creatinine; PR, pulse rate; eGFR, estimated glomerular filtration rate; PE, pulmonary embolism; DVT, deep vein thrombosis; PESI, pulmonary embolism severity index.

Table 2
Suspected causes of VTE.

Variables	Value
Thrombophilia, No. (%)	2 (2.3%)
Malignant tumor, No. (%)	23 (26.4%)
Post-operation, No. (%)	28 (32.1%)
Bed rest over 1 week, No. (%)	13 (14.5%)
Legs bone fracture, No. (%)	7 (8.1%)
Drugs (steroids, pills), No. (%)	5 (5.7%)
Others (aging, overweight, or unknown), No. (%)	9 (10.3%)

VTE, venous thromboembolism.

patients developed bleeding from a rectus abdominis muscle. They developed major bleeding requiring a transfusion or minor bleeding with intra-muscular hemorrhaging, resulting in the discontinuation of the fondaparinux therapy. Subsequent to the therapy, oral rivaroxaban was administered in 81 patients. Of those, no patients developed any subjective symptoms or experienced worsening of the VTE. In the end, this strategy was effective in 80 patients and no change was observed in one (Fig. 1).

Transition of the D-dimer level and QUT score

During the course of the treatment, the D-dimer level (17.7 ± 91.0 μg/ml) was significantly reduced by fondaparinux (17.8 ± 16.0 μg/ml vs. 8.3 ± 7.2 μg/ml, $p < 0.0001$), followed by rivaroxaban (8.3 ± 7.2 μg/ml vs. 5.5 ± 4.9 μg/ml, $p < 0.0001$) (Fig. 3). Similarly, the QUT score was improved by fondaparinux (4.7 ± 2.6 vs. 2.53 ± 2.51 , $p < 0.0001$), and further reduced by rivaroxaban (2.5 ± 2.5 vs. 1.9 ± 1.8 , $p < 0.0001$) (Fig. 4).

In a sub-analysis of 23 patients with cancer, the D-dimer level was similarly reduced by the sequential use of these two factor Xa inhibitors (22.2 ± 24.2 μg/ml vs. 4.3 ± 4.8 μg/ml, $p < 0.0001$). The QUT score was also improved (4.6 ± 2.6 vs. 2.0 ± 2.0 , $p = 0.0006$).

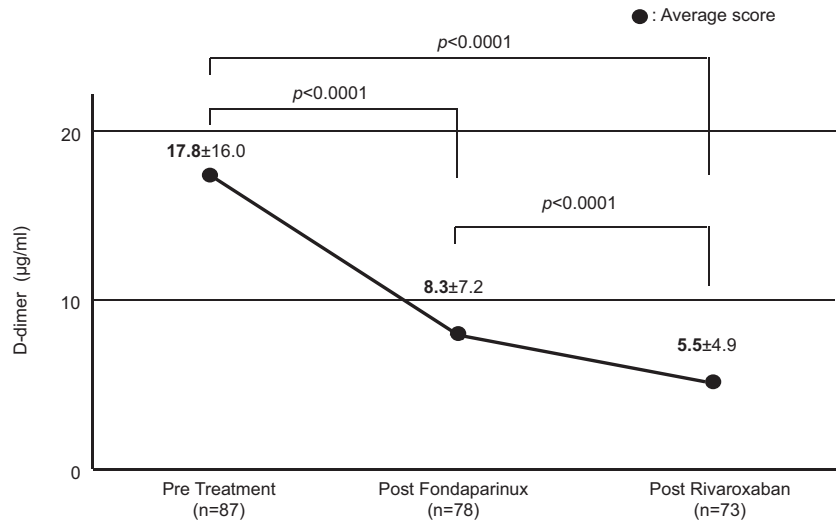


Fig. 3. Transition of the D-dimer level. We observed a significant reduction after the fondaparinux treatment for 7–10 days and rivaroxaban treatment for 7–14 days.

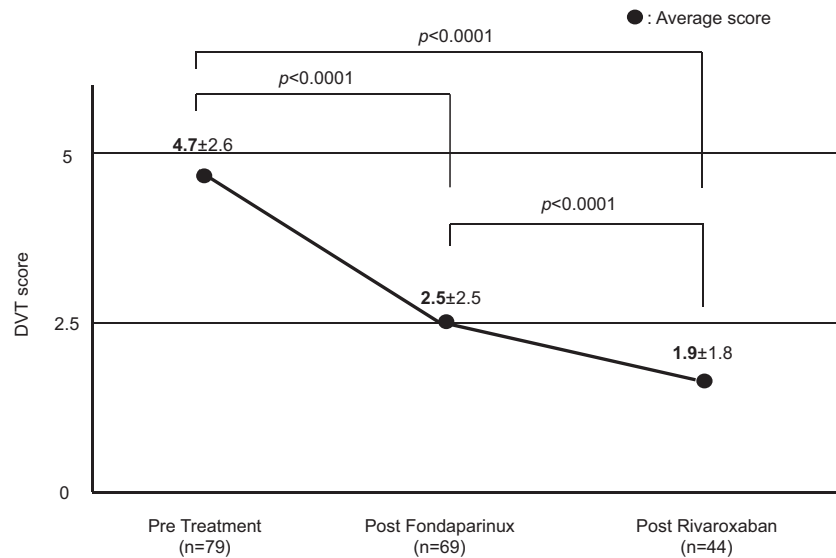


Fig. 4. Transition of the QUT score. The QUT score was improved by the fondaparinux treatment, and further reduced by the rivaroxaban treatment. QUT, quantitative ultrasound thrombosis.

Discussion

In the current study, our findings indicated the safety and efficacy of the therapeutic approach to VTE by subcutaneous fondaparinux followed by oral rivaroxaban in Japanese individuals. 6.9% of the patients did not continue the treatment on fondaparinux due to a progressive malignancy (4 patients) or complications involving bleeding (2 patients), the rest were successfully treated by rivaroxaban following fondaparinux.

The effectiveness and safety of fondaparinux has been proven in large-scale clinical trials against UFH and enoxaparin [8,9]. The American College of Chest Physicians and European Society of Cardiology guidelines recommend the use of fondaparinux along with UFH for the initial VTE treatment [10,11]. The safety and efficacy in relation to UFH in Japanese patients were also evident in a prior clinical study [12], whereas the quantitative assessment of the improvement in the DVT has not been explored. We firstly demonstrated a great reduction in the D-dimer and QUT score with

subcutaneous fondaparinux. While several patients did not tolerate the treatment and we did not directly compare the patients treated with fondaparinux to those with heparin, the risk seemed to be similar compared to that of heparin in the previous investigations (major bleedings, 1.1–1.5%) [9,13]. Rivaroxaban blocks factor Xa to provide an anticoagulant effect, and is widely used globally as a VTE treatment drug and as one of the non-vitamin K antagonist oral anticoagulants [11,14]. We switched from subcutaneous fondaparinux to oral rivaroxaban with the presupposition that there would be no aggravation during the initial treatment, resulting in a time-saving treatment with a remarkable reduction in both the D-dimer level and QUT score. In the current study, we used the D-dimer level and QUT score for therapeutic evaluation for VTE. Approximately a 50% reduction in the D-dimer level and QUT score was observed during the first 7–10 days after the fondaparinux treatment, and was 53.4% and 46.9%, respectively. Subsequently, treatment with rivaroxaban additionally improved the D-dimer level and QUT score by 34.7%

and 24.0%, respectively. In patients with cancer, the fondaparinux and rivaroxaban treatments similarly improved the D-dimer level and QUT score.

Our results showed that the D-dimer level and QUT score could be used as an indicator of the amount of thrombus in the DVT treatment.

Of importance, there was no aggravation observed in any patients during the rivaroxaban treatment. Bleeding events after switching were also very few and comparable with the prior investigations [15]. Globally, a single treatment with rivaroxaban was accepted for the initial VTE treatment, if three weeks of loading had been achieved [14]. The global loading dose usage of rivaroxaban in Japan has been recently reported by J-EINSTEIN [16] assessing the efficacy of oral rivaroxaban alone (10 mg twice daily or 15 mg twice daily for 3 weeks followed by 15 mg once daily) with Japanese VTE patients. Also, in the clinical study targeting Japanese nonvalvular atrial fibrillation patients, the J-ROCKET AF study showed that the administration of low-dose rivaroxaban (15 mg/day) was proven to be non-inferior in preventing thrombotic events compared to the good-control warfarin patients [15], and thus low-dose rivaroxaban is adequately effective in Japanese patients compared to that in European patients. We reported the treatment effect of dabigatran in VTE outpatients [17], and switching from subcutaneous fondaparinux to oral rivaroxaban in inpatients is convenient, safe, and a reasonable treatment strategy for both the medical personnel and patients.

In the current study, malignant tumors were observed in 23 out of 87 patients (26%). The high prevalence of cancer patients in the current study is consistent with the prior studies [4], suggesting that our cohort included “real-world” patients compared to the aforementioned study with only 7.2% [16]. Malignant tumors often create a thrombosis-prone status and there are numbers of reports revealing the high probability of VTE complications in cancer patients. Among the symptomatic VTE patients, 17% had active tumors in the RIETE Study [18]. Jeanet et al. [19] reported that among 3220 patients diagnosed with VTE, 389 (12.1%) had cancer, which was four times higher (3.2%) than participants without VTE. Also, Alex et al. [20] revealed that the onset of VTE in cancer patients is 4.7 times higher than that in non-cancer patients. Cancer patients are often resistant to anticoagulation treatment, and have a three times higher recurrence rate and two times higher bleeding rate, and this correlates with the progression of the cancer [21]. Indeed, we observed that all patients that exhibited an aggravation of the thrombosis during the fondaparinux treatment had advanced cancer and all died within half a year. The current guideline recommends the utility of parenteral anticoagulant treatment for cancer patients with VTE because such patients have a high rate of recurrence of VTE. Our data demonstrated that we successfully treated 81 of 87 patients (93.1%) using fondaparinux treatment, whereas there was no study examining the efficacy of fondaparinux treatment for cancer patients [11]. In this regard, future studies examining the therapeutic strategy in patients with advanced cancer will be needed.

Study limitations

This study has some limitations. This study was a retrospective and observational study that did not compare the results with those in patients with standard therapy, however, the results were acceptable. We demonstrated that this treatment strategy improved the quantitative score assessed by the D-dimer level and QUT score. Since this study excluded patients with massive PE, the efficacy of factor Xa inhibitors in massive PE needs to be examined. This study had a small sample size, which might have resulted in statistical bias. Further prospective studies in a larger cohort with acute DVT will be required to confirm our results.

Conclusions

A treatment strategy using fondaparinux followed by rivaroxaban is effective for treating VTE in Japanese patients. This strategy may improve the benefit-to-risk profile of the acute VTE treatment.

Funding

This research received no grant from any funding agency in the public, commercial, or not-for-profit sectors.

Conflicts of interest

T.I. has received grant support through his institution from Daiichi Sankyo, Bristol-Myers Squibb, Boehringer Ingelheim; and honoraria for lectures from Bayer Healthcare, Daiichi Sankyo, Bristol-Myers Squibb, Pfizer, Tanabe-Mitsubishi, and Ono Pharmaceutical. Regarding this study, all authors declare that there is no potential conflict of interest.

Acknowledgment

We thank Mr Chiaki Nishimura for his statistical advice.

References

- [1] JCS Joint Working Group. Guidelines for the diagnosis, treatment and prevention of pulmonary thromboembolism and deep vein thrombosis (JCS 2009). *Circ J* 2011;75:1258–81.
- [2] Matsuo H, Matsumura M, Nakajima Y, Ogawa T, Tazaki J, Doi T, Yamada N, Koide T, Mo M, Suzuki T, Sarai N, Nakajima H. Frequency of deep vein thrombosis among hospitalized non-surgical Japanese patients with congestive heart failure. *J Cardiol* 2014;64:430–4.
- [3] Warkentin TE, Greinacher A. Heparin-induced thrombocytopenia: recognition, treatment, and prevention: the Seventh ACCP Conference on Antithrombotic and Thrombolytic Therapy. *Chest* 2004;126:311S–37S.
- [4] Nakamura M, Miyata T, Ozeki Y, Takayama M, Komori K, Yamada N, Origasa H, Satokawa H, Maeda H, Tanabe N, Unno N, Shibuya T, Tanemoto K, Kondo K, Kojima T. Current venous thromboembolism management and outcomes in Japan. *Circ J* 2014;78:708–17.
- [5] Bauer KA, Hawkins DW, Peters PC, Petitou M, Herbert JM, van Boeckel CA, Meuleman DG. Fondaparinux, a synthetic pentasaccharide: the first in a new class of antithrombotic agents – the selective factor Xa inhibitors. *Cardiovasc Drug Rev* 2002;20:37–52.
- [6] Nakamura M, Yamada N, Ito M. Current management of venous thromboembolism in Japan: current epidemiology and advances in anticoagulant therapy. *J Cardiol* 2015;66:451–9.
- [7] Schulman S, Angeras U, Bergqvist D, Eriksson B, Lassen MR, Fisher W. Subcommittee on Control of Anticoagulation of the Scientific and Standardization Committee of the International Society on Thrombosis and Haemostasis. Definition of major bleeding in clinical investigations of antihemostatic medicinal products in surgical patients. *J Thromb Haemost* 2010;8:202–4.
- [8] Buller HR, Davidson BL, Decousus H, Gallus A, Gent M, Piovella F, Prins MH, Raskob G, Segers AE, Cariou R, Leeuwenkamp O, Lensing AW, Mattise Investigators. Fondaparinux or enoxaparin for the initial treatment of symptomatic deep venous thrombosis: a randomized trial. *Ann Intern Med* 2004;140:867–73.
- [9] Buller HR, Davidson BL, Decousus H, Gallus A, Gent M, Piovella F, Prins MH, Raskob G, van den Berg-Segers AE, Cariou R, Leeuwenkamp O, Lensing AW, Mattise Investigators. Subcutaneous fondaparinux versus intravenous unfractionated heparin in the initial treatment of pulmonary embolism. *N Engl J Med* 2003;349:1695–702.
- [10] Kearon C, Akl EA, Comerota AJ, Pradoni P, Bounameaux H, Goldhaber SZ, Nelson ME, Wells PS, Gould MK, Dental F, Crowther M, Kahn SR, American College of Chest Physicians. Antithrombotic therapy for VTE disease: Antithrombotic Therapy and Prevention of Thrombosis, 9th ed: American College of Chest Physicians Evidence-Based Clinical Practice Guidelines. *Chest* 2012;141(2 Suppl.):e419S–94S.
- [11] Konstantinides SV, Torbicki A, Agnelli G, Danchin N, Fitzmaurice D, Galie N, Gibbs JS, Huisman MV, Humbert M, Kucher N, Lang I, Lankeit M, Lekakis J, Maack K, Mayer E, et al. Task Force for the Diagnosis and Management of Acute Pulmonary Embolism of the European Society of Cardiology (ESC). 2014 ESC guidelines on the diagnosis and management of acute pulmonary embolism. *Eur Heart J* 2014;35:3033–80.
- [12] Nakamura M, Okano Y, Minamiguchi H, Munemasa M, Sonoda M, Yamada N, Hanzawa K, Aoyagi N, Tsujimoto H, Sarai N, Nakajima H, Kunieda T. Multidetector-row computed tomography-based clinical assessment of

- fondaparinux for treatment of acute pulmonary embolism and acute deep vein thrombosis in Japanese patients. *Circ J* 2011;75:1424–32.
- [13] Low-molecular-weight heparin in the treatment of patients with venous thromboembolism. The Columbus Investigators. *N Engl J Med* 1997;337:657–62.
- [14] Kearon C, Akl EA, Ornelas J, Blaivas A, Jimenez D, Bounameaux H, Huisman M, King CS, Morris TA, Sood N, Stenens SM, Vintch JR, Wells P, Woller SC, Moores L. Antithrombotic therapy for VTE disease: CHEST guideline and expert panel report. *Chest* 2016;149:315–52.
- [15] Hori M, Matsumoto M, Tanahashi N, Momomura S, Uchiyama S, Goto S, Izumi T, Koretsune Y, Kajikawa M, Kato M, Ueda H, Iwamoto K, Tajiri M, J-ROCKET AF Study Investigators. Rivaroxaban vs. warfarin in Japanese patients with atrial fibrillation – the J-ROCKET AF study. *Circ J* 2012;76:2104–11.
- [16] Yamada N, Hirayama A, Maeda H, Sakagami S, Shikata H, Prins MH, Lensing AWA, Kato M, Onuma J, Miyamoto Y, Iekushi K, Kajikawa M. Oral rivaroxaban for Japanese patients with symptomatic venous thromboembolism – the J-EINSTEIN DVT and PE program. *Thromb J* 2015;13:2.
- [17] Fujino T, Yamazaki Y, Yamazaki A, Kabuki T, Kiuchi S, Kobayashi K, Yamazaki J, Ikeda T. Efficacy of dabigatran for dissolving deep vein thromboses in outpatients with a deteriorated general condition. *Int Heart J* 2015;56:395–9.
- [18] Gussoni G, Frasson S, La Regina M, Di Micco P, Monreal M, RIETE Investigators. Three-month mortality rate and clinical predictors in patients with venous thromboembolism and cancer. Findings from the RIETE registry. *Thromb Res* 2013;131:24–30.
- [19] Blom JW, Doggen CJ, Osanto S, Rosendaal FR. Malignancies, prothrombotic mutations, and the risk of venous thrombosis. *JAMA* 2005;293:715–22.
- [20] Walker AJ, Card TR, West J, Crooks C, Grainge MJ. Incidence of venous thromboembolism in patients with cancer – a cohort study using linked United Kingdom databases. *Eur J Cancer* 2013;49:1404–13.
- [21] Prandoni P, Lensing AW, Piccioli A, Bernardi E, Simoni P, Girolami B, Marchiori A, Sabbion P, Prins MH, Noventa F, Girolami A. Recurrent venous thromboembolism and bleeding complications during anticoagulant treatment in patients with cancer and venous thrombosis. *Blood* 2002;100:3484–8.