

**Original Article****Evaluation of anatomical training for nursing students using unfixed lung, trachea, and larynx of swine**

Masaaki TAKAYANAGI\*, Dept. of Anatomy, Faculty of Medicine, Toho Univ.  
Megumi SUGAHARA, Toho University Omori Medical Center  
Manami NOZAKI, Dept. of Fundamental Nursing, Faculty of Nursing, Toho Univ.  
Satomi KOBAYASHI, School of Nursing, Tokyo Eisei Gakuen College  
Tomokazu KAWASHIMA, Dept. of Anatomy, Faculty of Medicine, Toho Univ.  
Hideo HOSHI, Dept. of Anatomy, Faculty of Medicine, Toho Univ.  
Tadanobu Chuyo KAMIJO, Dept. of Anatomy, Faculty of Medicine, Toho Univ.  
Fumi SATO, Dept. of Anatomy, Faculty of Medicine, Toho Univ.

**Abstract**

**Objectives:** Anatomy and physiology are fundamental subjects for establishing a foundation of knowledge for nursing. We have conducted anatomical training using unfixed respiratory internal organs (lung, trachea, and larynx) of swine in order to provide anatomy education to nursing students, since nursing students in Japan are not able to dissect the human body for learning. The objective of this study was to evaluate anatomical training of participating students and instructors, in order to inform development of an educational system effective at teaching anatomy of the respiratory system, and to enhance educational technique.

**Subjects and methods:** Grade 1 nursing students participated in an anatomy practicum using unfixed respiratory systems of swine (dissection, identification of the parts, labelling, measurement, and recording), after prior study of a textbook and distributed the manual for this anatomical training. We conducted a survey using a questionnaire with five-point Likert scale responses to investigate the benefit of the anatomical training among 425 nursing students who participated in the anatomy practicum. We also interviewed 5 instructors to evaluate the anatomical training.

**Conclusions:** The percentage of students who evaluated the anatomical training as meaningful were 95.4%, 94.1%, and 88.8% for lung, trachea, and larynx, respectively (average 92.8%). Our results suggest that the anatomical training was meaningful for learning anatomy among nursing students. In particular, many students were interested in the air injection demonstration using unfixed lung and segmental bronchus, where movement of the lung can be clearly observed, providing a strong learning opportunity. This demonstration is one of the most popular training experiences among the students. The demonstration enhances understanding of the concept of the pulmonary segmentation, shrinkage of the lung, and pneumothorax, as well as the dynamic image of change of the lung during respiration.

**Keywords:** anatomical education, nursing students, respiratory system, lung, swine

**Introduction**

Anatomy and physiology, where students learn about the structure and function of the human body, are prerequisite subjects in the basic educational program of nursing, and are important subjects that build a foundation for nursing. According to a survey by Fujii et al. (2004), 98.7% of nurses and

79.3% of nursing students consider anatomy to be important. Nurses also reported on this survey, specific examples of nursing practice for which knowledge of the respiratory system was important; 95.9% and 83.2% of nurses reported that such knowledge is important for “assistance for suction” and “assistance for oxygen inhalation”, respectively (Fujii, 2004). Considering that 66.2% of nurses

experience limited competency due to lack of anatomical understanding, although they recognize its importance, it is necessary to develop improved educational content and teaching methods (Fujii, 2004). There is agreement that anatomical training is important for understanding the anatomy and function of the human body, because it allows for learning about human structures sterically. However, in Japan, nursing students cannot conduct dissections on human bodies because they are donated under the condition that they will be used only by medical and dental students (Act on Body Donation for Medical and Dental Education, 1983; Postmortem Examination and Corpse Preservation Act, 1949). While commercialized anatomical models are also valuable as alternative tools for training, they are not as optimal as biological specimens in regard to feeling and understanding the texture and characteristics of biological tissues. Thus, the use of fresh tissue for dissection has been recommended for the training of medical staff and medical students (Hubbell, 2002; Ingram, 2003; Robinson, 2004; Cope, 2008). Unfixed animal specimens have been used for medical training (John, 2008; Zhang, 2008; Umezu, 2009; Mrug, 2010; Joyce 2011; Suenaga, 2012) and anatomical training, not only in nursing schools (Takayanagi, 2007; Mochiki, 2008; Yamaguchi, 2009; Iwama 2011; Takayanagi, 2012), but also in medical educational institutions (Suenaga, 2012) and in science classes in junior high and high schools (Iijima, 2000; Ingram, 2003; Noritake, 2010). Generally, the human body is used in anatomical training after it is fixed with formalin, while animal specimens are used unfixed; animal specimens have the advantage that students are not exposed to formaldehyde emitted from formalin, which is considered to be carcinogenic to humans.

Based on these findings, at Tokyo Eisei Gakuen College, we have conducted anatomical training using unfixed internal organs of swine as a part of anatomy education, in order to foster deeper understanding and interest in anatomy (Takayanagi, 2007; Takayanagi, 2012; Kikuchi, 2014; Takayanagi,

2016). Although there are some reports about anatomical training using hearts and kidneys of swine (Iijima, 2000; Ingram, 2003; Takayanagi, 2007; Mochiki, 2008; Yamaguchi, 2009; Noritake, 2010; Takayanagi, 2012), there are no reports about anatomical training for nursing students using respiratory organs of swine. Therefore, in this study, we report the practice of anatomical training using unfixed lung, trachea, and larynx of swine, and present an evaluation of the training program based on feedback from participating students and instructors, that may be used to improve educational methods and develop an educational system where students can effectively learn the anatomy of respiratory systems.

This study was conducted under the approval of Animal Research Committee for Animal Experimentation for Toho University (permission number: 15-54-212) and Research Ethics Committee at the Faculty of Nursing of Toho University (permission number: 24034). Permission from the principal of the college and the head of the nursing department were obtained in writing, since there is no ethics committee at Tokyo Eisei Gakuen College.

We explained to students the study objectives and that their answers to the questionnaires would not be related to grades or influence pass or fail rates, and that private information would remain confidential. We used answers only from students who provided consent to participate in the study. We also explained similar information, such as study objectives, to the instructors, and the survey was administered to instructors who provided written consent.

### **Subjects and methods**

We conducted anatomical training using unfixed lung, trachea, and larynx of swine in order to provide anatomy education to nursing students. We conducted a questionnaire-based survey among participating nursing students to evaluate the present training program. We also evaluated the training

program by conducting group interviews of instructors. We will first describe the summary of the training program, and then describe the students who participated and the questionnaire-based survey.

### 1. Summary of the training program

Students first had lectures on the anatomy of thoracoabdominal organs, including respiratory systems and cardiovascular systems, during the first semester of the first year, and then students underwent anatomical training using unfixed respiratory organs (lung, trachea, and larynx) between June and July at the laboratory in the school; they submitted an assigned report 1 week after the training.

We distributed “Manual for anatomical training using respiratory system of swine”, created based on selected references (Ingram, 2003; Robinson, 2004; Terada, 2004; Dyce, 2010; Standring, 2016), 1 month prior to the training, and we explained the objectives of practice, preparation, prior learning and assignments, and precautions. Anatomical differences of lung between human and swine were described in the manual. Students were repeatedly encouraged to read through the manual and to study the anatomy of the lung, trachea, and larynx of humans prior to the training. Students were instructed to have a meeting with group members prior to the training and to share roles (leader, dissection, photograph, measurement, and record) during the training. During the training, students were instructed to label slips with anatomical terms to place on the specimens and to observe, identify, and record by taking pictures or making sketches (Figures 1d, g, h, i, l). While photographing of the specimens by students was permitted during anatomical training prior to 2013, it was prohibited after 2014 based on the prohibition advised in the “Recommendation on ethical issues in medical and dental education and research using human body and human specimens”, proposed by three academic societies in Japan (Japanese Association of Anatomists, 2013). Lung, trachea, and larynx were

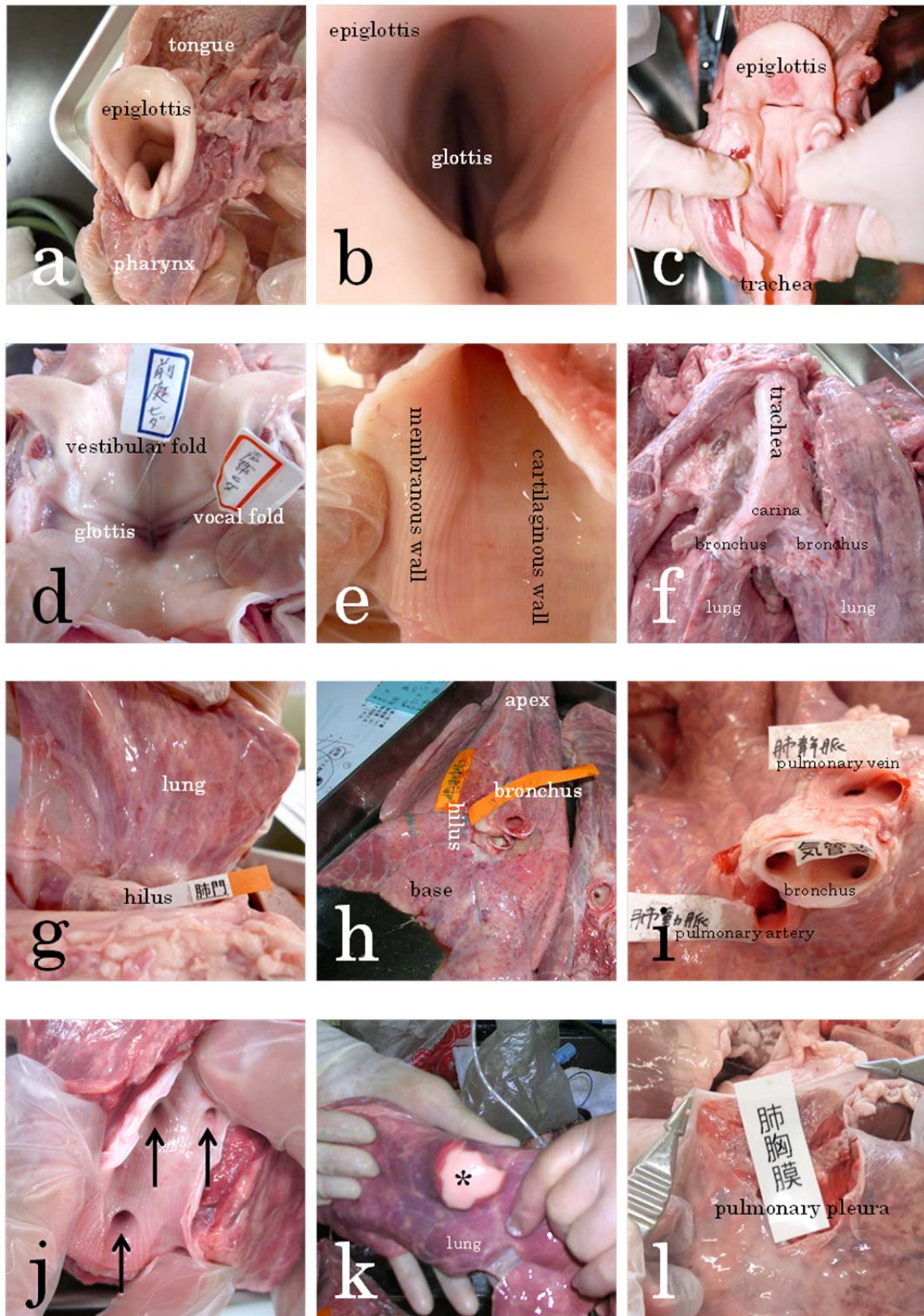
purchased from a meat merchant (Niku no Tabuchi, Tokyo). We explained to the merchant that the purpose of the purchase was anatomical training and we confirmed their understanding. Unfixed internal organs of swine were delivered on the day of or the day before training and were preserved in the refrigerator until the beginning of training.

For each class of 32-42 nursing students (average  $38.6 \pm 3.3$  students,  $n=11$  classes), one anatomy lecturer, 2-3 assistants and 1-2 nursing professors provided the training. One set of the right and left lung, trachea, and larynx was distributed to each group of 4-5 students. For sanitation and deodorisation purposes, students wore white garments, gloves, and masks. A silent prayer was offered before and after the training.

### 2. Content of the training and major procedures

The following procedures were conducted in approximately 30-50 minutes.

- 1) Students identified and observed thyroid cartilage, cricoid cartilage, arytenoid cartilage, and epiglottic cartilage in the larynx (Figure 1a).
- 2) Students observed the larynx from above and confirmed the glottis, which is the opening between the vocal folds (Figure 1b).
- 3) The posterior wall of the larynx was incised in the median line (Figure 1c), and students observed the glottis, vestibular folds, vocal folds, and fissure of the glottis (Figure 1d).
- 4) After the students confirmed the cartilaginous wall by touching where C-shaped tracheal cartilages are connected by annular (intercartilaginous) ligaments (Figure 1e) with a finger, they observed that the trachea consists of lines of these structures.
- 5) The students identified and observed the membranous wall which is composed of smooth muscles without cartilage in the trachea (Figure 1e).
- 6) After a tracheotomy tube was inserted by incising the trachea, securing of the airway was simulated. The students observed how the air pathway changed thereafter.



**Figure 1:** Nursing students' representative photographs of pig larynxes, tracheae, and lungs during the anatomical training using the unfixed swine respiratory organs.

a) Dorsal aspect of swine larynx. The tongue is above, and the pharynx is below. It is easy to observe the swine larynx since it is larger than human larynx. b) Observe larynx from above and confirm glottis, which is the gap of the larynx. c) The posterior wall of the larynx was incised in the median line, and the laryngeal cavity was observed from the posterior view. d) The glottis in the laryngeal cavity was observed from the posterior view. Confirm vestibular fold and vocal fold. e) Students can feel and confirm by touching with a finger the cartilaginous wall where C-shaped tracheal cartilages are connected by annular (intercartilaginous) ligaments, and the membranous wall which is composed of smooth muscles without cartilage in the trachea. f) Confirm the trachea, carina of the trachea, and left and right main bronchi from the dorsal aspect. g) The hilus was identified and cut. After cutting, size and weight of the left and right lung were measured. h) The lung cut from the hilus. Confirm the apex of the lung and base of lung. i) Identify pulmonary artery, pulmonary vein, and main bronchus from the cross section of the hilus. The origin region of segmental bronchi can be seen in the lobar bronchus lumen. j) After incising the main bronchus and lobar bronchus, region of origin for the segmental bronchus (*arrow*) was identified. Observe many segmental bronchi from lobar bronchus. k) When the air was injected using a syringe from the origin region for the segmental bronchus, only the respective pulmonary segment for the segmental bronchus was expanded (\*), and its colour changed from dark-red to light-pink. It helped the students understand the concept of the pulmonary segmentation since neighbouring pulmonary segments did not expand. The lung contracted naturally when the syringe was removed. l) After removing the pulmonary pleura using tweezers, which is thin and strong, expose and observe sponge-like and puffy lung parenchyma. The pulmonary segments where the pulmonary pleura was removed and damaged did not expand even when air was injected into the segmental bronchus, since the air leaked from the damage. This observation helps the students understand pneumothorax.

- 7) The students confirmed the trachea, carina of the trachea, and left and right main bronchi (Figure 1f).
- 8) The students confirmed and cut the hilus (Figure 1g). They measured the size and weight of the left and right lungs.
- 9) The students observed configuration of the lung as a whole and identified the apex of lung and base of the lung (Figure 1h).
- 10) The students confirmed the pulmonary artery, pulmonary vein, and main bronchus from the cross section of the hilus (Figure 1i). They also observed that the pulmonary artery has a thicker vessel wall than the pulmonary vein.
- 11) After removing lung parenchyma around the hilus, lobar bronchi, which branch off from the main bronchus, were dissected.
- 12) After incising the main bronchus and lobar bronchus, the region of origin for the segmental bronchus was identified and observed at the lumen of the lobar bronchus (Figure 1j).
- 13) After the air was injected using a 50 ml catheter tip syringe from the region of origin for the segmental bronchus, students observed that

only a part of the lung was expanded (Figure 1k) to understand the concept of the pulmonary segmentation. Students also confirmed that the air naturally escaped and the lung contracted after removing the syringe.

- 14) After removing the pulmonary pleura, which is thin and strong, the students observed sponge-like and puffy lung parenchyma (Figure 1l).
- 15) The students observed that the lung does not expand in the lung area with broken pulmonary pleura even when the air is injected into the respective segmental bronchus, since the air escapes from the damaged region. The students, therefore, learned the concept of pneumothorax.

### 3. Participated students, analysed students, and methods

A total of 425 nursing students participated in the anatomical training between FY2006 and FY2016; there were 54 male ( $29.7 \pm 7.3$  years old) and 371 female ( $30.2 \pm 8.3$  years old) students, and their average age was  $30.1 \pm 8.2$  years. An anonymous questionnaire-based survey was

administered 1 week after the training. Between FY2006 and FY2012, “Efficacy of anatomical training using swine respiratory system (lung, trachea, and larynx)” was investigated using five-point Likert scales. Between FY2013 and FY2016, we divided the questions into 3 following categories: “efficacy of anatomical training using swine lung”; “efficacy of anatomical training using swine trachea”; and “efficacy of anatomical training using swine larynx”; these items were evaluated. The responses on the five-point scale were “very meaningful”, “somewhat meaningful”, “neither meaningful nor meaningless”, “somewhat meaningless”, and “very meaningless”. We collected the number of answers for each item, and calculated the ratio of students who chose each item. We also evaluated the training by conducting a group interview of 5 instructors who participated in the training. Interview questions included procedures of the training, evaluation for each training item, appearance of the students, and other points noted; we obtained responses in a free format.

## Results

### 1. Summary of participants

For the questionnaire-based survey, data from 249 (response rate 92.6%; Table 1) and 152 (response rate 97.4%; Table 2-4) students out of 269 and 156 nursing students who completed anatomical training between FY2006 and FY2012 and between FY2013 and FY2016, respectively, and who gave written consent, were used for analysis (401 students, response rate 94.4% in total).

### 2. Evaluation of training by students

For anatomical training using the swine respiratory organs (lung, trachea and larynx), 163 students (65.5%), 66 students (26.5%), 18 students (7.2%), and 1 student (0.4%), evaluated it as “very meaningful”, “somewhat meaningful”, “neither meaningful nor meaningless”, and “somewhat meaningless”, respectively; none of them evaluated it as “very meaningless”, and 1 student (0.4%) did

not provide an answer (Table 1). The rate of students who evaluated the training as “very meaningful” or “somewhat meaningful” was 92.0% in total. For anatomical training using the swine lung, 111 students (73.0%), 34 students (22.4%), and 5 students (3.3%) evaluated it as “very meaningful”, “somewhat meaningful”, and “neither meaningful nor meaningless”, respectively. None of them evaluated it as “somewhat meaningless” or “very meaningless”, and 2 students (1.3%) did not provide answers (Table 2). The rate of students who evaluated the training as “very meaningful” or “somewhat meaningful” was 95.4% in total. For anatomical training using the swine trachea, 97 students (63.8%), 46 students (30.3%) and 7 students (4.6%) evaluated it as “very meaningful”, “somewhat meaningful” and “neither meaningful nor meaningless”, respectively. There were no students who evaluated it as “somewhat meaningless” or “very meaningless”, and 2 students (1.3%) did not provide answers (Table 3). The rate of students who evaluated it as “very meaningful” or “somewhat meaningful” was 94.1% in total. For anatomical training using swine larynx, 83 students (54.6%), 52 students (34.2%), 12 students (7.9%), and 1 student (0.7%) evaluated it as “very meaningful”, “somewhat meaningful”, “neither meaningful nor meaningless”, and “somewhat meaningless”, respectively. There were no students who evaluated it as “very meaningless”, and 4 students (2.6%) did not provide answers (Table 4). The rate of students who evaluated it as “very meaningful” or “somewhat meaningful” was 88.8% in total.

### 3. Evaluation of training by instructors

Overall training procedures: the instructors evaluated the procedures as “the training was conducted smoothly”, as shown by comments “I liked the style of the training where lecturer gave demonstration of dissection and then students conducted the training alternately”, and “specific presentation of each item helped the students

**Table 1:** Evaluation of anatomical training using the swine respiratory system by nursing students

Year	Question Was the anatomical training using the unfixed swine respiratory organs (lung, trachea, and larynx) meaningful?												
	Very meaningful		Somewhat meaningful		Meaningful/ meaningless		Somewhat meaningless		Very meaningless		No answers		Total
	# students	(%)	# students	(%)	# students	(%)	# students	(%)	# students	(%)	# students	(%)	
2012	26	(68.4)	10	(26.3)	2	(5.3)	0		0		0		38
2011	17	(68.0)	8	(32.0)	0		0		0		0		25
2010	26	(74.3)	6	(17.1)	3	(8.6)	0		0		0		35
2009	30	(71.4)	11	(26.2)	1	(2.4)	0		0		0		42
2008	20	(54.1)	11	(29.7)	5	(13.5)	0		0		1	(2.7)	37
2007	20	(57.1)	10	(28.6)	4	(11.4)	1	(2.9)	0		0		35
2006	24	(64.9)	10	(27.0)	3	(8.1)	0		0		0		37
<b>Total</b>	<b>163</b>	<b>(65.5)</b>	<b>66</b>	<b>(26.5)</b>	<b>18</b>	<b>(7.2)</b>	<b>1</b>	<b>(0.4)</b>	<b>0</b>	<b>(0.0)</b>	<b>1</b>	<b>(0.4)</b>	<b>249</b>

**Table 2:** Evaluation of anatomical training using the swine lung by nursing students

Year	Question Was the anatomical training using the unfixed swine lung meaningful?												
	Very meaningful		Somewhat meaningful		Meaningful/ meaningless		Somewhat meaningless		Very meaningless		No answers		Total
	# students	(%)	# students	(%)	# students	(%)	# students	(%)	# students	(%)	# students	(%)	
2016	23	(71.9)	8	(25.0)	1	(3.1)	0		0		0		32
2015	29	(74.4)	6	(15.4)	3	(7.7)	0		0		1	(2.6)	39
2014	29	(74.4)	8	(20.5)	1	(2.6)	0		0		1	(2.6)	39
2013	30	(71.4)	12	(28.6)	0		0		0		0		42
<b>Total</b>	<b>111</b>	<b>(73.0)</b>	<b>34</b>	<b>(22.4)</b>	<b>5</b>	<b>(3.3)</b>	<b>0</b>	<b>(0.0)</b>	<b>0</b>	<b>(0.0)</b>	<b>2</b>	<b>(1.3)</b>	<b>152</b>

**Table 3:** Evaluation of anatomical training using the swine trachea by nursing students

Year	Question Was the anatomical training using the unfixed swine trachea meaningful?												
	Very meaningful		Somewhat meaningful		Meaningful/ meaningless		Somewhat meaningless		Very meaningless		No answers		Total
	# students	(%)	# students	(%)	# students	(%)	# students	(%)	# students	(%)	# students	(%)	
2016	21	(65.6)	10	(31.3)	1	(3.1)	0		0		0		32
2015	25	(64.1)	10	(25.6)	3	(7.7)	0		0		1	(2.6)	39
2014	25	(64.1)	11	(28.2)	2	(5.1)	0		0		1	(2.6)	39
2013	26	(61.9)	15	(35.7)	1	(2.4)	0		0		0		42
<b>Total</b>	<b>97</b>	<b>(63.8)</b>	<b>46</b>	<b>(30.3)</b>	<b>7</b>	<b>(4.6)</b>	<b>0</b>	<b>(0.0)</b>	<b>0</b>	<b>(0.0)</b>	<b>2</b>	<b>(1.3)</b>	<b>152</b>

**Table 4:** Evaluation of anatomical training using the swine larynx by nursing students

Year	Question Was the anatomical training using the unfixed swine larynx meaningful?												
	Very meaningful		Somewhat meaningful		Meaningful/ meaningless		Somewhat meaningless		Very meaningless		No answers		Total
	# students	(%)	# students	(%)	# students	(%)	# students	(%)	# students	(%)	# students	(%)	
2016	21	(65.6)	10	(31.3)	1	(3.1)	0		0		0		32
2015	24	(61.5)	10	(25.6)	4	(10.3)	0		0		1	(2.6)	39
2014	19	(48.7)	16	(41.0)	3	(7.7)	0		0		1	(2.6)	39
2013	19	(45.2)	16	(38.1)	4	(9.5)	1	(2.4)	0		2		42
<b>Total</b>	<b>83</b>	<b>(54.6)</b>	<b>52</b>	<b>(34.2)</b>	<b>12</b>	<b>(7.9)</b>	<b>1</b>	<b>(0.7)</b>	<b>0</b>	<b>(0.0)</b>	<b>4</b>	<b>(2.6)</b>	<b>152</b>

understand the subject”.

Respective training items: larynx specimens were evaluated as “swine larynx is larger than human larynx”, “swine glottis is very similar to human glottis” (Figure 1d), and “it is appropriate for the explanations of the glottis, vestibular fold and vocal fold”. For securing the airway simulation, there were comments as following: “it is possible to explain sterically that patients cannot speak after tube insertion since air does not pass glottis”, “visual explanation helps students to understand the subject”. As a result of the air injection experiment in unfixed lung and segmental bronchus (Figure 1k), only the respective pulmonary segment expanded and bulged about 5-10 mm more in comparison to surrounding tissues. Positive comments were given for the clear change of the lung (e.g., expansion): “The border between expanded and unexpanded areas was clear since neighbouring lung tissues remained unexpanded”, and “the colour of lung clearly changed due to expansion, from dark-red to light-pink”. They also evaluated as “it was visually understandable that individual pulmonary segments are independent since pulmonary segments were expanded when the air was injected to respective segmental bronchi”. Since unfixed lung specimens were used, several comments were given for the nature of the unfixed specimens: “the lung shrunk naturally when the syringe was removed”, and “lung parenchyma, which was resected after breaking pulmonary pleura, was very soft, like sponge” (Figure 1l), and a favourable comment for unfixed specimens was given as “colour and elasticity were significantly different from specimens that are fixed with formalin”.

Appearance of the students: instructors commented that “students were learning proactively”, “students were taking pictures or making sketches for the labelled specimens (Figures 1d, g, h, i, l)”, “the students were surprised aloud when the lung expanded”, and “many students repeated the air injection experiment”. They also commented that “there was no confusion or major hesitation during the training”.

Other points noted: the students used the pictures for assignment as shown by the comment: “many pictures that were taken during the training were used for assignment report”.

## Discussion

### 1. Overall evaluation of the training

In the survey between FY2006 and FY2012, 65.5% of the students who provided answers evaluated the anatomical training using swine respiratory organs (lung, trachea, and larynx) as “very meaningful”, and the ratio reached 92.0% when the number was combined with students evaluating it as “somewhat meaningful”. Dissection of unfixed fresh tissue is a precious tool for medical training of medical students and medical residents (Hubbell, 2002; Ingram, 2003; Robinson, 2004; Joyce, 2011), and the sense of touch for realistic specimen provides a vivid impression (Kikuchi, 2014); our training using unfixed internal organs as specimens was considered to be very valuable for anatomical education of nursing students. Although there were no students who answered as “very meaningless”, 7.2% (18 students) answered as “neither meaningful nor meaningless”, and 0.4% (1 student) answered as “somewhat meaningless”. Considering that a previous study reported that 27.5% and 19.7% of nursing students considered anatomy as “not interesting” and “not important” (Fujii, 2004), our training successfully enhanced the interest and curiosity of students, since only < 8% of the students provided low evaluations for the training. For the students who evaluated the training as “neither meaningful nor meaningless” or “somewhat meaningless”, they may be those 1) who are not interested in anatomy, 2) who do not consider anatomy as important, 3) who hoped for dissection using human specimens instead of alternative animal specimens, or 4) who feel resistance to dissection.

Instructors evaluated the procedures of the training as smooth. In a previous study (Takayanagi, 2007), 23.1% of nursing students who underwent



anatomical training using swine heart reported that prior learning was important, 8.0% of them had difficulty in conducting dissection by themselves, and 7.0% of them described the importance of group discussion and role sharing in the essay. In order to address those needs from students, we repeatedly emphasized “sufficient prior learning”, “group meeting prior to the training”, and “sharing roles during the training” to students before the training. During the training, a lecturer performed a dissection demonstration first, and then students performed dissection; these procedures helped establish the structure of the present educational training system.

## **2. Evaluations for each training item (lung, trachea, and larynx)**

In the survey between FY2013 and FY2016, 73.0%, 63.8%, and 54.6% of the students evaluated the training as “very meaningful” for the swine lung, trachea, and larynx, respectively. Furthermore, when the results of “very meaningful” and “somewhat meaningful” were combined, 95.4%, 94.1%, and 88.8% of the students evaluated the training as meaningful for swine lung, trachea, and larynx, respectively. About 90% of students considered the training using all 3 organs as meaningful, and in particular, training using the lung as the most meaningful. The reason that the anatomical training using the larynx received the lowest evaluation result among the used 3 organs, may be because the general population is not familiar with the larynx, and there was no training specifically about the function of the larynx. For the experiment of air injection to the segmental bronchus, the surprise of many students was audible when the lung was expanded, and they repeated the experiment actively, indicating that this experiment, in particular, was very interesting and impressive for the students. This experiment is feasible only with unfixed flexible tissues, where clear and realistic biological movement can be observed, unlike mere observation of static, fixed specimens in formalin. We can expect learning to be effective as a result of this

training because of the following: (1) students can visually and intuitively understand pulmonary segments for each segmental bronchus by observing that only the respective lung expands when air is injected from the segmental bronchus; (2) students can understand shrinkage characteristics of sponge-like lung parenchyma by observing that the lung naturally contracts when the air injection syringe is removed; (3) it helps the students understand pneumothorax by observing that the lung does not expand even when air is injected after removing the pulmonary pleura; and (4) the students can dynamically visualize the changes occurring in the lung during respiration, by observing its expansion and contraction. In anatomical education, it has been recommended to use fresh swine lung for dissection (Ingram, 2003), and air injection into the tracheal cannula and lung has been conducted using fresh tissue of rat lung in medical school (Robinson, 2004), indicating that the teaching techniques in our training are optimal.

For anatomical training using the swine larynx, 88.8% of responders evaluated the training as meaningful, and instructors also evaluated it as a meaningful educational tool to explain structures inside the larynx, such as the glottis, vestibular fold, and vocal fold. Although there was no student who evaluated the training using the swine lung and trachea as “somewhat meaningless” or “very meaningless”, 0.7% (1 student) of responders evaluated the training using swine larynx as “somewhat meaningless”. Compared to the lung or trachea, the training using larynx involved relatively simple procedures, where students dissected and observed; there were not many opportunities for observing dynamic movement, and the impact on the students may have been low. Students gave slightly lower evaluations for training using the trachea and larynx, compared to the lung. However, we believe the training should be conducted for the respiratory system including the trachea and larynx, instead of only the lung, since the understanding of a series of structures including the larynx, trachea, and lung is essential in order to understand the

anatomy and physiology of respiration and to learn the respiratory system as a whole.

We would like to thank students for giving consent and participating in this study, Ms Yumi Ito (R.N.), Ms Mie Waragai (R.N.), Ms Chie Baba (R.N.), Ms Yuko Nakajima (R.N.), and Ms Akiko Osawa (R.N.) for providing photo images (Figures 1a, b, e, g, i; Figures 1d, f, j; Figures 1h, k; Figure 1c; Figure 1l); Ms Sachiko Muramatsu (R.N.), Mr. Youichi Ishikawa, Mr. Makoto Sakai, and Dr. Teruko Takayanagi (Ph.D.) for providing the training environment and supporting implementation of the training; and Prof. Miyoko Yamamoto (R.N.), Prof. Michiko Machida (R.N.), Prof. Yasuyo Yoda (R.N.), and other staff at Tokyo Eisei Gakuen College.

The authors have no conflict of interests to declare for this manuscript.

### References

- Act on Body Donation for Medical and Dental Education, 1983. Law No. 56, Ministry of Justice, Tokyo, Japan.
- Cope LA, 2008. Dilated canine hearts: A specimen for teaching cardiac anatomy. *Anat. Sci. Educ.* 1, 207-211.
- Dyce KM, Sack WO, Wensing CJG, 2010. Textbook of veterinary anatomy, 4th Ed. WB Saunder Elsevier, St. Louis, MO.
- Fujii T, Sato M, Watanabe H, Shimada T, Nakayama K, 2004. The relationships of nurse' perceptions of anatomy knowledge in clinical nursing with anatomy education (in Japanese). *Japan. J. Nurs. Art Sci.* 3(2), 22-29.
- Hubbell DS, Dwornik JJ, Alway SE, Eliason R, Norenberg RE, 2002. Teaching gross anatomy using living tissue. *Clin. Anat.* 15, 157-159.
- Iijima K, 2000. Dissection of pig kidneys and observation of the tissue in senior high school biology (in Japanese). 1999(11th) Toray Science Education Prize: Works of Winners, 17-21.  
[http://www.toray.co.jp/tsf/rika/pdf/h11\\_05.pdf](http://www.toray.co.jp/tsf/rika/pdf/h11_05.pdf) (accessed 16.09.04)
- Ingram D, 2003. Organ dissections: a fresh perspective. *Am. Biol. Teach.* 65(8), 600-609.
- Iwama J, Matsumoto K, 2011. Educational significance of dissection of animals in nursing department. *Bulletin of Kawasaki City College of Nursing* 16(1), 55-64.
- Japanese Association of Anatomists, Japanese Society of Pathology, Japanese Society of Legal Medicine, 2013. Recommendation on ethical issues in medical and dental education and research using human body and human specimens (in Japanese).  
[http://www.anatomy.or.jp/file/pdf/guideline/proposal\\_130802.pdf](http://www.anatomy.or.jp/file/pdf/guideline/proposal_130802.pdf) (accessed 16.09.04)  
<http://pathology.or.jp/news/pdf/moral-130826.pdf> (accessed 16.09.04)  
[http://www.jslm.jp/topics/teigen\\_201308.pdf](http://www.jslm.jp/topics/teigen_201308.pdf) (accessed 16.09.04)
- John B, Ghani KR, Patel U, Anson K, 2008. Resin polymer and corrosion casting of the porcine pelvi-calyceal system: A meaningful model for investigating new imaging and endoscopic techniques of the upper urinary tract. *Urol. Res.* 36, 39-42.
- Joyce DL, Dhillon TS, Caffarelli AD, Joyce DD, Tsirigotis DN, Burdon TA, Fann JI, 2011. Simulation and skills training in mitral valve surgery. *J. Thorac. Cardiovasc. Surg.* 141, 107-112.
- Kikuchi Y, Nozaki M, Takayanagi M, Mikamo N, Sato F, 2014. Nursing students learning anatomy using non-fixed pig organs (in Japanese with English abstract). *Toho Kango Gakkai-shi* 11, 9-14.  
<http://rep.toho-u.ac.jp/modules/xoonips/detail.php?id=15985428> (accessed 16.09.04)
- Mochiki K, Yamaguchi R, Nagato Y, Haruki Y, Kuzumi T, 2008. Evaluation of education methods using models of thoracic organs and pig hearts specimen (in Japanese). *Nursing Education (Japanese Nursing Association)* 38,

- 252-254.
- Mrug M, Bissler JJ, 2010. Simulation of real-time ultrasound-guided renal biopsy. *Kidney Int.* 78, 705-707.
- Noritake C, Kawakami S, 2010. Observation and experiments of pig hearts' dissection for realizing elaborative structures of the body (in Japanese). *Kyoshi Kyoiku Kenkyu (Faculty of Education, Gifu University)* 6, 127-130.  
[http://www.ed.gifu-u.ac.jp/info/kyosi/pdf/6\\_15.pdf](http://www.ed.gifu-u.ac.jp/info/kyosi/pdf/6_15.pdf) (accessed 16.09.04)
- Robinson AG, Metten S, Guiton G, Berek J, 2004. Using fresh tissue dissection to teach human anatomy in the clinical years. *Acad. Med.* 79, 711-716.
- Postmortem Examination and Corpse Preservation Act, 1949. Law No. 204, Ministry of Justice, Tokyo, Japan.
- Standring S (Editor-in-Chief), 2016. *Gray's anatomy: The anatomical basis of clinical practice*, 41th Ed. Churchill Livingstone Elsevier, London, UK.
- Suenaga H, Momose N, Kobayashi Y, Syukuwa Y, 2012. Trial and development of effective instructional materials for echocardiography (in Japanese with English abstract), *Japan. J. Med. Ultrason.* 39(4), 457-462.
- Takayanagi M, Sato M, Nakajima Y, Okada M, Ueki I, Kobayashi S, Machida M, Yamamoto M, Sato F, 2007. Trial of gross anatomy program using pig hearts and analysis of student' reports (in Japanese). *Kango Kyoiku* 48(6), 500-507.
- Takayanagi M, Nozaki M, Inoue Y, Murakami K, Kawashima T, Sugahara M, Kobayashi S, Machida M, Takayanagi T, Kikuchi Y, Imajo N, Sato F, 2012. Trial of gross anatomy program using pig kidneys for nursing students (in Japanese). *Kango Kyoiku* 53(5), 409-414.
- Takayanagi M, Nozaki M, Kawashima T, Hoshi H, Kamijo TC, Sato F, 2016. Outcome model analysis-based results of actual tissue anatomy exercise for nursing students using non-fixed pig organs. *J. Ergonomic Technology* 16, 8-14.
- Terada H, Fujita T, 2004. *Guidebook of gross anatomy (in Japanese)*, 11th ed. Nanzando, Tokyo.
- Umezu M, Park YK, 2009. Mitral valve simulator and training of coronary artery anastomosis. *Circulation Up-to-Date* 4, 15-21.
- Yamaguchi R, Mochiki K, Kuzumi T, Nagato Y, Haruki Y, 2009. Evaluation of education methods using models and pig hearts specimens for learning anatomy (2nd) (in Japanese). *Nursing Education (Japanese Nursing Association)* 39, 187-189.
- Zhang Y, Ou TW, Jia JG, Gao W, Cui X, Wu JT, Wang G, 2008. Novel biologic model for percutaneous renal surgery learning and training in the laboratory. *Urology* 72, 513-516.