

東邦大学学術リポジトリ



OPAC

東邦大学メディアセンター

タイトル	Delayed bleeding following cold snare polypectomy for small colorectal polyps in patients taking antithrombotic agents
別タイトル	抗血栓薬内服患者におけるコールドポリペクトミーを用いた小ポリープ切除後の遅発性出血について
作成者（著者）	牧野, 敏之
公開者	東邦大学
発行日	2017.08.24
掲載情報	東邦大学大学院医学研究科 博士論文. 10.
資料種別	学位論文
内容記述	主査：五十嵐良典 / タイトル：Delayed bleeding following cold snare polypectomy for small colorectal polyps in patients taking antithrombotic agents / 著者：Toshiyuki Makino, Akira Horiuchi, Masashi Kajiyama, Naoki Tanaka, Kenji Sano, Iruru Maetani / 掲載誌：Journal of Clinical Gastroenterology / 巻号・発行年等：52(6):502-507, 2018
著者版フラグ	ETD
報告番号	32661乙第2872号
学位記番号	乙第2720号
学位授与年月日	2017.08.24
学位授与機関	東邦大学
DOI	info:doi/10.1097/MCG.0000000000000802
メタデータのURL	https://mylibrary.toho-u.ac.jp/webopac/TD74616241

Revised Manuscript JCG16743

ORIGINAL ARTICLE

Delayed bleeding following cold snare polypectomy for small colorectal polyps in patients taking antithrombotic agents

Toshiyuki Makino, MD,^{1,2} Akira Horiuchi, MD,¹ Masashi Kajiyama, MD,¹ Naoki Tanaka, MD,¹ Kenji Sano, MD,³ Iruru Maetani, MD²

¹Digestive Disease Center, Showa Inan General Hospital, Komagane, Japan

²Division of Gastroenterology and Hepatology, Department of Internal Medicine, Toho University Ohashi Medical Center, Tokyo, Japan

³Department of Laboratory Medicine, Shinshu University Hospital, Matsumoto, Japan

Short Title: Delayed bleeding following cold snare polypectomy

Conflicts of Interest and Source of Funding: None.

Corresponding author: Akira Horiuchi, MD, Digestive Disease Center, Showa Inan General Hospital, 3230 Akaho, Komagane 399-4117, Japan

Phone: +81-265-82-2121 Fax: +81-265-82-2118

Email: horiuchi.akira@sihp.jp

Background: This study compared the incidence of delayed bleeding following two methods of cold snare polypectomy for colorectal polyps in patients taking antithrombotic agents.

Methods: Patients undergoing cold snare polypectomy for colorectal polyps ≤ 10 mm without discontinuation of antithrombotic agents were enrolled. This was a retrospective study of a prospectively collected cohort based on a historical comparison of two time periods. A traditional cold snare was used between January 2012 and December 2013 and a dedicated cold snare was used between January 2014 and December 2015. Patients' and polyps' characteristics, antithrombotic agents used, the snare used, the number of clips used and adverse events were documented from a hospital on-line database. Delayed bleeding was defined as bleeding that required endoscopic treatment within 2 weeks after polypectomy. The submucosal layer of the resected polyps (6-10 mm) was histologically examined for the presence of injured arteries.

Results: 172 patients having 370 eligible polyps were enrolled; traditional cold snare group, N=100 (212 polyps) and dedicated cold snare group, N=72 (158 polyps). The patients' and polyps' characteristics were similar between the two groups. Hemostatic clips were used more often with the traditional than dedicated cold snares [33/100 (33%) vs. 13/72 (18%), $P = 0.044$]. Delayed bleeding following cold snare polypectomy occurred in 1.2% (2/172); 0% (0/72) with dedicated snare vs. 2% (2/100) with the traditional snare ($P=0.63$). The presence of histologically demonstrated injured submucosal arteries with the dedicated cold snare was significantly less than with the traditional cold snare [4.1% (4/98) vs. 16% (17/105), $P=0.009$].

Conclusions: Colorectal polyps ≤ 10 mm can be removed without an increase in delayed bleeding using dedicated cold snare polypectomy in patients taking antithrombotic agents.

INTRODUCTION

Screening for colorectal cancer in asymptomatic patients can reduce the incidence and mortality of colorectal cancer [1] and forms the basis for surveillance colonoscopy at appropriate intervals [2]. Current practice guidelines consider polypectomy a high-risk procedure unless antithrombotic agents are temporarily discontinued [3]. However, many candidates for colorectal cancer screening also take antithrombotic agents for treatment or prevention of cardiovascular or cerebrovascular diseases and there is often some reticence about withholding them. Generally, antithrombotic agents including aspirin are temporarily discontinued before polypectomy in Japan. In addition, less than half of the endoscopy units surveyed in the United States routinely continue aspirin before screening colonoscopies despite evidence the benefits outweigh the risks [4]. Typically, post polypectomy bleeding occurs in approximately 1% in patients and is delayed occurring 2 to 7 days after polypectomy [5,6]. The data on the incidence of delayed bleeding for colorectal small polyps without discontinuation of antithrombotic agents is limited especially when one considers the polypectomy technique (eg, cold snare or hot snare polypectomy) [7].

Since 2011, our approach has been to perform screening endoscopy without discontinuation of antithrombotic agents based on the fact that removal of small polyps by cold snaring has been associated with a low rate of adverse events and over 90% of polypectomies are performed for diminutive (≤ 5 mm) or small (6–9 mm) lesions [8-13]. Further, we hypothesized this would be safe because delayed bleeding appears related to damage to the submucosal arteries caused by electrocautery and this was markedly less frequent using traditional cold snares or dedicated cold snare polypectomy [7,8]. Thus, if

large polyps were found, patients were rescheduled and the procedure repeated after interruption of antithrombotic agents. For small polyps we perform cold snare polypectomy immediately without stopping antithrombotic agents. The aim of this study was to retrospectively compare the incidence of delayed bleeding following cold snare polypectomy using the traditional cold polypectomy snare and dedicated cold polypectomy snare in patients taking antithrombotic agents.

METHODS

Study design

We prospectively recorded the data of all colonoscopic examinations performed at Showa Inan General Hospital from January 2012 to December 2015 using a computer database program. This is a case-control study based on historical comparisons of patients in two time periods, with data being collected retrospectively (i.e., is a retrospective study of a prospectively collected cohort).

The Institutional Review Board of Showa Inan General Hospital approved the study protocol. All subjects gave written informed consent for the endoscopic procedure. Subjects referred and scheduled for screening, surveillance, or diagnostic colonoscopy were prospectively enrolled between January 2012 and December 2015; during this time 14,266 subjects underwent colonoscopy. Since 2011, antithrombotic agents including antiplatelet agents and anticoagulants have not been discontinued for screening, surveillance, or diagnostic endoscopy in patients (the policy of our endoscopy unit). An audit was conducted for a 4-year period (2012-2015) of consecutive patients undergoing cold snare polypectomy for colorectal polyps ≤ 10 mm in diameter without discontinuation of antithrombotic agents.

Patients were not randomized to cold snare polypectomy with either the traditional cold snare or dedicated cold snare. The traditional cold snare was used between January 2012 and December 2013. In January 2014 the dedicated cold snare became consistently available in our endoscopy unit and cold snare polypectomy was performed using only dedicated cold snare between January 2014 and December 2015.

Endoscopists and Equipment

All procedures were performed by 1 of 3 experienced endoscopists. A pediatric variable-stiffness colonoscope (Olympus PCF-Q260AZI; Olympus medical systems, Tokyo, Japan) was used in all subjects. The instrument has a distal tip diameter of 11.7 mm and insertion tube diameter of 11.8 mm (working length, 133 cm; accessory channel diameter, 3.2 mm). As is our standard practice, a transparent short cap (Olympus D-201-12704) with an outer diameter of 13.4 mm and inner diameter of 12 mm was attached to the tip of the colonoscope in an attempt to improve adenoma detection rate [14]. The edge of the cap protrudes for approximately 4 mm beyond the tip of the colonoscope. Retroflexion in the rectum was routinely performed. The standard bowel preparation was performed using a polyethylene glycol-electrolyte solution (Ajinomoto Pharmaceutical Co, Tokyo, Japan). All the procedures were conducted under nurse administered propofol sedation [15].

Procedure

Cecal intubation was verified by identification of the appendiceal orifice and ileocecal valve. Endoscopists were instructed to measure polyp size using the size of the snare catheter or the snare diameter. Polyps were measured in increments of 1 mm. The time taken to reach the

cecum, the intubation rate of the terminal ileum, the procedure time, the location of polyps (right side was defined at or proximal to the splenic flexure), and the size and morphology (flat type was defined height <2.5 mm at measured by the diameter of the 2.4 or 2.6-mm snare catheter) of each polyp were recorded. The size of polyp was also estimated using the open-forceps technique, forceps span = 7.3 mm. All colorectal polyps up to 10 mm found, except for tiny hyperplastic polyps in the rectum and distal sigmoid colon, were removed.

The traditional cold snare polypectomy snare used (Snare Master™ snare; SD-210U-10; Olympus, Tokyo, Japan) has a maximal snare diameter of 10 mm or a dual loop wire snare (SN-3316LX, Medico's Hirata Inc., Osaka, Japan) with a loop size of 33/16 mm. The dedicated cold snare used was the Exacto™ cold snare that has a maximum snare diameter of 9 mm (US endoscopy, Mentor, USA). The snare wire diameter of the traditional cold snare polypectomy snare is 0.47 mm and 0.30 mm for the Exacto™ cold snare. The instrument was rotated for polypectomy, to align the polyp with the instrument channel at 6 o'clock. The snare was opened enough to allow a rim of normal tissue to be ensnared and resected. The scope was angled into the colon wall while the snare was pushed forward. The polyp and small rim of normal tissue was snared closely without tenting and guillotined. If submucosa tissue was entrapped, the captured tissue was guillotined repeatedly in order to remove the polyp completely. Cold snare polypectomy using the "pull technique" that is by ensnaring the polyp and pulling it into the colonoscope channel followed by transection of the polyp with simultaneous suctioning [11] is not used at our endoscopy unit. The absence of visible residual polyp tissue was also confirmed endoscopically and using narrow band imaging before the completeness of the polyp resection was determined pathologically. If the residual polyp was seen at the polypectomy site, it was resected. The transected small polyps were sucked into a

trap. Larger polyps were retrieved using retrieval forceps without the use of the endoscopic suction channel in order to avoid fragmenting the samples. Submucosal injection of saline solution before polyp removal was not performed. Prophylactic clipping after polyp removal was not routinely performed, however hemostatic clipping was done for immediate bleeding. In our endoscopy unit immediate bleeding requiring hemostatic clipping was defined as spurting or oozing which continued for more than 30 seconds.

Data collection

The antithrombotic agents used, the snare used, the size, location, shape and pathology of all polyps, and the number of hemostatic clips used was prospectively recorded. All patients who underwent polypectomy visited our hospital two weeks after polypectomy to be informed of the pathological results of polyps removed. Adverse events and all gastrointestinal symptoms within two weeks after each polypectomy were recorded. For this retrospective study patients' and polyps' characteristics, antithrombotic agents used, the snare used, the number of clip used and adverse events were documented from a hospital on-line database.

Pathological examination

The snare used for cold snare polypectomy in this study (traditional cold snare or dedicated cold snare) remained blinded to the pathologist (KS) until after all the analyses were completed. After removal, excised polyp specimens were mounted with pins on Styrofoam plates and fixed in 10% formalin. They were examined grossly and following sectioning, they were examined using hematoxylin and eosin staining. The resection was considered complete histologically if vertical and lateral margins were free from neoplasia tissue. The submucosal

layer of the resected polyps of 6-10 mm in diameter was also specifically examined for the presence of arteries and injured arteries.

Outcome variables

The primary outcome measure was delayed bleeding within two weeks after cold snare polypectomy. Delayed bleeding was defined as remarkable bleeding that required the endoscopic treatment within 2 weeks after polypectomy. The submucosal layer of the resected polyps of 6-10 mm in diameter was also histologically examined for the presence of injured arteries.

Statistical analysis

Polyps were measured in increment of 1 mm. Statistical tests to compare the measured results for the two groups were as follows: the Chi-square test, with Yates' correction for continuity where appropriate, was used for comparison of categorical data. Fisher's exact test was used when the numbers were small. For parametric data, the Student's *t*-test was used when 2 means were compared. For nonparametric data, Mann-Whitney rank sum test was used when 2 medians were compared. Differences were considered significant if the *P* value was less than 0.05. Statistical analysis was performed by using SigmaStat 3.5 software (Systat Software, Inc., San Jose, CA).

All authors had access to the study data and had reviewed and approved the final manuscript.

RESULTS

Patients

One hundred seventy two patients (men 88 and women 84) having 370 polyps were included

in this study; traditional cold snare group, N=100 (212 polyps) and dedicated cold snare group, N=72 (158 polyps). Table 1 shows the patient baseline characteristics and clinical features of the enrolled patients in this study. Patients continued to take antithrombotic agents (aspirin 33 vs. 25, warfarin 39 vs. 20, clopidogrel 12 vs. 12, concomitant use of warfarin and clopidogrel 8 vs. 6, dabigatran 6 vs. 4, apixaban 2 vs. 5) (Table 1). The patients' baseline characteristics including the use of antithrombotic agents were similar between the two groups (Table 1).

Polypectomy

There were no significant differences in cecum intubation rate, mean cecal intubation time, intubation rate of terminal ileum, and mean procedure time between the traditional cold snare group and the dedicated cold snare group (Table 2). The sizes of polyps removed were also similar between the two techniques: (traditional cold snare group, 212 polyps, average size 6.4 mm, median size 6.5 mm; dedicated cold snare group, 158 polyps, average size 6.5 mm, median size 6.5 mm). The complete retrieval rates of polyps were similar between the two techniques [98% (207/212) vs. 98% (153/158), P= 0.88] (Table 2).

Hemostatic clips were used more often with the traditional than dedicated cold snares (i.e., in 33/100 (33%) and 13/72 (18%) patients) in the traditional and dedicated cold snare groups, respectively (P = 0.044) (Table 3). The median number of hemostatic clips per patient used after polypectomy in the traditional cold snare group (2 clips/patient clipped, range 1 to 4) was greater than that of the dedicated (1 clip/patient clipped, range 1 to 2) (P= 0.15) (Table 2).

Delayed bleeding following cold snare polypectomy was seen in 1.2% (2/172) (Table 3). Interestingly, delayed bleeding was only seen in patients receiving dabigatran or apixaban (one

each) and using the traditional cold snare technique. The frequency of delayed bleeding was 2/17 among those taking dabigatran or apixaban vs. 0/155 of those using aspirin, warfarin, chlopidogrel or both ($P = 0.002$). There was a significant difference, in terms of delayed bleeding, between new generation and older anticoagulants. However, the number using the new anticoagulants, dabigatran or apixaban, was small making it unclear whether they represent an especially high-risk group or this result occurred by chance; further studies are needed. In this study perforation and untreatable bleeding did not occur.

The characteristics of size, location, shape, and pathology of polyps removed in the two groups were not significantly different between the two groups (Table 4). Tissues could be examined for arteries in the submucosal layer in 85% (105/124) and 100% (98/98) of resected polyps (6-10 mm) in traditional cold snare group and dedicated cold snare group, respectively (Table 5). Figure 1 shows endoscopic finding and the pathological specimen of resected polyp in a patient with delayed bleeding in traditional cold snare group. Damage of arteries in the submucosal layer was present in the resected specimen. On the other hand, figure 2 shows endoscopic finding and the pathological specimen of resected polyp in a patient without damage of arteries in the submucosal layer in dedicated cold snare group. The presence of submucosal arteries detected in the submucosal layer was not significantly different between in the traditional cold snare group and in the dedicated cold snare group [34% (36/105) vs. 26% (25/98), $P=0.23$] (Relative risk 1.3; 95% confidence interval 0.9-2.1). However, the presence of histologically demonstrated injured arteries in the submucosal layer with dedicated cold snare was significantly less than with traditional cold snare [4.1% (4/98) vs. 16% (17/105), $P=0.009$] (Relative risk 4.0; 95% confidence interval 1.4-11).

DISCUSSION

ASGE guidelines for colonoscopy in patients requiring antithrombotics recommend that antithrombotic drugs (thienopyridines and warfarin) be temporarily discontinued [3].

Because cold snare polypectomy has been associated with a low rate of postpolypectomy bleeding [13] and we had experienced no delayed bleeding requiring hemostasis after cold snare polypectomy despite continuation of anticoagulants [7], we instituted a policy of not discontinuing antithrombotic therapy for cold snare polypectomy of small polyps. Here, we retrospectively analyzed the risk of delayed bleeding following cold snare polypectomy in patients in whom antithrombotic drugs were not discontinued. Delayed bleeding occurred in 1.2% (2/172) which was similar to that reported following hot snare polypectomy in patients without antithrombotic drugs [5,6]. This result suggests that colorectal polyps ≤ 10 mm in size can be removed by cold snare polypectomy without an increase in the risk of delayed bleeding despite continuing antithrombotic agents. One caveat to this inclusion is that we used hemostatic clips post polypectomy in approximately 1/3 of cases.

This retrospective study is consistent with prior studies suggesting that cold snare polypectomy using a dedicated cold snare has advantages over using a traditional snare possibly because the dedicated cold snare produces less damage to arteries to the submucosal layer than does traditional cold snares [8]. In our previous study we showed that delayed bleeding requiring hemostasis occurred significantly less commonly after cold snare polypectomy than hot snare polypectomy despite continuation of anticoagulants (0% vs.14%, $P=0.027$) and that injured submucosal arteries were seen less frequently following cold snare polypectomy than following hot snare polypectomy (22% vs. 39%, $P=0.023$) [7]. Another recent study compared dedicated cold snare vs. traditional cold snare for cold snaring and

showed a trend for lesser damage to arteries in the submucosal layer was associated with the thinner wire used for the especially designed cold snare (3.1% vs. 6.7%, $P=0.24$) [8]. In that study, the injury to submucosal arteries was significantly less with dedicated cold snares [4.1% (4/98) vs. 16% (17/105), $P=0.009$] for polyps 6-10 mm in diameter suggesting that polypectomy technique, snare used, and polyp size may all be important.

Regardless of the snare used we used the re-snaring technique where the captured tissue is guillotined repeatedly in order to remove the polyp completely for cold snare polypectomy. We suspect that pulling the trapped submucosal layer into the channel of the endoscope with the “pull” cold snare polypectomy technique may damage submucosal arteries and result in a higher risk of delayed bleeding especially in patients taking antithrombotic agents. Based on the results of previous study we prefer the dedicated cold snare for the re-snaring technique [8].

In our practice prophylactic clipping after polyp removal is not routinely performed because prophylactic use of hemostatic clips has not proven to be effective for prevention of delayed bleeding after conventional polypectomy even in patients not receiving antithrombotic drugs [16]. Clinically, delayed bleeding is more important than that of immediate bleeding in the routine clinical practice in that immediate bleeding can be controlled during endoscopy. In our endoscopy unit immediate bleeding requiring hemostatic clipping was defined as spurting or oozing which continued for more than 30 seconds. We compared the number of hemostatic clips used after polypectomy. Hemostatic clips were used more often with the traditional than dedicated cold snares (i.e., in 33/100 (33%) and 13/72 (18%) patients) in the traditional and dedicated cold snare groups, respectively ($P = 0.044$) (Table 3). In addition, the number of clips/patient receiving hemostatic clips was greater with the traditional cold snare (median 2 vs. 1, $P=0.15$) (Table 2). These results suggest that the incidence of spurting or oozing continuing

for more than 30 seconds was higher after cold snare polypectomy using a traditional cold snare than using a dedicated cold snare. The histological data of the resected specimens also support that hemostatic clipping was less required for the immediate bleeding following polypectomy using the dedicated cold snare.

The complete resection rate was significantly greater with the dedicated cold than the traditional cold snare [91% (89/98) vs. 79% (88/112), $P= 0.015$] with a marked difference with 8-10 mm polyps of both flat or pedunculated [8]. Our experience was that it seemed easier for endoscopists to remove 8-10 mm polyps of flat or pedunculated using the dedicated cold snare than using traditional cold snare. In retrospect, we found an additional cost advantage due to the decrease in the need of hemostatic clipping following dedicated cold snare polypectomy.

This study has some limitations. In addition to the small sample size, this study was conducted in a single hospital in Japan, was retrospective and consisted of consecutive groups. Nonetheless, the results are consistent with our previous observations. Larger, randomized multicenter trials are needed to confirm the superiority of specially designed thin wire cold snare polypectomy and to better define the desired characteristics.

In conclusion, colorectal small polyps can be removed without delayed bleeding by cold snare polypectomy using the dedicated cold snare even in patients taking antithrombotic agents. One possible exception is the use of the new anticoagulants, dabigatran or apixaban. Delayed bleeding following polypectomy appears to be related to injury of vessels in the submucosal layer related possibly to polypectomy technique.

REFERENCES

1. Zauber AG, Winawer SJ, O'Brien MJ, et al. Colonoscopic polypectomy and long-term prevention of colorectal-cancer deaths. *N Engl J Med* 2012;366:687-96.
2. Lieberman DA, Rex DK, Winawer SJ, et al. Guidelines for colonoscopy surveillance after screening and polypectomy: a consensus update by the US multi-society task force on colorectal cancer. *Gastroenterology* 2012;143:844-57.
3. ASGE Standards of Practice Committee: Anderson MA, Ben-Menachem T, Gan SI, et al. Management of antithrombotic agents for endoscopic procedures. *Gastrointest Endosc* 2009; 70: 1060–70.
4. Robbins R, Tian C, Singal A, et al. Periprocedural management of aspirin during colonoscopy: a survey of practice patterns in the United States. *Gastrointest Endosc* 2015; 82: 895-900.
5. Gatto NM, Frucht H, Sundararajan V, et al. Risk of perforation after colonoscopy and sigmoidoscopy: a population-based study. *J Natl Cancer Inst* 2003;95:230–236.
6. Heldwein W, Dollhopf M, Rosch T, et al. The Munich Polypectomy Study (MUPS): prospective analysis of complications and risk factors in 4000 colonic snare polypectomies. *Endoscopy* 2005;37:1116-22.
7. Horiuchi A, Nakayama Y, Kajiyama M, et al. Removal of small colorectal polyps in anticoagulated patients: a prospective randomized comparison of cold snare and conventional polypectomy. *Gastrointest Endosc* 2014;79; 417-23.
8. Horiuchi A, Hosoi K, Kajiyama M, et al. Prospective, randomized comparison of 2 methods of cold snare polypectomy for small colorectal polyps. *Gastrointest Endosc* 2015;82:686-92.

9. Regula J, Rupinski M, Kraszewska E, et al. Colonoscopy in colorectal-cancer screening for detection of advanced neoplasia. *N Engl J Med* 2006; 355:1863–72.
10. Lieberman D, Moravec M, Holub J, et al. Polyp size and advanced histology in patients undergoing colonoscopy screening: implications for CT colonography. *Gastroenterology* 2008; 135: 1100–5.
11. Deenadayalu VP, Rex DK. Colon polyp retrieval after cold snaring. *Gastrointest Endosc*. 2005;62:253–6.
12. Tolliver KA, Rex DK. Colonic polypectomy. *Gastroenterol Clin North Am*. 2008;37:229-51.
13. Repici A, Hassan C, Vitetta E, et al. Safety of cold polypectomy for <10mm polyps at colonoscopy: a prospective multicenter study. *Endoscopy* 2012;44:27-31.
14. Horiuchi A, Nakayama Y, Kajiyama M, et al. Benefits and limitations of cap-fitted colonoscopy in screening colonoscopy. *Dig Dis Sci* 2013; 58: 534-9.
15. Horiuchi A, Nakayama Y, Fujii H, et al. Psychomotor recovery and blood propofol level in colonoscopy when using propofol sedation. *Gastrointest Endosc* 2012; 75: 506-12.
16. Shioji K, Suzuki Y, Kobayashi M, et al. Prophylactic clip application does not decrease delayed bleeding after colonoscopic polypectomy. *Gastrointest Endosc* 2003; 57: 691–4.

Figure legends

Fig. 1. Endoscopic finding (left) and the pathological specimen of resected polyp (right) in a patient with delayed bleeding. Asterisk shows injured artery in the submucosal layer.

Fig. 2. Endoscopic finding (left) and the pathological specimen of resected polyp (right) in a patient without the damage of arteries in the submucosal layer.

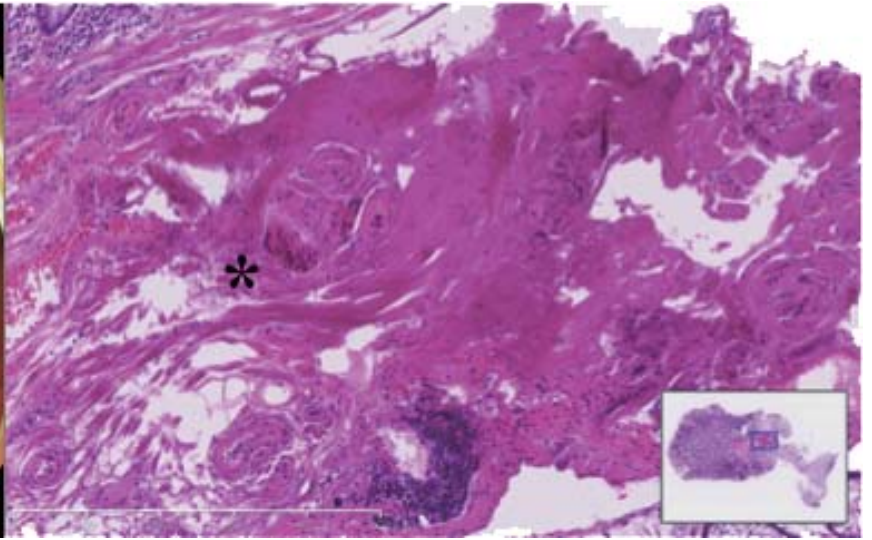
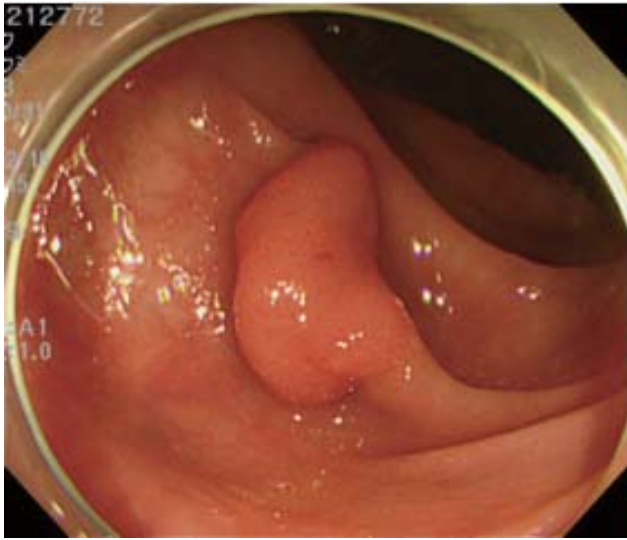


Fig.1

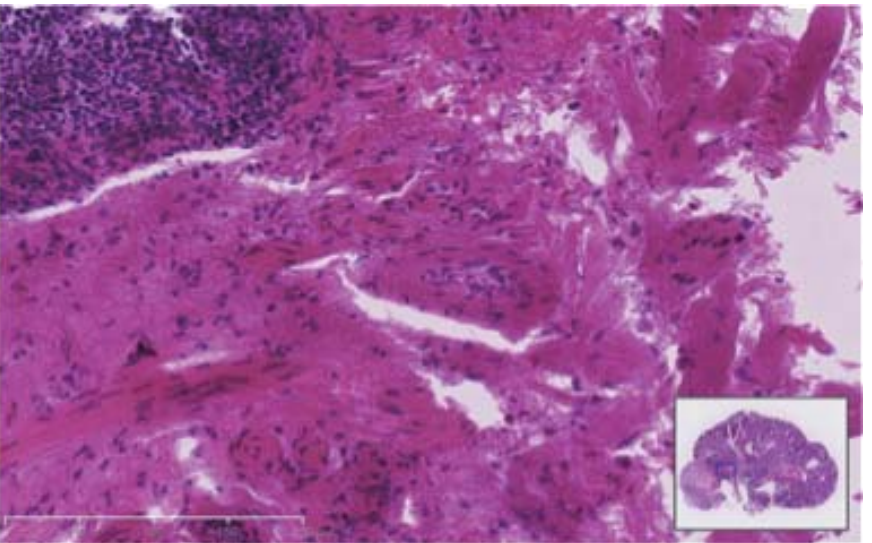
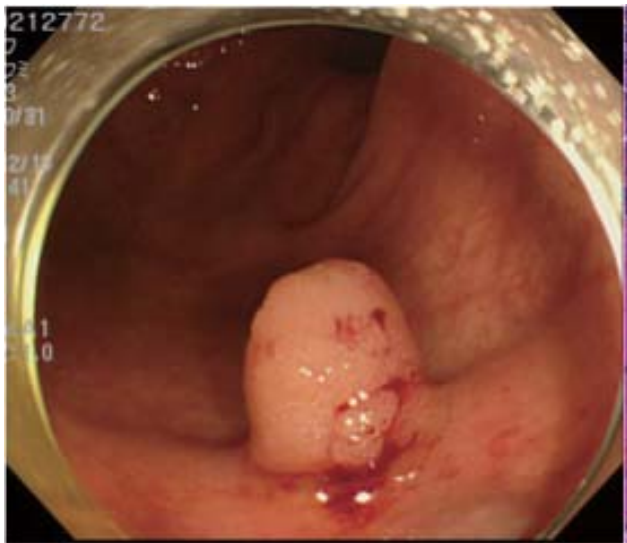


Fig.2