

東邦大学学術リポジトリ

Toho University Academic Repository

タイトル	Virtual histology intravascular ultrasound analysis of attenuated plaque and ulcerated plaque detected by gray scale intravascular ultrasound and the relation between the plaque composition and slow flow/no reflow phenomenon during percutaneous coronary intervention
別タイトル	グレイスケール血管内超音波上の深部エコー減衰プラークと潰瘍性プラークのバーチャルヒストロジー血管内超音波による解析、およびプラーク性状と経皮的冠動脈インターベンション中のスローフロー、ノーリフロー現象との関係
作成者（著者）	天野, 英夫
公開者	東邦大学
発行日	2013.07
掲載情報	東邦大学大学院医学研究科 博士論文. 66.
資料種別	学位論文
内容記述	主査：杉薫 / タイトル：Virtual histology intravascular ultrasound analysis of attenuated plaque and ulcerated plaque detected by gray scale intravascular ultrasound and the relation between the plaque composition and slow flow/no reflow phenomenon during percutaneous coronary intervention / 著者：Hideo Amano, Kenji Wagatsuma, Jyunichi Yamazaki, Takanori Ikeda / 掲載誌：Journal of Interventional Cardiology / 巻号・発行年等：26(3):295-301, 2013 / 本文ファイル：査読後原稿
著者版フラグ	ETD
報告番号	32661乙第2794号
学位授与年月日	2013.07.25
学位授与機関	東邦大学
DOI	info:doi/10.1111/joic.12035
メタデータのURL	https://mylibrary.toho-u.ac.jp/webopac/TD71836927

Virtual histology intravascular ultrasound analysis of attenuated plaque and ulcerated plaque detected by gray scale intravascular ultrasound and the relation between the plaque composition and slow flow/no reflow phenomenon during percutaneous coronary intervention

Hideo Amano, M.D., Kenji Wagatsuma, M.D., Jyunichi Yamazaki, M.D., and Takanori Ikeda, M.D.

From Department of Cardiovascular Medicine, Toho University Faculty of Medicine

Address for repairs: Hideo Amano, M.D., Department of Cardiovascular Medicine, Toho University Faculty of Medicine, 5-21-16 Ohmorinishi Ohtaku, Tokyo 143-8541, Japan, Fax: +81-3-3762-4151, e-mail: 300095ah@med.toho-u.ac.jp

There is no financial association that might pose any potential conflict of interest to disclose.

Abstract:

Objective: This study aimed to assess the plaque characteristics of attenuated and ulcerated plaques in virtual-histology intravascular ultrasound (VH-IVUS) and the incidence of slow flow/no reflow during percutaneous coronary intervention (PCI).

Background: The attenuated and ulcerated plaques are thought as embolic prone plaque, however the plaque characteristics are unclear.

Methods: Subjects were 119 patients 121 lesions undergoing VH-IVUS before coronary stenting. These lesions were divided into the 15 lesions showing attenuated plaque, 24 lesions showing ulcerated plaque, and 82 lesions revealing neither attenuated nor ulcerated plaque (the control group).

Results: Fibro-fatty tissue in attenuation group was significantly larger than the control group ($27.5 \pm 9.5\%$ vs. $13.9 \pm 8.2\%$, $p < 0.01$, $3.5 \pm 1.9 \text{ mm}^2$ vs. $1.6 \pm 1.2 \text{ mm}^2$, $p < 0.01$).

Necrotic core in ulceration group was significantly larger than the control group ($20.7 \pm 9.0\%$ vs. $15.9 \pm 9.0\%$, $p < 0.05$, $2.5 \pm 1.3 \text{ mm}^2$ vs. $1.7 \pm 1.0 \text{ mm}^2$, $p < 0.01$). Dense calcium in ulceration group was significantly larger than the control group ($12.3 \pm 6.4\%$ vs. $8.3 \pm 7.1\%$, $p < 0.05$, $1.4 \pm 0.7 \text{ mm}^2$ vs. $0.9 \pm 0.8 \text{ mm}^2$, $p < 0.01$). In the ulceration group, the necrotic core area of acute coronary syndrome was significantly larger than the stable angina pectoris ($3.0 \pm 1.4 \text{ mm}^2$ vs. $1.8 \pm 1.0 \text{ mm}^2$, $p < 0.05$)

The incidence of slow flow/no reflow was significantly higher in the attenuation and ulceration group

than the control group (20.0% (3/15), 20.8%(4/24) vs. 4.9% (4/82), $p < 0.05$, 0.05).

Conclusion: The attenuated plaque had significantly larger fibro-fatty tissue. The ulcerated plaque had significantly larger necrotic core and dense calcium. The lesions with the attenuated and the ulcerated plaque had more frequent slow flow/no reflow during PCI.

Introduction

There are reports that grayscale intravascular ultrasound (IVUS) detection of echo attenuation behind lesion sites in the absence of dense calcification is often seen in acute coronary syndrome (ACS) patients, and that coronary microembolism and slow/no reflow often occur when lesions have such findings at the time of coronary intervention.¹ It has also been reported that ruptured plaque is more often seen in ACS patients than in patients with stable angina pectoris (SAP).² Fibrous cap in grayscale IVUS is unclear, the ulcerated plaque may include ruptured plaques that contain fibrous cup. However, there are few reports about plaque composition and slow flow/no reflow during percutaneous coronary intervention (PCI) of the ulcerated plaques. Virtual Histology-IVUS (VH-IVUS) analyzes radiofrequency signals acquired by IVUS and displays this by classifying plaque into four components. The predictive accuracy of plaque composition by VH-IVUS to corresponding pathological tissue is good at about 90 percent.³ The objective of the present study was to investigate the plaque composition of attenuated and ulcerated plaque by VH-IVUS and the relation between the plaque composition and slow flow/no reflow during PCI.

Method

Patient population

Study was conducted on consecutive 119 patients 121 lesions treated by percutaneous coronary PCI for de novo coronary stenosis at our institution between July 2005 and February 2007, and for which good images were obtained through IVUS studies conducted before the PCI procedure. Cases of vessels 2.5mm or less in size, stent restenosis, vein graft lesions, cases where the IVUS catheter was not able to cross the lesion prior to PCI due to calcification or other reasons, cases of cardiogenic shock, and cases with large

amounts of thrombus making it difficult to discriminate from plaque in IVUS, were excluded from this study. This protocol was approved by the Toho University Omori Medical Center Ethics Committee.

PCI procedure

All patients received aspirin (81mg/day) and ticlopidine hydrochloride (200mg/day) before PCI. There were no patients who received glycoprotein IIb/IIIa inhibitors, because this drug is not available in Japan. Pre-intervention angiography was performed after the intracoronary administration of 0.1-0.2 mg nitroglycerin. When there were large amounts of thrombus present, IVUS was conducted after thrombus aspiration was performed. This was closely followed by dilatation by an appropriately sized balloon and stent deployment. During the procedure, 5000 to 10000 units of heparin were used to maintain activated clotting time at 250 to 300 seconds. Thrombolysis In Myocardial Infarction (TIMI) flow grade and corrected Thrombolysis In Myocardial infarction frame count (CTFC) was assessed as described previously.^{4,5} Slow flow was defined as TIMI flow grade of 1 or 2, and no reflow was TIMI flow grade 0 without mechanical obstruction on the angiography immediately after stent deployment.

IVUS procedure

After the intracoronary administration of 0.1-0.2 mg nitroglycerin, a 20-MHz 3.2-F phased-array IVUS catheter (Eagle Eye, Volcano Therapeutics, Rancho Cordova, California, USA) was pulled back at the speed of 1 mm/s from the distal of the culprit lesion to the distal of the culprit lesion. The culprit vessel was identified on the basis of clinical, ECG, and angiographic data. In SAP patients, the culprit vessel was considered to be the ischemia-related vessel identified by exercise stress test.

IVUS data analysis

The grayscale IVUS and captured radiofrequency data were written onto a CD-R or DVD-R, off-line analyses was performed by an independent operator blinded to the patients' clinical data. Using Volcano In-Vision Gold imaging system software (IVUS Lab, pcVH2.1, Volcano Therapeutics), lumen, external elastic membrane (EEM), plaque and media (defined as EEM minus lumen) cross sectional areas (CSA)

and plaque burden (defined as plaque and media divided by EEM) were measured in all slices. This imaging software automatically calculates plaque and media CSA, and categorizes the plaque into four components. These are color-coded with fibrous as green, fibro-fatty as greenish yellow, necrotic core as red, and calcium as white, and are displayed as percent plaque area. Attenuated plaque was defined as echo attenuation behind coronary atheroma without significant calcification shown in grayscale IVUS (Figure 1).¹ Ulcerated plaque was defined as a recess in the plaque beginning at the luminal-intimal border (Figure 1).⁶ Lesions were divided into 3 groups. The attenuation group was defined as the lesions showing attenuated plaque (15 patients 15 lesions). The ulceration group was defined as the lesions showing ulcerated plaque (24 patients 24 lesions). The control group was defined as the lesions revealing neither attenuated nor ulcerated plaque (80 patients 82 lesions). There were no duplicated lesions of attenuation group and ulceration group.

Statistical analysis

Statistical analysis was performed using Stat View version 5.0 (SAS Institute Inc., Cary, North Carolina). Continuous variables were compared using paired Student's t tests and are presented as mean \pm SD. Categorical variables were compared using chi-square analysis and are presented as frequencies. A p value <0.05 was considered statistically significant.

Results

For patient characteristics, there were no significant differences between the attenuation group, ulceration group and control group concerning age, gender, or risk factors (Table 1). There were no significant differences in the number of lesion vessels, lesion site, or lesion morphology. Reference vessel diameter (RD) was significantly larger ($p<0.05$) in the ulceration group, with the ulceration group 3.41 ± 0.58 mm and the control group 3.15 ± 0.51 mm (Table 2). There were no significant differences in thrombus, TIMI flow, CTFC, thrombectomy. The incidence of slow flow/no reflow was significantly

higher in the attenuation group ($p<0.05$) with 20.0% (3/15) in the attenuation group and 4.9% (4/82) in the control group. The incidence of slow flow/no reflow was significantly higher in the ulceration group ($p<0.05$) with 20.8% (4/24) in the ulceration group and 4.9% (4/82) in the control group (Table 3). Regarding VH-IVUS analysis, %Fibrous tissue in attenuation group was significantly lower than the control group ($p<0.05$), with the attenuation group $55.7 \pm 9.5\%$ and the control group $61.7 \pm 9.9\%$. %Fibro-fatty tissue in attenuation group was significantly higher than the control group ($p<0.01$), with the attenuation group $27.5 \pm 9.5\%$ and the control group $13.9 \pm 8.2\%$ (Table 4). Fibro-fatty area in attenuation group was significantly larger than the control group, with the attenuation group $3.5 \pm 1.9 \text{ mm}^2$ and the control group $1.6 \pm 1.2 \text{ mm}^2$ ($p<0.01$) (Table 4).

In comparison between the ulceration group and control group, EEM CSA was significantly larger ($p<0.01$) in the ulceration group with ulceration group $19.7 \pm 4.9 \text{ mm}^2$ and control group $16.0 \pm 4.5 \text{ mm}^2$, and lumen CSA was significantly larger ($p<0.01$) in the ulceration group with ulceration group $7.6 \pm 3.0 \text{ mm}^2$ and control group $4.7 \pm 1.4 \text{ mm}^2$ (Table 4). In VH-IVUS analysis, %Fibrous tissue in ulceration group was significantly lower than the control group ($p<0.05$), with the ulceration group $56.9 \pm 10.0\%$ and the control group $61.7 \pm 9.9\%$. %Fibro-fatty tissue in ulceration group was significantly lower than the control group ($p<0.05$), with the ulceration group $10.4 \pm 5.8\%$ and the control group $13.9 \pm 8.2\%$. %Necrotic core in ulceration group was significantly higher than the control group ($p<0.05$), with the ulceration group $20.7 \pm 9.0\%$ and the control group $15.9 \pm 9.0\%$. %Dense calcium in ulceration group was significantly higher than the control group ($p<0.05$), with the ulceration group $12.3 \pm 6.4\%$ and the control group $8.3 \pm 7.1\%$. Necrotic core area in ulceration group was significantly larger than the control group, with the ulceration group $2.5 \pm 1.3 \text{ mm}^2$ and the control group $1.7 \pm 1.0 \text{ mm}^2$ ($p<0.01$). Dense calcium area in ulceration group was significantly larger than the control group, with the ulceration group $1.4 \pm 0.7 \text{ mm}^2$ and the control group $0.9 \pm 0.8 \text{ mm}^2$ ($p<0.01$) (Table 4). In the ulceration group, the necrotic core area of ACS was significantly larger than the SAP, with $3.0 \pm 1.4 \text{ mm}^2$, SAP $1.8 \pm 1.0 \text{ mm}^2$ ($p<0.05$) (Table 5).

Discussion

This study had the following outcomes: (1) The Fibro-fatty tissue in attenuation group was significantly larger than the control group. (2) The ulceration group had significantly larger EEM CSA than the control group. (3) The necrotic core and dense calcium in ulceration group was significantly larger than the control group. (4) In the ulceration group, the necrotic core area of ACS was significantly larger than the SAP. (5) The incidence of slow flow/no reflow was significantly higher in the attenuation and ulceration group than the control group.

Plaque composition of attenuated plaque

The histological conditions of the sections of high echo attenuation behind lesion sites are difficult to distinguish by grayscale IVUS. Because there is a good 90% or greater accuracy of VH-IVUS to pathological studies for each of the components³, and since in vivo assessment of the lesion can also be conducted at the same time, we used VH-IVUS to assess the echo attenuated slice. In the attenuated plaque, VH-IVUS showed fibro-fatty tissue to occupy a large portion of the area behind spotty calcification. It could be thought that the lipid components caused deep echo attenuation. In addition, there were also many cases where microcalcification was observed at the site where attenuation began, suggesting the possibility that microcalcification caused signal reflection, resulting in attenuation. In previous studies, pathological examinations of attenuated plaque in gray scale IVUS was revealed much lipid-rich plaque with microcalcification⁷, and VH findings of attenuated plaque was revealed more fibro-fatty tissue.⁸ Our study results were compatible with these findings.

Wu et al. report that attenuated plaques contain large amounts of necrotic core in VH⁹, Tsunoda et al. report attenuated plaque revealed underlying hypocellular fibrous plaque¹.

The cause of differences with our results might be thought the frequencies of SAP and ACS, the degree of ACS in present study was 60% (9/15), Wu was 100% (47/47), Tsunoda was 17% (1/6).

Slow flow/no reflow of attenuated plaque

In this present study, the attenuation group showed significantly higher frequency of slow flow/no

reflow during PCI than the Control group. In the previous study, the incidence of slow flow/no reflow during PCI reported 15-26%.^{7,10} Our study results were compatible with these findings.

Tanaka et al. argue that coronary microembolization is triggered by the PCI-engineered rupture of plaque, with no-reflow occurring as a result of the lipid pool flowing into the peripheral circulation.¹¹ Irie et al. report that the components of the lipid pool-like image on gray scale IVUS are almost all fibro-fatty¹², and in our study we considered the possibility that plaque was ruptured artificially by PCI, with the fibro-fatty plaque contents in the attenuated section causing flow reduction.

Plaque composition of ulcerated plaque

The necrotic core in ulceration group was significantly larger than the control. Commonly, it was thought that vulnerable plaque contained a large amount of necrotic core. Vulnerable plaque classified as: (1) plaque prone to rupture (60-75%), namely, plaque with a thin fibrous cap; (2) plaque prone to erosion (20-40%); and (3) plaque with a calcified nodule (2-7%).¹³

Thin fibrous cup cannot be detected in gray scale IVUS because of resolution.¹⁴ The ulcerated plaque have a possible to include the ruptured plaque, and erosion plaque.

The pathologic morphology of ruptured plaque and erosion plaque is tissue with large amount of necrotic core.¹⁵⁻¹⁷ Therefore, the ulcerated plaques thought be contained large amount of necrotic core in this study. It was suggested that the ulcerated plaque might be thought as one of the instability plaque because the fibrous cap is unclear in grayscale IVUS.

Furthermore, in ulceration group, the necrotic core of ACS was significantly larger than the SAP. It was suggested that the ulcerated plaque in ACS was highly vulnerable.

Slow flow/no reflow of ulcerated plaque

In our study the ulceration group had a significantly larger EEM CSA and necrotic core. Tanaka et al. report that subjects with no-reflow had large EEM CSA and plaque areas.¹² Although the large incidence of slow flow/no reflow in the ulceration group in our study as well could have been due to the large vessel diameter revealed in QCA and the fragments of vulnerable plaque carried to the peripheries, it is believed

that there was a larger percentage of slow flow/ no reflow during PCI because EEM CSA was larger in this group than in the control group.

In addition, it reported that lesions with large amounts of necrotic core on VH-IVUS could occur distal embolization¹⁸, so ulcerated plaque had greater slow flow/no reflow during PCI because of the large amount of necrotic core.

Study limitation

An issue in VH-IVUS is that thrombus is not coded. In our study, we aspirated thrombus to all possible extent especially in ACS patients, and measured the plaque by excluding mobile thrombus on IVUS. The ulceration groups included thrombus aspiration cases, it might be possible that the aspiration make ulceration. This was a retrospective study on a limited number of patients who were able to undergo IVUS studies. It would be necessary to conduct further large-scale studies.

Conclusion

The attenuated plaque had significantly larger fibro-fatty tissue. The ulcerated plaque had significantly larger EEM CSA. The ulcerated plaque had significantly larger necrotic core and dense calcium. The ulcerated plaque in ACS had significantly larger necrotic core. The attenuated plaque and the ulcerated plaque showed higher frequency of slow flow/no reflow during PCI.

References

1. Tsunoda T, Hara H, Nakamura M, et al. The Histopathological Validation of Coronary Atherosclerotic Lesions using Non-calcific Plaque Ultrasound Attenuation Images. *Jpn J Interv Cardiol* 2005;20:309-317.
2. Kotani J, Minz GS, Castagna MT, et al. Intravascular ultrasound analysis of infarct related and non-infarct related arteries in patients who presented with an acute myocardial infarction. *Circulation* 2003;107:2889-2893.
3. Nair A, Kuban BD, Tuzcu EM, et al. Coronary plaque classification with intravascular ultrasound

- radiofrequency data analysis. *Circulation* 2002;106: 2200–2206.
4. The TIMI Study Group. The Thrombolysis In Myocardial Infarction (TIMI) trial. Phase I findings. *N Engl J Med* 1985;312:932– 6.
 5. Gibson CM, Cannon CP, Daley WL, et al. TIMI frame count: a quantitative method of assessing coronary artery flow. *Circulation* 1996; 93:879–88.
 6. Mintz GS, Nissen SE, Anderson WD, et al. American College of Cardiology Clinical Expert Consensus Document on Standards for Acquisition, Measurement and Reporting of Intravascular Ultrasound Studies (IVUS). *J Am Coll Cardiol* 2001;37:1478 –92.
 7. Kimura S, Kakuta T, Yonetsu T, et al. Clinical significance of echo signal attenuation on intravascular ultrasound in patients with coronary artery disease. *Circ Cardiovasc Interv.* 2009 ;2:444-54.
 8. Yamada R, Okura H, Kume T, et al. Histological characteristics of plaque with ultrasonic attenuation: a comparison between intravascular ultrasound and histology. *J Cardiol* 2007;50:223-228.
 9. Wu X, Maehara A, Mintz GS, et al. Virtual Histology Intravascular Ultrasound Analysis of Non-Culprit Attenuated Plaques Detected by Grayscale Intravascular Ultrasound in Patients With Acute Coronary Syndromes. *Am J Cardiol* 2010;105:48–53.
 10. Lee SY, Mintz GS, Kim SY, et al. Attenuated Plaque Detected by Intravascular Ultrasound. *J Am Coll Cardiol Intv* 2009;2:65-72.
 11. Tanaka A, Kawarabayashi T, Nishibori Y, et al. No-reflow phenomenon and lesion morphology in patients with acute myocardial infarction. *Circulation* 2002;105:2148-2152.
 12. Irie H, Ito K, Koide M, et al. Assessment of lipid pool-like image of coronary artery plaque –gray scale IVUS v.s. Virtual Histology IVUS™. *Heart* 2007;39:136-140.
 13. Schaar JA, Muller JE, Falk E, et al. Terminology for high-risk and vulnerable coronary artery plaques. *Eur Heart J* 2004;25:1077-1082.
 14. Sawada T, Shite J, Garcia-Garcia HM, et al. Feasibility of combined use of intravascular ultrasound radiofrequency data analysis and optical coherence tomography for detecting thin-cap fibroatheroma. *Eur Heart J.* 2008 ;29:1136-46.
 15. Giroud D, Li JM, Urban P, et al. Relation of the site of acute myocardial infarction to the most severe

- coronary arterial stenosis at prior angiography. *Am J Cardiol* 1992;69:729 –32.
16. Arbustini E, Dal Bello B, Morbini P, et al. Plaque erosion is a major substrate for coronary thrombosis in acute myocardial infarction. *Heart* 1999;82:269–272.
 17. Virmani R, Kolodgie FD, Burke AP, et al. Lessons from sudden coronary death a comprehensive morphological classification scheme for atherosclerotic lesions. *Arterioscler Thromb Vasc Biol* 2000;20:1262–1275.
 18. Claessen BE, Maehara A, Fahy M, et al. Plaque composition by intravascular ultrasound and distal embolization after percutaneous coronary intervention. *JACC Cardiovasc Imaging*. 2012;5:111-8.

Table 1: Baseline clinical characteristics

	Attenuation group (n=15)	Ulceration group (n=24)	Control group (n=82)	p value
Age (yrs)	65 ± 10	64 ± 10	64 ± 11	n.s.
Gender (male/female)	15 / 0	20 / 4	69 / 13	n.s.
Hypertension	8 (53%)	14 (58%)	53 (65%)	n.s.
Diabetes mellitus	8 (53%)	11 (46%)	29 (35%)	n.s.
Hypercholesterolemia	5 (33%)	13 (54%)	45 (55%)	n.s.
Current smokers	10 (67%)	9 (38%)	39 (48%)	n.s.
Acute coronary syndrome	9 (60%)	14 (58%)	42 (51%)	n.s.
Stable angina pectoris	6 (40%)	10 (42%)	40 (49%)	n.s.

Data are expressed as mean ± SD or as number (percentage).

Table 2: Angiographic and procedure characteristics

	Attenuation group (n=15)	Ulceration group (n=24)	Control group (n=82)	p value
Target vessel				
LAD	8 (53%)	12 (50%)	48 (59%)	n.s.
LCx	4 (27%)	7 (29%)	8 (10%)	
RCA	3 (20%)	5 (21%)	25 (30%)	
LMT	0 (0%)	0 (0%)	1 (1%)	
Extent of coronary artery disease				
1	6 (40%)	6 (25%)	35 (43%)	n.s.
2	4 (60%)	13 (54%)	23 (28%)	
3	5 (33%)	5 (21%)	24 (29%)	
ACC/AHA classification				
A / B1	5 (33%)	10 (42%)	35 (43%)	n.s.
B2 / C	10 (67%)	14 (58%)	47 (57%)	

Coronary calcification		4 (27%)	6 (25%)	20 (24%)	n.s.
Quantitative angiography					
Reference vessel diameter (mm)		3.07 ± 0.58	3.41 ± 0.58	3.15 ± 0.51	n.s.* <0.05**
Pre-minimal luminal diameter (mm)		0.56 ± 0.39	0.71 ± 0.43	0.71 ± 0.44	n.s.
Pre-diameter stenosis (%)		82 ± 11	79 ± 12	78 ± 13	n.s.
Post-minimal luminal diameter (mm)		2.95 ± 0.51	3.23 ± 0.52	3.01 ± 0.46	n.s.* <0.05**
Post-diameter stenosis (%)		6 ± 8	4 ± 8	4 ± 11	n.s.

LAD: Left anterior descending coronary artery; LCx: Left circumflex coronary artery, RCA: Right coronary artery; LMT: Left main trunk

* Attenuation group vs. Control group

** Ulceration group vs. Control group

Table 3: Angiographic and procedure characteristics

	Attenuation group (n=15)	Ulceration group (n=24)	Control group (n=82)	p value
Thrombus before PCI	6 (40%)	9 (38%)	26 (32%)	n.s.
Procedure				
Thrombectomy	6 (40%)	5 (21%)	20 (24%)	n.s.
Before dilatation	15 (100%)	24 (100%)	81 (99%)	n.s.
Initial TIMI flow grade 0/1/2	5 (33%)	9 (38%)	33 (40%)	n.s.
Final TIMI flow grade 3	15 (100%)	24 (100%)	81 (99%)	n.s.
Before stenting				
TIMI flow grade 0/1/2	2 (13%)	1 (4%)	6 (7%)	n.s.
CTFC	24.5 ± 4.9	24.0 ± 6.3	24.3 ± 8.7	n.s.
After stenting				
TIMI flow grade 0/1/2	4 (27%)	5 (21%)	10 (12%)	n.s.

CTFC	27.1 ± 4.8	28.0 ± 8.1	24.5 ± 9.7	n.s.
The incidence of slow flow/no reflow after stenting	3 (20.0%)	5 (20.8%)	4 (4.9%)	<0.05* <0.05**

PCI: percutaneous coronary intervention

TIMI flow: Thrombolysis In Myocardial infarction

CTFC: corrected Thrombolysis In Myocardial infarction frame count

* Attenuation group vs. Control group

** Ulceration group vs. Control group

Table 4: Gray-scale and virtual histology intravascular ultrasound findings

	Attenuation group (n=15)	Ulceration group (n=24)	Control group (n=82)	p value
Grayscale IVUS characteristics				
Lumen CSA (mm ²)	5.0 ± 1.3	7.6 ± 3.0	4.7 ± 1.4	n.s.* <0.01**
EEM CSA (mm ²)	17.1 ± 3.5	19.7 ± 4.9	16.0 ± 4.5	n.s.* <0.01**
Plaque and Media CSA (mm ²)	12.1 ± 3.9	12.0 ± 3.2	11.4 ± 3.6	n.s.* n.s.**
VH-IVUS characteristics				
Fibrous (%)	55.7 ± 9.5	56.9 ± 10.0	61.7 ± 9.9	<0.05* <0.05**
Fibro-fatty (%)	27.5 ± 9.5	10.4 ± 5.8	13.9 ± 8.2	<0.01* <0.05**
Necrotic core (%)	12.2 ± 6.1	20.7 ± 9.0	15.9 ± 9.0	n.s.* <0.05**
Dense calcium (%)	4.6 ± 3.0	12.3 ± 6.4	8.3 ± 7.1	n.s.* <0.05**

Fibrous (mm ²)	6.8 ± 2.6	6.8 ± 2.2	7.1 ± 2.8	n.s.* n.s.**
Fibro-fatty (mm ²)	3.5 ± 1.9	1.2 ± 0.7	1.6 ± 1.2	<0.01* n.s.**
Necrotic core (mm ²)	1.3 ± 0.4	2.5 ± 1.3	1.7 ± 1.0	n.s.* <0.01**
Dense calcium (mm ²)	0.5 ± 0.4	1.4 ± 0.7	0.9 ± 0.8	n.s.* <0.01**

CSA: cross-sectional area, EEM: external elastic membrane

* Attenuation group vs. Control group

** Ulceration group vs. Control group

Table 5: Comparison of virtual histology intravascular ultrasound findings between ACS and SAP in the attenuation group and the ulceration group

1) The attenuation group

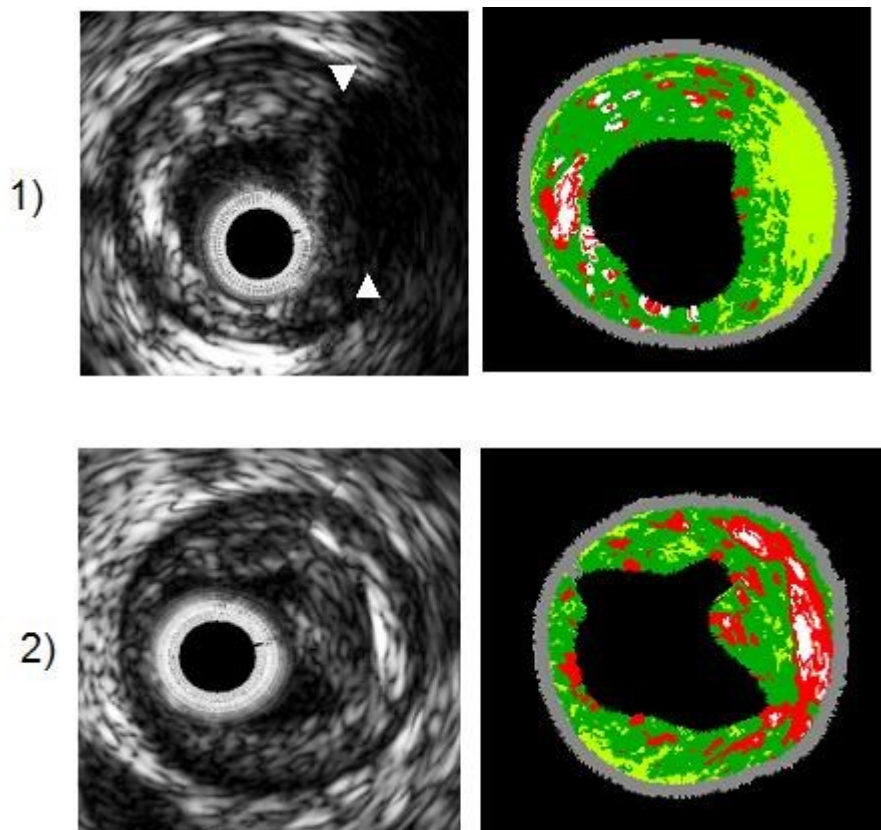
	Attenuation group		p value
	ACS (n=9)	SAP (n=6)	
Fibrous (%)	55.6 ± 8.4	56.0 ± 11.9	n.s.
Fibro-fatty (%)	28.4 ± 7.9	26.2 ± 12.2	n.s.
Necrotic core (%)	11.3 ± 6.0	13.5 ± 6.5	n.s.
Dense calcium (%)	4.9 ± 3.9	4.2 ± 1.0	n.s.
Fibrous (mm ²)	7.5 ± 2.5	5.7 ± 2.4	n.s.
Fibro-fatty (mm ²)	4.0 ± 2.0	2.8 ± 1.7	n.s.
Necrotic core (mm ²)	1.4 ± 0.5	1.2 ± 0.4	n.s.
Dense calcium (mm ²)	0.6 ± 0.5	0.4 ± 0.1	n.s.

2) The ulceration group

	Ulceration group		p value
	ACS (n=14)	SAP (n=10)	
Fibrous (%)	54.6 ± 9.7	60.0 ± 9.9	n.s.
Fibro-fatty (%)	10.3 ± 6.5	10.5 ± 4.9	n.s.
Necrotic core (%)	23.1 ± 9.9	17.2 ± 6.7	n.s.
Dense calcium (%)	12.1 ± 6.4	12.5 ± 6.8	n.s.
Fibrous (mm ²)	7.0 ± 1.9	6.5 ± 2.5	n.s.

Fibro-fatty (mm ²)	1.3 ± 0.8	1.1 ± 0.6	n.s.
Necrotic core (mm ²)	3.0 ± 1.4	1.8 ± 1.0	<0.01
Dense calcium (mm ²)	1.5 ± 0.8	1.3 ± 0.6	n.s.

Figure 1: Grayscale and virtual histology intravascular ultrasound image of the attenuated plaque and the ulcerated plaque



1) The Attenuated plaque; Attenuated plaque showed echo attenuation (white arrow) behind coronary atheroma without significant calcification in grayscale IVUS. The attenuated plaque contained more fibro-fatty tissue in VH-IVUS.

2) The Ulcerated plaque; The ulcerated plaque contained more necrotic core and dense calcium in VH-IVUS.

