

# 東邦大学学術リポジトリ

Toho University Academic Repository

タイトル	A Case of Dural Arteriovenous Fistula in a Patient Presenting with Objective Tinnitus
作成者（著者）	Kentaro, Matsuura / Kota, Wada / Yuko, Sasaki / Koji, Matsushima / Hisako, Shiono / Hitoshi, Ozawa / Hideo, Edamatsu
公開者	The Medical Society of Toho University
発行日	2015.12
ISSN	21891990
掲載情報	Toho Journal of Medicine. 1(4). p.69 72.
資料種別	学術雑誌論文
内容記述	Case Report
著者版フラグ	publisher
JaLCDOI	info:doi/10.14994/tohojmed.2015.006
メタデータのURL	<a href="https://mylibrary.toho u.ac.jp/webopac/TD67694352">https://mylibrary.toho u.ac.jp/webopac/TD67694352</a>

**Case Report****A Case of Dural Arteriovenous Fistula in a Patient Presenting with Objective Tinnitus**

Kentaro Matsuura<sup>1)</sup> Kota Wada<sup>1)\*</sup> Yuko Sasaki<sup>1)</sup>  
 Koji Matsushima<sup>1)</sup> Hisako Shiono<sup>2)</sup> Hitoshi Ozawa<sup>3)</sup>  
 and Hideo Edamatsu<sup>1)</sup>

<sup>1)</sup>Department of Otolaryngology (Omori), School of Medicine, Faculty of Medicine, Toho University

<sup>2)</sup>Department of Otolaryngology, Ushioda General Hospital

<sup>3)</sup>Department of Neurosurgery, Ushioda General Hospital

---

**ABSTRACT:** A 42-year-old woman presented with a chief complaint of worsening tinnitus in the left ear. The tinnitus was very low in volume, and audiometry and tympanometry findings were normal. One month later, her condition had worsened to the extent that a stethoscope placed at the temporal region or entrance of the external auditory meatus revealed objective pulsatile tinnitus, indicating vascular murmur. Findings from magnetic resonance imaging suggested intracranial vascular lesions. Dural arteriovenous fistula was diagnosed on the basis of angiography findings. Tinnitus resolved after arterial embolization. At present, there are no signs of recurrence or postoperative complications. The present findings indicate that vascular murmur should be diagnosed and treated with caution.

**Toho J Med 1 (4): 69–72, 2015**

---

**KEYWORDS:** dural arteriovenous fistula, objective tinnitus, pulsatile tinnitus

Fowler classified tinnitus as nonvibratory and vibratory.<sup>1)</sup> Nonvibratory tinnitus is perceived only by the patient and occurs without acoustic stimulation. Vibratory tinnitus can be detected by a physician/audiologist and is attributable to physical sound stimuli. Vibratory tinnitus perceivable by another person is called objective tinnitus, the cause of which is classified as muscular, vascular, and other, in descending order of incidence.<sup>2)</sup>

The cause of muscular tinnitus is intermittent sound that initiates a spasm of, for example, the tympanic muscle, stapedius muscle, tensor veli palatini muscle, or levator veli palatini muscle.<sup>3)</sup> The sound sources are the tympanum, eustachian tube, and soft palate. Muscular tinnitus is often associated with mechanical vibrations at higher fre-

quencies than those seen in vascular tinnitus. Movement disorders synchronous with tinnitus, such as palatal myoclonus, are observed in the soft palate and tympanic membrane.

The causes of vascular tinnitus include changes in systemic hemodynamics caused by anemia, thyroid dysfunction, pheochromocytoma, pregnancy, shunt-induced changes in the inner diameter of blood vessels (*e.g.*, arteriovenous malformation and arteriovenous fistula), arteriosclerosis, aneurysm, and local disorders such as malpositioning in the venous system.<sup>4)</sup>

The causes of “other” objective tinnitus include intratympanic tumors (*e.g.*, glomus tumor), intracranial tumors (*e.g.*, meningioma),<sup>5)</sup> and sarcoidosis.<sup>6)</sup> Here we report

---

1) 6-11-1 Omorinishi, Ota, Tokyo 143-8541, Japan  
 2, 3) 1-6-20 Yakou, Tsurumi, Yokohama, 230-0001, Japan  
 \*Corresponding Author: tel: +81-(0)3-3762-4151  
 e-mail: wadakota@med.toho-u.ac.jp

DOI: 10.14994/tohojmed.2015.006  
 Received May 11, 2015; Accepted Sept. 6, 2015  
 Toho Journal of Medicine 1 (4), Dec. 1, 2015.  
 ISSN 2189-1990, CODEN: TJMOA2

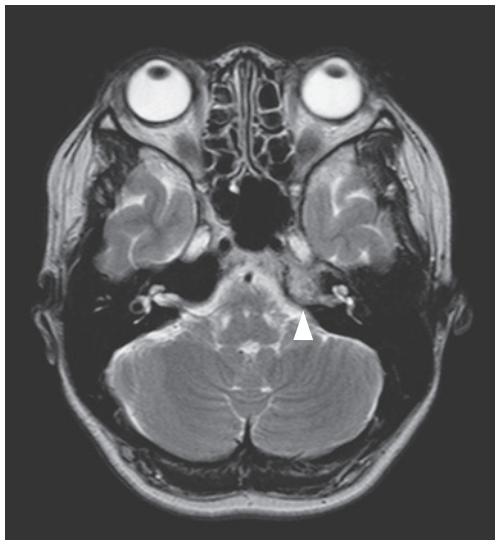


Fig. 1 T2-weighted MR image

A T2-weighted magnetic resonance (MR) image shows a lesion with mildly high signal intensity (arrowhead) along the auditory nerve, at the apex of the petrous bone.

a case of dural arteriovenous fistula in a patient with objective tinnitus.

### Case Presentation

A 42-year-old woman presented with sudden onset of left tinnitus, in early June 2014. She sought treatment because her condition was gradually worsening. She described the tinnitus as rushing sounds, which worsened at night but did not affect sleep. She had no hearing loss, sense of ear fullness, or vertigo. Her previous medical history was unremarkable, and she did not report trauma. Her blood pressure was 102/57 mmHg on both the right and left sides. Her pulse was 72 beats/min and regular. There were no abnormal findings in the ears, nose, or throat. Blood testing revealed no abnormalities. The results of pure-tone audiometry were normal: 18.3 dB for the right ear and 15 dB for the left ear (the average of 6 frequencies). Tympanometry was type A on both sides. Because her tinnitus was relatively mild, we suggested a wait-and-see approach. Approximately 1 month later, she returned complaining that her tinnitus was clearly pulsatile and so loud that others could hear it by pressing their ears to hers. Otoscopy failed to detect tinnitus; thus, a magnetic resonance imaging (MRI) was performed. T2-weighted MR images revealed a lesion with mixed intensity. A mildly high signal intensity was present along the auditory nerve, at the apex of the petrous bone (Fig. 1).

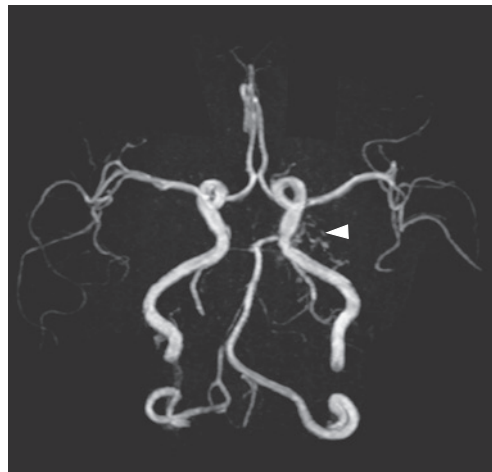


Fig. 2 Magnetic resonance angiography (MRA)  
A MRA image shows structures resembling blood vessels (arrowhead) at a site slightly outward from the cavernous sinus, near the left internal carotid artery.

MR angiography (MRA) revealed structures resembling blood vessels at a site slightly deviated from the cavernous sinus, near the left internal carotid artery (Fig. 2). These findings suggested vascular lesions, *e.g.*, arteriovenous fistula. When the patient was reexamined in our department and the neurology department, auscultation with a stethoscope revealed an intermittent buzzing sound synchronous with the pulse, at the entrance of the external auditory meatus and within the temporal region. Moreover, her tinnitus was relieved by compression of the cervical blood vessels and recurred after compression was released. A vascular lesion was suspected, and she was referred to the neurosurgery department, where angiography was performed. Imaging of the left external carotid artery and maxillary artery revealed abnormal proliferation of blood vessels, into which blood flowed strongly from several arteries, including the middle meningeal artery (Fig. 3A). Because the veins were enhanced, even during the early arterial phase (Fig. 3B), epidural arteriovenous fistula was diagnosed. Although the patient's only symptom was tinnitus, endovascular embolization (coiling) of the feeding arteries was performed at her request. Blood flow into the abnormal blood vessels disappeared after the branches from the middle meningeal, maxillary, and ascending pharyngeal arteries to the arteriovenous fistula were embolized with platinum coils (Fig. 4). The tinnitus disappeared after surgery, and no complications or other symptoms have been observed postopera-

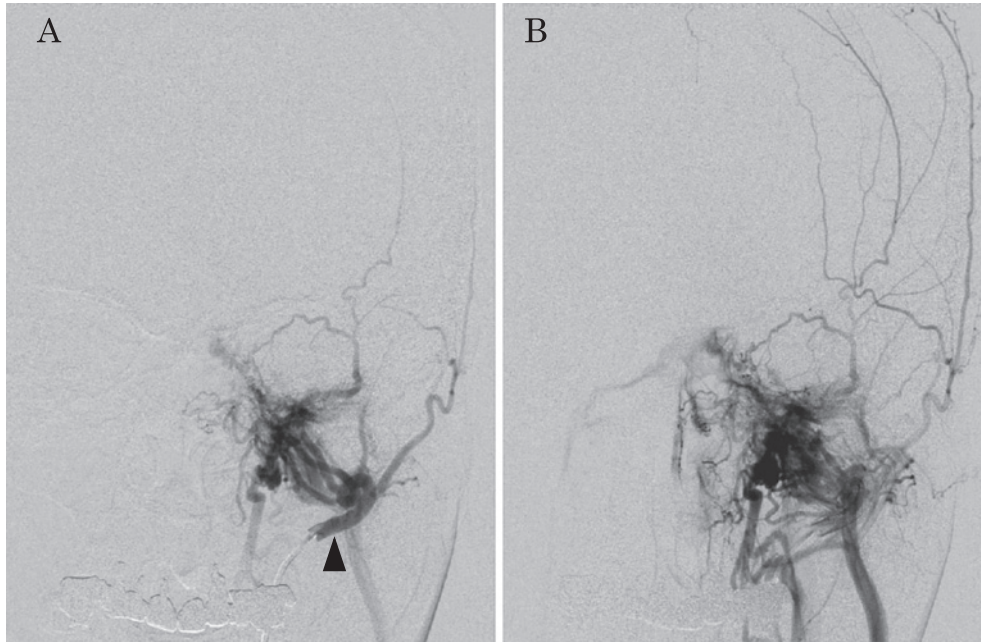


Fig. 3 Angiogram of the left external carotid artery

A. An angiogram of the left external carotid artery and maxillary artery (arrowhead) shows abnormal proliferation of blood vessels, into which blood flow from the middle meningeal artery is strong.

B. The veins are enhanced during the early arterial phase.

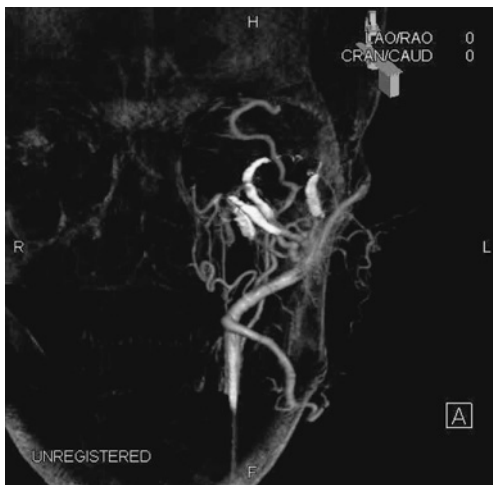

Fig. 4 Three-dimensional angiogram

A 3-dimensional angiogram was obtained after coiling. The branches from the middle meningeal, maxillary, and ascending pharyngeal arteries to the arteriovenous fistula were embolized with platinum coils (white sections of vessels).

tively.

## Discussion

We treated a patient with dural arteriovenous fistula whose chief complaint was objective tinnitus, which can be treated effectively by surgery. In the present case, minimally invasive endovascular therapy was successful.

Tinnitus is an extremely common auditory complaint. Otolaryngologists encounter many patients with subjective tinnitus; however, few have objective tinnitus. Objective tinnitus is classified as muscular, vascular, and "other".<sup>2)</sup> Sila et al reported that tinnitus was objectively confirmed in approximately 70% of cases of vascular tinnitus.<sup>7)</sup> Because the incidence of objective tinnitus is low, it is sometimes misdiagnosed as subjective tinnitus. Thus, a complaint of pulsatile tinnitus might mask a serious disorder. Because a complete cure can be achieved by treatment in some cases, a detailed medical history and examination are necessary. While obtaining a patient history, clinicians should focus on the presence or absence of continuous tinnitus, time of onset, site of onset, exacerbating factors, relieving factors, hearing loss, sense of ear fullness, presence or absence of vertigo, and past history of trauma. Moreover, risk factors for arteriosclerosis, such as hypertension, hyperlipidemia, diabetes mellitus, smoking his-

tory, cerebrovascular disorder, and previous myocardial infarction, are important in diagnosing vascular tinnitus.

In our patient, tinnitus was objectively inaudible with an otoscope but was heard with a stethoscope. Therefore, when a patient complains of objective or pulsatile tinnitus, the ears should be examined with both an otoscope and stethoscope. Moreover, our patient reported that her tinnitus was audible to another person whose ear was pressed to the patient's ear. When the authors repeated this test, tinnitus was indeed audible. If objectively audible tinnitus is synchronous with the pulse, it is most likely vascular tinnitus. In such cases, the head, neck, and chest should be auscultated with a stethoscope. Furthermore, if tinnitus resolves or subsides after compression of the cervical blood vessels, then intracranial vascular abnormalities such as arteriovenous malformation and fistula should be suspected. Angiography should be performed when a vascular lesion, such as dural arteriovenous fistula, is suspected during imaging procedures, *e.g.*, ultrasonography, MRI, or MRA (as in our case).

While there are various causes for pulsatile tinnitus, the reported incidence varies. One study found that 45% of pulsatile tinnitus was attributable to intracranial hypertension.<sup>8)</sup> Moreover, arteriovenous fistula is reported to be the most common cause of pulsatile tinnitus.<sup>9,10)</sup> Dural arteriovenous fistula is responsible for approximately 2% to 20% of pulsatile tinnitus.<sup>9,11)</sup> Although the cause of dural arteriovenous fistula is often occlusion of the venous sinus due to trauma, dehydration, infection, or use of oral contraceptives, many cases are idiopathic. The common sites of dural arteriovenous fistula are the transverse/sigmoid venous sinus and cavernous sinus, which account for 24.7% to 63% and 12% to 25.8% of cases, respectively.<sup>12)</sup> Progression of dural arteriovenous fistula may cause vascular rupture, resulting in cerebral hemorrhage. As described above, in many cases the only initial symptom is pulsatile tinnitus. Thus, when pulsatile tinnitus is observed, we recommend that clinical examinations and tests for disorders such as dural arteriovenous fistula be performed.

Treatments for dural arteriovenous fistula include (1) endovascular therapy, (2) radiotherapy, and (3) surgical therapy.<sup>13,14)</sup> At present, owing to technical advances, minimally invasive endovascular therapy is indicated for many patients and results in positive outcomes. In our case, endovascular therapy was selected, and postoperative recov-

ery has been satisfactory. At this writing, the patient is free from symptoms.

## Conclusion

We described a case of objective tinnitus caused by dural arteriovenous fistula. Progression of dural arteriovenous fistula can cause cerebral hemorrhage, which is potentially life-threatening. However, in many cases the only initial symptom is pulsatile tinnitus. Thus, when pulsatile tinnitus is observed we recommend that clinicians obtain a detailed history and perform examinations including auscultation with an otoscope or stethoscope, MRI, and detailed testing.

## References

- 1) Fowler EP, Fowler EP Jr. An explanation of certain types of tinnitus and deafness. *Laryngoscope*. 1950; 60: 919-30.
- 2) Chan Y. Tinnitus: etiology, classification, characteristics, and treatment. *Discov Med*. 2009; 8: 133-6.
- 3) Ellenstein A, Yusuf N, Hallett M. Middle ear myoclonus: two informative cases and a systematic discussion of myogenic tinnitus. *Tremor Other Hyperkinet Mov (NY)*. 2013; 3: tre-03-103-3713-1.
- 4) Sismanis A. Pulsatile tinnitus: contemporary assessment and management. *Curr Opin Otolaryngol Head Neck Surg*. 2011; 19: 348-57.
- 5) Crummer RW, Hassan GA. Diagnostic approach to tinnitus. *Am Fam Physician*. 2004; 69: 120-6.
- 6) Özdoğan A, Acioglu E, Karaman E, Öz B, Müsellim B. A difficult case: sarcoidosis of the middle ear. *Am J Otolaryngol*. 2009; 30: 281-4.
- 7) Sila CA, Furlan AJ, Little JR. Pulsatile tinnitus. *Stroke*. 1987; 18: 252-6.
- 8) Sismanis A. Pulsatile tinnitus. A 15-year experience. *Am J Otol*. 1998; 19: 472-7.
- 9) Waldvogel D, Mattle HP, Sturzenegger M, Schroth G. Pulsatile tinnitus: a review of 84 patients. *J Neurol*. 1998; 245: 137-42.
- 10) Dietz RR, Davis WL, Harnsberger HR, Jacobs JM, Blatter DD. MR imaging and MR angiography in the evaluation of pulsatile tinnitus. *AJNR Am J Neuroradiol*. 1994; 15: 879-89.
- 11) Sonmez G, Basekim CC, Ozturk E, Gungor A, Kizilkaya E. Imaging of pulsatile tinnitus: a review of 74 patients. *Clin Imaging*. 2007; 31: 102-8.
- 12) Kim S, Byun J, Park M, Lee S. Pulsatile tinnitus with a dural arterio-venous fistula diagnosed by computed tomography-angiography. *Korean J Audiol*. 2013; 17: 133-7.
- 13) Radvany MG, Gregg L. Endovascular treatment of cranial arteriovenous malformations and dural arteriovenous fistulas. *Neurosurg Clin N Am*. 2012; 23: 123-31.
- 14) Kobayashi A, Al-Shahi Salman R. Prognosis and treatment of intracranial dural arteriovenous fistulae: a systematic review and meta-analysis. *Int J Stroke*. 2014; 9: 670-7.