

東邦大学学術リポジトリ



OPAC

東邦大学メディアセンター

タイトル	Effect of skip lymphovascular invasion on hepatic metastasis in colorectal carcinomas
別タイトル	大腸癌肝転移における非連続性脈管侵襲の影響
作成者（著者）	岡本, 陽祐
公開者	東邦大学
発行日	2016.03
掲載情報	東邦大学大学院医学研究科 博士論文. 64.
資料種別	学位論文
内容記述	主査：澁谷和俊 / タイトル：Effect of skip lymphovascular invasion on hepatic metastasis in colorectal carcinomas / 著者：Yosuke Okamoto, Hiroyuki Mitomi, Kazuhito Ichikawa, Shigeki Tomita, Takahiro Fujimori, Yoshinori Igarashi, Study Group for Depth of Tumor Invasion projected by the Japanese Society for Cancer of the Colon and Rectum (JSCCR) / 掲載誌：International Journal of Clinical Oncology / 巻号・発行年等：20(4):761-766, 2015 / 本文ファイル: 査読後原稿 / この論文ファイルに記載されている論題は、雑誌に掲載された論題と異なっておりますが、著者最終稿に記載されている通りのものです。 / The original publication is available at www.springerlink.com/
著者版フラグ	ETD
報告番号	32661甲第787号
学位授与年月日	2016.3.29
学位授与機関	東邦大学
DOI	info:doi/10.1007/s10147-014-0778-z
その他資源識別子	http://link.springer.com/article/10.1007%2Fs10147-014-0778-z
メタデータのURL	https://mylibrary.toho-u.ac.jp/webopac/TD43214393

Original article

Impact of skip lymphovascular invasion on hepatic metastasis in colorectal carcinomas

Yosuke Okamoto ¹, Hiroyuki Mitomi ², Kazuhito Ichikawa ^{3,5}, Shigeki Tomita ⁴, Takahiro Fujimori ⁵, Yoshinori Igarashi ¹ and Study Group for Depth of Tumor Invasion projected by the Japanese Society for Cancer of the Colon and Rectum (JSCCR)

1. Division of Gastroenterology and Hepatology, Department of Internal Medicine, Toho University Omori Medical Center, 6 - 11 - 1, Omorinishi, Ota-ku, Tokyo 143 - 8541, Japan.
2. Department of Surgical and Molecular Pathology, Dokkyo Medical University School of Medicine, 880 Kitakobayashi, Mibu, Shimotsuga, Tochigi 321 - 0293, Japan.
3. Regional Medical Support Center, Fukushima Medical University, 1 Hikarigaoka, Fukushima-shi, Fukushima 960-1295, Japan.
4. Department of Pathology, Juntendo University Urayasu Hospital, 2 - 1 - 1 Tomioka, Urayasu, Chiba 279 - 0021, Japan.
5. Department of Pathology, Shinko Hospital, 1-4-47 Wakihama-cho, Chuo-ku, Kobe, Hyogo 651 - 0072, Japan.

Corresponding author: Hiroyuki Mitomi, M.D., Ph.D

Department of Surgical and Molecular Pathology, Dokkyo Medical University School of Medicine, 880 Kitakobayashi, Mibu, Shimotsuga, Tochigi 321 - 0293, Japan.

Phone: 81-282-87-2130; Fax: 81-282-86-1681; E-mail: hmitomi@dokkyomed.ac.jp

ABSTRACT

Background: “Skip” lymphovascular invasion presenting as discontinuous foci of tumor cells within a colonic wall is now excluded from consideration in determining the T stage in the TNM classification. The aim of this study was to assess the clinicopathological characteristics of colorectal cancer (CRC) patients featuring such skip lymphovascular invasion.

Methods: First, a retrospective questionnaire survey for the incidence of skip lymphovascular invasion was performed for a total of 1,868 patients with CRCs at 10 institutions. Next, we comparatively assessed clinicopathological data of 896 CRC patients with or without skip lymphovascular invasion.

Results: The incidence of skip lymphovascular invasion was 1.1 % (20 out of 1,868), the majority of affected cases being rectal, pT2 and node negative, with moderately differentiated histology. Skip lymphovascular invasion was present in the muscularis propria and subserosa, with the tumors directly invading into submucosa (pT1) or muscularis propria (pT2). Hepatic metastasis was higher in CRC with skip lymphovascular invasion (25%) than in pT1/2 CRC (0%; $P < 0.001$) or pT3 CRC without such invasion (13.8%; $P = 0.185$).

Conclusions: Our study suggests that skip lymphovascular invasion is associated with hepatic metastasis in CRC cases. Thus, definition of a T category including such invasion would be useful for clinical practice.

Key words: skip metastasis, lymphovascular invasion, colon carcinoma, liver metastasis

INTRODUCTION

Colorectal cancer (CRC) is the fourth most common cancer in men and the third most common cancer in women worldwide. High CRC rates are observed in the Asian registries of Japan and Singapore [1]. CRC is a major cause of mortality in Japan, where it accounts for the largest number of deaths from malignant neoplasms in women and the third largest number in men; outcomes remain poor in Japanese CRC patients with advanced stage, with cumulative 5-year survival rates of 63.7% for stage III and 13.2 for stage IV [2].

Considerable ongoing interest is being paid to predictive factors for survival such as the TNM stage. The TNM classification, the most widely used means for classifying the extent of CRC spread, is based on the size and/or extent (reach) of the primary tumor (T stage), the amount of involvement of nearby lymph nodes (N stage), and the presence of metastasis or secondary tumors formed by dissemination of cancer cells to other parts of the body (M stage) [3]. In addition to the TNM staging, lymphatic vessel invasion [4, 5], venous invasion [6-8], extranodal cancer deposits [9, 10] and perineural invasion [11, 12] are also important pathologic prognostic indicators. Distinction of venous invasion from lymphatic vessel invasion on conventional hematoxylin and eosin (H&E) - stained sections is often difficult and the assessment of these two elements has thus been incorporated under a single heading entitled lymphovascular invasion [13]. Thus prognostic significance of lymphovascular (combined lymphatic and blood vessels) invasion has been shown in CRC [14].

“Skip” lymphovascular invasion features discontinuous foci of tumor cells within a colonic wall and this type of invasion is excluded from consideration in determining T stage based in the 7th edition of the TNM classification [3]. However, it is still unclear whether skip lymphovascular invasion should be categorized into T staging or excluded from consideration in determining tumor stage because few studies have focused on the

significance of skip lymphovascular invasion in CRC. Therefore, the present multicenter study on skip lymphovascular invasion in CRC was conducted by the Depth of Tumor Invasion Working Group of the Japanese Society for Cancer of the Colon and Rectum (JSCCR).

The aim of the present study is therefore to assess the incidence and clinicopathological characteristics of CRC patients with skip lymphovascular invasion, providing useful prognostic information to optimize the TNM classification.

MATERIALS AND METHODS

Patients and materials

First, we performed a retrospective questionnaire survey for the incidence of CRC with skip lymphovascular invasion and obtained this information from a total of 1,868 patients with pT1 - 4 CRCs, who consecutively underwent curative surgery in 2005 and 2011 at 10 JSCCR institutions (National Defense Medical College, Dokkyo Medical University School of Medicine, Niigata University Graduate School of Medical and Dental Sciences, Tokyo Medical and Dental University, Teikyo University School of Medicine, Kinki University, Hiroshima University, Tokyo Metropolitan Geriatric Hospital, Watari Hospital, and Juntendo University School of Medicine).

Next, we comparatively investigated clinicopathological data of patients with or without skip lymphovascular invasion in 896 of 1,868 CRC patients, with an average follow-up period to be 45.4 months (range, 1 - 81 months) for 326 survivors. Clinicopathological characteristics of 896 CRC patients with or without skip lymphovascular invasion are shown in Table 1. Ethics approval for this study was obtained from the JSCCR.

Histological evaluation of skip lymphovascular invasion

Tumor blocks stained with H&E were evaluated for skip lymphovascular invasion, defined as well-defined tumor emboli within an endothelial lined space of lymphatic or blood vessels, discontinuously present in deeper layers separate from invasive tumor fronts. Identification of lymphovascular invasion was enhanced by the 'orphan artery sign,' defined as a well-circumscribed tumor nodule adjacent to a muscularized artery [8]. If necessary, an elastin stain was used to facilitate detection of lymphovascular invasion. The schema and representative histology of skip lymphovascular invasion are shown in Figs. 1 and 2, respectively.

Statistical analysis

All statistical analyses were performed using R software version 3.0.0 for Windows. Categorical analysis of variables was performed using either the Chi-squared test (with Yates' correction) or the Fisher's exact test, as appropriate. For continuous variables, two-group comparisons were performed Mann-Whitney *U* - test. A *P* value less than 0.05 was considered significant.

RESULTS

Clinicopathological characteristics of CRC patients with skip lymphovascular invasion

The overall incidence of CRC with skip lymphovascular invasion in the 2005 and the 2011 cohorts was 1.1 % (20 out of 1,868 cases); the values were 1.7 % (16 of 926 cases) in the 2005 cohort and 0.4 % (4 of 942 cases) in the 2011 cohort.

Table 2 shows clinicopathological details of CRC with skip lymphovascular invasion. The majority of patients were older than 60 years (15 of 20 cases, 75%) and male (13 of 20

cases, 65%), with a mean tumor diameter of 25.6 mm (range, 9 - 50mm). The majority of tumors were rectal (11 of 20 cases, 55%), moderately differentiated (12 of 20 cases, 60%), pT2 (17 of 20 cases, 85%) and node negative (17 of 20 cases, 85%). Skip lymphovascular invasion was present in the muscularis propria in 2 of 20 cases (10%), both directly invading the submucosa (pT2), and was also existed in the subserosa in 18 of 20 cases (90%), 1 of these 18 directly invaded the submucosa (pT1) and the remaining 17 lesions invaded the muscularis propria (pT2). Hepatic metastasis was found in 4 of the 20 cases (20%) at surgery and recurrent hepatic metastasis was also found in 1 (5%). One patient (Case #3 in Table 2; Fig. 2) with lymph node metastasis had recurrence as additionally observed in the liver and lung, and died of cancer 22 months after surgery.

Comparison of clinicopathological variables in CRC patients with skip lymphovascular invasion and pT1/2 CRC patients without skip lymphovascular invasion

Among the total study group, 210 cases (128 males and 82 females, mean age 67 years) of pT1 and pT2 CRC without skip lymphovascular invasion were extracted for comparative analysis with the 20 CRCs featuring skip lymphovascular invasion.

Lymphovascular invasion and hepatic metastasis were significantly higher in CRCs with skip lymphovascular invasion than in pT1 and pT2 CRCs without ($P < 0.001$). There were however no significant differences between the two groups in terms of age, gender, size of tumor, location, histological type, lymph node metastasis and distant metastasis (Table 3). In addition, 62 out of 448 (13.8%) pT3 CRC without skip lymphovascular invasion had hepatic metastasis: the value was lower than that of CRC with skip lymphovascular invasion (5 of 20 cases, 25%; $P = 0.185$).

DISCUSSION

In the present multicenter survey, the incidence of CRCs with skip lymphovascular invasion was 1.1 % (20 of 1,868 cases). Skip lymphovascular invasion was present in the muscularis propria and subserosa, with the tumors directly invading into submucosa (pT1) or the muscularis propria (pT2), respectively. Hepatic metastasis was significantly higher in CRCs with skip lymphovascular invasion than in pT1 and pT2 CRCs without skip lymphovascular invasion. Furthermore, the value of CRCs with this type of invasion was higher than that of pT3 CRC without such invasion (25% *vs.* 13.8%). Thus, the depth of skip lymphovascular invasion may be regarded as a factor for T staging in the process of classification using the TNM staging manual with regard to hepatic metastasis.

Substantial interobserver variability has been reported in the diagnosis of lymphatic or venous invasion on the basis of H&E stained slides, but variability was not improved by the use of immunohistochemical staining for CD31 and D2-40 [15]. In daily practice, distinction of venous from lymphatic invasion is usually applied only with H&E - stained sections in the institutions affiliated with the Depth of Tumor Invasion Working Group in the JSCCR. The College of American Pathologists' consensus statement did not recommend the use of any special stains or immunohistochemistry to diagnose lymphatic or venous invasion [16]. Consequently, in the present study the assessment of these two elements was incorporated under a single heading entitled skip lymphovascular invasion.

Venous invasion is known to be associated with hepatic metastasis [6, 7]. Logistic regression multivariate analysis showed vascular invasion and tumor location to be the only statistically significant predictors of hepatic metastasis [7]. Multivariate analysis also identified lymphatic vessel invasion as an independent prognostic factor for survival in CRC cases [4, 5]. In an analysis of a large cohort (approximately 2,400 CRC patients), presence of lymphovascular invasion was an independent unfavorable prognostic factor for 5-year survival of CRC patients (81% and 53%, respectively, with and without

lymphovascular invasion) [14]. The combination of T stage and vascular invasion had predictive value for survival; 5-year values for node negative / positive T4 diseases were 69% / 40%; as compared to 91% / 71% without vascular invasion [8]. This suggests that the combination system might improve prediction of survival in CRC cases. Ueno et al. demonstrated that the prognostic impact of tumor nodules without residual lymph node structure, as extramural discontinuous cancer spread (extranodal cancer deposits), was independent of lymph node metastasis and venous invasion [9]. In their study, vascular invasion-type of extranodal cancer deposit was recommended as a T factor in the TNM staging, in line with our study.

Adjuvant chemotherapy is generally applied for stage III CRC as it has proven to reduce the rate of tumor recurrence, to increase survival and to be cost-effective in this patient group [17]. However, convincing evidence of survival benefit is lacking for stages I and II [18], and discussions depend on identification of risk factors in addition to TNM staging [5]. In the current study, 14 of 20 (70%) CRCs with skip lymphovascular invasion were stage I. Furthermore, we paid particular attention to a case of stage III CRC showing recurrence as liver and lung metastasis and cancer-related death at 22 months after surgery. Adjuvant chemotherapy should be considered in selected high risk subgroups such as CRC with skip lymphovascular invasion.

In patients with T1 CRC, endoscopic resection of the tumor is an attractive option compared with surgical resection. Endoscopic submucosal dissection allows en bloc resection of T1 tumors [18]. We found that 3 of 99 (3%) pT1 CRC had skip lymphovascular invasion in the 2005 cohort, all featuring deep involvement of the submucosa coexisting with skip invasion in the muscularis propria (1 case) or the subserosa (2 cases). If these patients had undergone endoscopic resection, residual foci of skip lymphovascular invasion located in the muscularis propria or the subserosa would have remained a problem. Since risk of lymph node metastasis is very low in minimally invasive T1 CRC [19, 20], the JSCCR

Guideline 2010 for the Treatment of CRC proposed that minimally, but not deeply invasive T1 tumor with the size of < 20mm can be endoscopically resected [2].

In conclusion, our study suggests that skip lymphovascular invasion is associated with hepatic metastasis in patients with CRC and adjuvant chemotherapy may be considered in this high risk subgroup. Thus, T category including this type of invasion would appear useful for clinical practice in risk prediction of hepatic metastasis in CRC cases.

ACKNOWLEDGEMENTS

For kindly supplying the data the authors greatly thank: Hideki Ueno, Department of Surgery, National Defense Medical College; Gen Watanabe, Division of Molecular and Diagnostic Pathology, Niigata University Graduate School of Medical and Dental Sciences; Tetsuro Higuchi, Department of Digestive Surgery, Graduate School, Tokyo Medical and Dental University; Keiji Matsuda, Department of Surgery, Teikyo University; Hiroshi Kashida, Department of Gastroenterology and Hepatology, Kinki University; Shiro Oka, Department of Endoscopy, Hiroshima University Hospital; Tomio Arai, Department of Pathology, Tokyo Metropolitan Geriatric Hospital; Masamitsu Unakami, Department of Pathology, Watari Hospital; Ryo Wada, Department of Pathology, Juntendo Shizuoka Hospital, Juntendo University School of Medicine; Hisashi Nakamura, Department of Gastroenterology and Endoscopy, Chofu Surgical Clinic; Akinori Iwashita, Department of Pathology, Fukuoka University; Tomoo Ito, Department of Pathology, Kobe University Graduate School of Medicine; Atsushi Ochiai, Pathology Division, Research Center for Innovative Oncology, National Cancer Center Hospital East; Yasuo Ohkura, Department of Pathology, Kyorin University; Tadayoshi Kakemura, Division of Gastroenterology, Department of Internal Medicine, Toho University Ohashi Medical Center; Hiroshi Kijima,

Department of Pathology and Bioscience, Hirosaki University Graduate School of Medicine; Ryoji Kushima, Division of Molecular and Diagnostic Pathology, Shiga University of Medical Science Hospital; Kazutomo Togashi, Department of Gastroenterology, Fukushima Medical University; Takashi Nishigami, Department of Pathology, Steel Memorial Hirohata Hospital and Tamotsu Sugai, Department of Molecular Diagnostic Pathology, Iwate Medical University School of Medicine.

DISCLOSURE/CONFLICT OF INTEREST

The authors declare no conflict of interest.

REFERENCES

1. Center MM, Jemal A, Smith RA et al (2009) Worldwide variations in colorectal cancer. *CA Cancer J Clin* 59:366-378
2. Watanabe T, Itabashi M, Shimada Y et al (2012) Japanese Society for Cancer of the Colon and Rectum (JSCCR) guidelines 2010 for the treatment of colorectal cancer. *Int J Clin Oncol* 17:1-29
3. Sobin LH, Gospodarowitz MK, Wittekind C (2009) *TNM Classification of Malignant Tumours*, 7th edn. Wiley-Liss, New York
4. Minsky BD, Mies C, Rich TA et al (1989) Lymphatic vessel invasion is an independent prognostic factor for survival in colorectal cancer. *Int J Radiat Oncol Biol Phys* 17:311-318
5. Gertler R, Rosenberg R, Schuster T et al (2009) Defining a high-risk subgroup with colon cancer stages I and II for possible adjuvant therapy. *Eur J Cancer* 45:2992-2999
6. Shirouzu K, Isomoto H, Kakegawa T, et al (1991) A prospective clinicopathologic study of venous invasion in colorectal cancer. *Am J Surg* 162:216-222
7. Mitomi H, Mori A, Kazazawa H, et al (2005) Venous invasion and down regulation of p21^{WAF1/CIP1} are associated with metastasis in colorectal carcinomas. *Hepatogastroenterology* 52:1421-1426
8. Roxburgh CS, McMillan DC, Richards CH, et al (2014) The clinical utility of the combination of T stage and venous invasion to predict survival in patients undergoing surgery for colorectal cancer. *Ann Surg* 259:1156-1165
9. Ueno H, Mochizuki H, Hashiguchi Y, et al (2007) Extramural cancer deposits without nodal structure in colorectal cancer: optimal categorization for prognostic staging. *Am J Clin Pathol* 127:287-294
10. Qiu HB, Chen G, Keshari RP, et al (2011) The extramural metastasis might be

- categorized in lymph node staging for colorectal cancer. *BMC Cancer* 11:414
11. Liebig C, Ayala G, Wilks J, et al (2009) Perineural invasion is an independent predictor of outcome in colorectal cancer. *J Clin Oncol* 27:5131-5137
 12. Ueno H, Shirouzu K, Eishi Y, et al (2013) Characterization of perineural invasion as a component of colorectal cancer staging. *Am J Surg Pathol* 37:1542-1549
 13. Washington MK, Berlin J, Branton P, et al (2009) Protocol for the examination of specimens from patients with primary carcinoma of the colon and rectum. *Arch Pathol Lab Med* 133:1539-1551
 14. Lim SB, Yu CS, Jang SJ, et al (2010) Prognostic significance of lymphovascular invasion in sporadic colorectal cancer. *Dis Colon Rectum* 53:377-384
 15. Harris EI, Lewin DN, Wang HL, et al (2008) Lymphovascular invasion in colorectal cancer: an interobserver variability study. *Am J Surg Pathol* 32:1816-1821
 16. Compton CC, Fielding LP, Burgart LJ, et al (2000) Prognostic factors in colorectal cancer. College of American Pathologists Consensus Statement 1999. *Arch Pathol Lab Med* 124:979-994
 17. Jessup JM, Stewart A, Greene FL, et al (2005) Adjuvant chemotherapy for stage III colon cancer: Implications of race/ethnicity, age, and differentiation. *JAMA* 294:2703-2711
 18. Quasar Collaborative Group (2007) Adjuvant chemotherapy versus observation in patients with colorectal cancer: a randomized study. *Lancet* 370:2020-2029
 19. Tanaka S, Oka S, Chayama K (2008) Colorectal endoscopic submucosal dissection: present status and future perspective, including its differentiation from endoscopic mucosal resection. *J Gastroenterol* 43:641-651
 20. Kitajima K, Fujimori T, Fujii S, et al (2004) Correlations between lymph node metastasis and depth of submucosal invasion in submucosal invasive colorectal carcinoma: a Japanese collaborative study. *J Gastroenterol* 39:534-543

FIGURE LEGENDS

Fig. 1. A schema for skip lymphovascular invasion in CRC, the primary tumor directly invading the muscularis propria (pT2) and skip lymphovascular invasion within the subserosa. M, lamina propria mucosae; SM, submucosa; MP, muscularis propria; SS, subserosa; S, serosa.

Fig. 2. A case of pT1 CRC with skip lymphovascular invasion (Case #3 in Table 3).

- a. Well to moderately differentiated adenocarcinoma invading the submucosa (pT1) (H&E stain, original magnification X1.25).
- b. Skip lymphovascular invasion discontinuously existing in the subserosa distant from the invasive front of a primary tumor (H&E stain, original magnification X1.25).
- c. The magnifying view of the box in Fig. 2b. Cancer emboli in lymphatic vessels or small-sized veins in the subserosa (H&E stain, original magnification X20).

Table 1. Clinicopathological data of 896 patients with CRC

Age [years] (range)	66.9 (19 - 98)
Gender	
Male	542
Female	354
Size [mm] (range)	45.3 (7 - 220)
Location	
Right colon	231
Left colon	297
Rectum	360
ND	8
Differentiation	
Well	376
Moderate	465
Poor	20
Others	33
ND	2
Depth of tumor invasion	
pTis	41
pT1	117
pT2	116
pT3	450
pT4	172
Lymphovascular invasion	
Positive	736
Negative	160
Lymph node metastasis	
Positive	363
Negative	529
ND	4
Hepatic metastasis	
Positive	101
Negative	789
ND	6

ND, not described

Table 2. Comparison of clinicopathological variables in CRC patients with skip lymphovascular invasion and pT1/2 CRC patients without skip lymphovascular invasion

Variables	Skip lymphovascular invasion		P value
	Positive (n = 20)	Negative (n = 210)	
Age [years] (range)	64.0 (34 - 78)	67.0 (40 - 90)	0.544
Gender			0.909
Male	13	128	
Female	7	82	
Size [mm] (range)	25.6 (9 - 50)	26.7 (7 - 65)	0.979
Location			0.405
Right colon	5	45	
Left colon	4	73	
Rectum	11	92	
Tumor differentiation			0.177
Well	7	125	
Moderate	12	78	
Poor	0	5	
Others	1	2	
Lymphovascular invasion			
Positive	20	138	< 0.001
Negative	0	72	
Lymph node metastasis			> 0.999
Positive	3	31	
Negative	17	179	
Hepatic metastasis			
Positive	5	0	< 0.001
Negative	15	210	
Distant metastasis			0.087
Positive	1	0	
Negative	19	210	

Table 3. Details of CRC patients with skip lymphovascular invasion

No.	Age	Gender	Location	Size (mm)	Tumor differentiation	Direct invasion	Skip lymphovascular invasion	Lymph node metastasis	Hepatic metastasis	Stage	Follow - up period (month)	Outcome
1	56	M	Rectum	20	Moderate	pT2	Subserosa	-	-	I	1	Dead of other disease
2	57	M	Rectum	ND	Moderate	pT2	Subserosa	-	-	I	10	Dead of other disease
3	73	M	Rectum	20	Moderate	pT1	Subserosa	+	+#	III	22	Dead of disease
4	63	M	Sigmoid colon	22	Moderate	pT2	Subserosa	-	-	I	42	Alive
5	54	F	Rectum	ND	Moderate	pT2	Subserosa	-	-	I	45	Alive
6	70	F	Rectum	48	Moderate	pT2	Subserosa	-	-	I	56	Alive
7	34	M	Rectum	50	Moderate	pT2	Subserosa	-	-	I	58	Alive
8	67	F	Cecum	9	Well	pT1	Muscularis propria	-	-	I	59	Alive
9	55	M	Rectum	18	Moderate	pT2	Subserosa	-	-	I	59	Alive
10	76	M	Sigmoid colon	10	Moderate	pT2	Subserosa	-	-	I	60	Alive
11	68	M	Rectum	ND	Moderate	pT2	Subserosa	-	-	I	62	Alive
12	65	M	Descending colon	25	Well	pT2	Subserosa	-	-	I	63	Alive
13	65	F	Ascending colon	40	Well	pT2	Subserosa	+	+	IV	64	Alive
14	68	M	Cecum	ND	Well	pT2	Subserosa	-	+	IV	75	Alive
15	78	F	Cecum	15	Well	pT1	Muscularis propria	-	+	IV	82	Alive
16	70	M	Rectum	35	Well	pT2	Subserosa	-	+	IV	ND	ND
17	74	F	Rectum	27	Moderate	pT2	Subserosa	-	-	I	ND	ND
18	70	M	Transverse colon	15	Other	pT2	Subserosa	-	-	I	ND	ND
19	64	M	Rectum	30	Moderate	pT2	Subserosa	-	-	I	ND	ND
20	62	F	Sigmoid colon	26	Well	pT2	Subserosa	+	-	III	ND	ND

*, metachronous metastasis; ND, not described

Figure 1

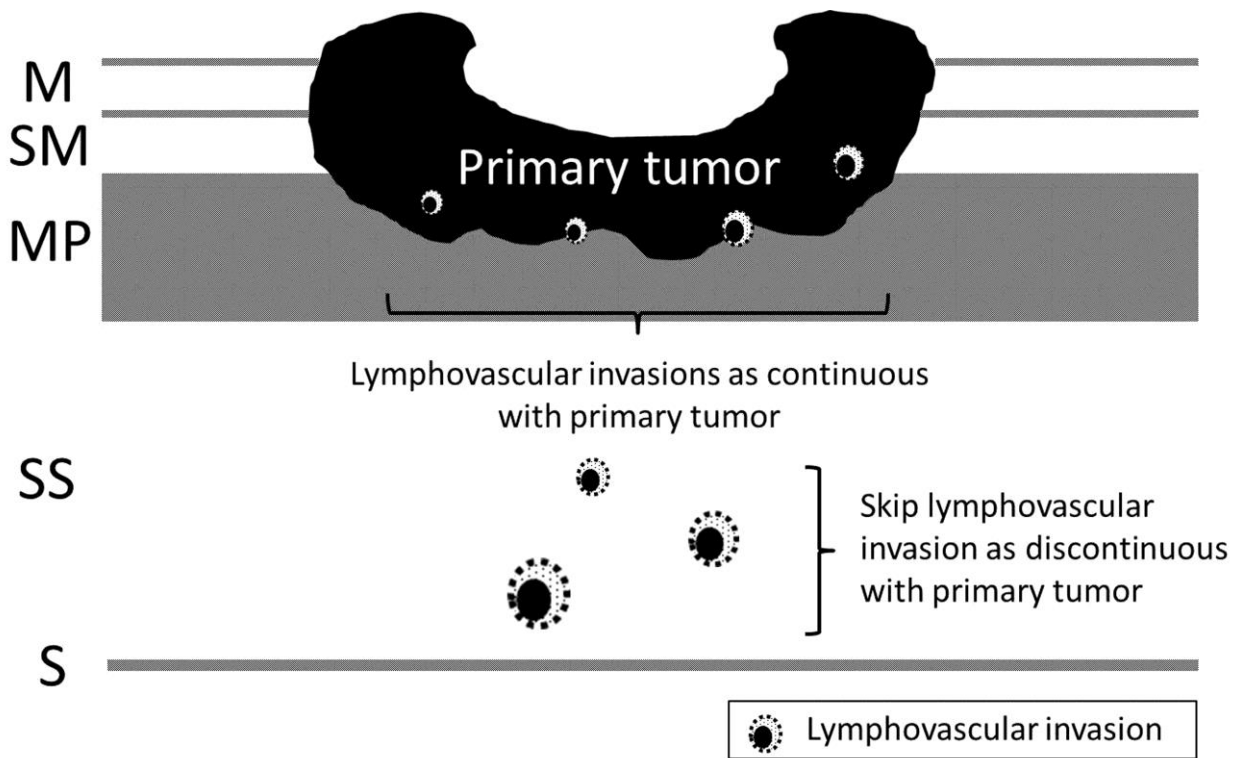


Figure 2

