

東邦大学学術リポジトリ



OPAC

東邦大学メディアセンター

タイトル	Serum VEGF as a tumor marker in patients with HCV related liver cirrhosis and hepatocellular carcinoma
別タイトル	肝細胞癌合併C型肝炎患者の診療における診断および腫瘍マーカーとしての血清VEGF測定の意義
作成者（著者）	向津, 隆規
公開者	東邦大学
発行日	2015.03
掲載情報	東邦大学大学院医学研究科 博士論文. 15.
資料種別	学位論文
内容記述	主査：瓜田純久 / タイトル：Serum VEGF as a tumor marker in patients with HCV related liver cirrhosis and hepatocellular carcinoma / 著者：Takanori Mukozu, Hidenari Nagai, Daigo Matsui, Takenori Kanekawa, Yasukiyo Sumino / 掲載誌：Anticancer Research / 巻号・発行年等：33(3):1013-1022, 2013 / 本文ファイル：出版者版
著者版フラグ	ETD
報告番号	32661甲第756号
学位授与年月日	2015.03.24
学位授与機関	東邦大学
その他資源識別子	http://ar.iijournals.org/content/33/3/1013.long
メタデータのURL	https://mylibrary.toho-u.ac.jp/webopac/TD40491498

Serum VEGF as a Tumor Marker in Patients with HCV-related Liver Cirrhosis and Hepatocellular Carcinoma

TAKANORI MUKOZU, HIDENARI NAGAI, DAIGO MATSUI, TAKENORI KANEKAWA and YASUKIYO SUMINO

*Division of Gastroenterology and Hepatology, Department of Internal Medicine (Omori),
Faculty of Medicine, Toho University School of Medicine, Ota-ku, Tokyo, Japan*

Abstract. Aim: Vascular endothelial growth factor (VEGF) is a primary driving force for both physiological and pathological angiogenesis, and its overexpression has been found in hepatocellular carcinoma (HCC). The aim of this study was to retrospectively clarify the usefulness of serum VEGF levels as a tumor marker in patients with hepatitis C virus (HCV)-related liver cirrhosis (CLC) and HCC. Materials and Methods: The patients with CLC were divided into three groups: 28 patients without HCC (CLC group), 11 patients with HCC (HCC group), and 48 patients with advanced HCC (aHCC group). The control group consisted of 37 patients with chronic HCV. Results: When the relation of serum VEGF to liver function was assessed, there was no significant difference of VEGF levels between the control group and the CLC group. When serum VEGF levels were assessed in relation to the presence of HCC, the VEGF levels of the HCC group and aHCC group were found to be significantly higher than that of the control group, while there was no significant difference between the control group and the CLC group. For the detection of cancer, serum VEGF had the largest area under the curve (AUC) and the highest accuracy when we employed the cut-off value obtained by receiver operating characteristic (ROC) analysis using the Youden index. Evaluation of various tumor markers in the aHCC group showed that the serum levels of α -fetoprotein (AFP) were higher in patients with infiltrating tumors than in patients with multiple discrete nodules or confluent multinodular tumors, while there were no significant differences in the serum levels of VEGF, Lens culinaris agglutinin-reactive fraction of AFP (AFP-L3), and

des- γ -carboxy prothrombin. There were no significant differences on the serum levels of all four markers between tumor stages, but serum VEGF was higher in patients with vascular invasion than in those without vascular invasion. Conclusion: The present findings suggest that the serum levels of VEGF might be a useful predictor of the presence of HCC in patients with CLC, while serum levels of AFP and VEGF can predict the tumor type and vascular invasion, respectively.

α -Fetoprotein (AFP) has been used for many years as a serum marker for hepatocellular carcinoma (HCC) diagnosis and screening (1, 2); however, in some cases, AFP has poor specificity in the detection of HCC (3, 4). Recently, the Lens culinaris agglutinin-reactive fraction of AFP (AFP-L3) (5-7) and *des- γ -carboxyprothrombin* (DCP) (8, 9) have been proposed as complements or substitutes for AFP in the diagnosis of HCC or the detection of recurrent HCC after locoregional treatment (10, 11). Patients who have liver cirrhosis need regular examination by abdominal ultrasound and measurement of tumor markers for HCC screening. In fact, the guidelines of the European Association for the Study of the Liver (EASL) and the Asian Pacific Association for the Study of the Liver (APASL) recommend measurement of AFP and abdominal ultrasound every six months (12, 13), while the National Comprehensive Cancer Network (NCCN) recommends these tests every 6-12 months (14). The Japanese Society of Hepatology recommends measurement of AFP, AFP-L3, or DCP and abdominal ultrasound every six months. Because patients with HBV- or HCV-related liver cirrhosis are considered to be a high-risk group, they should be screened every 3-4 months. Thus, tumor markers are used in three guidelines (15), although the American Association for the Study of Liver Disease (AASLD) recommends abdominal ultrasound every six months, without tumor marker measurement, because of the low specificity of AFP (16). Therefore, a more sensitive tumor marker than AFP, AFP-L3, or DCP is required to predict carcinogenesis in patients with liver cirrhosis.

Vascular endothelial growth factor (VEGF) is a primary driving force for both physiological and pathological

This article is freely accessible online.

Correspondence to: Hidenari Nagai, Division of Gastroenterology and Hepatology, Department of Internal Medicine (Omori), Faculty of Medicine, Toho University School of Medicine, 6-11-1, Omorinishi, Ota-ku, Tokyo, 143-8541, Japan. Tel: +81 337624151, Fax: +81 337638542, e-mail: hidenari@aol.com

Key Words: VEGF, HCV infection, tumor marker, HCC, carcinogenesis.

Table I. Clinical characteristics of the 124 patients with hepatitis C virus infection.

	Control	CLC	HCC	aHCC
No. of patients	37	28	11	48
Age (Mean±SD)	48.5±13	61.4±8	65.4±6	69.8±5
Gender (M/F)	20/17	17/11	9/2	42/6
Child-Pugh class (A/B/C)		16/7/5	9/2/0	30/14/4
Tumor type (multiple/diffuse/giant)				40/6/4
Stage (I/II/III/IVA/IVB)			7/4/0/0/0	0/0/7/34/7

CLC: Hepatitis C virus-related liver cirrhosis; HCC: hepatocellular carcinoma; aHCC: advanced hepatocellular carcinoma.

angiogenesis (17), and overexpression of VEGF is observed in HCC (18, 19). Although VEGF is also expressed in non-tumoral hepatic parenchyma, a higher level of expression is observed in tumor tissues (20, 21). VEGF is one of the most important angiogenic factors and it promotes angiogenesis in most human tumors (22). One of the notable features of most HCCs is hypervascularity (20), and it has been reported that VEGF expression is correlated with tumor vascularity (23). The circulating VEGF level was reported to be correlated with the stage of HCC and the highest VEGF levels are found in patients with metastasis (24).

Recently, Sorafenib[®] has been approved for anti-VEGF therapy, based on the SHARP study and the Asia-Pacific study (25, 26), such that VEGF has attracted attention again. The aim of this study was to retrospectively clarify whether the serum VEGF level is useful as a marker for the presence and progression of HCC in patients with HCV-related liver cirrhosis (CLC).

Materials and Methods

Patients. Eighty-seven adult Japanese patients who had CLC with or without HCC were treated at our hospital between 2004 and 2011. Blood samples were collected from patients in the morning. The control group was composed of 37 adult Japanese patients with chronic hepatitis C, diagnosed by examination of liver biopsy specimens. All patients had stage 1 or 2 liver disease according to the fibrosis score of Desmet (27).

Assays. Blood samples were drawn into a serum separator tube and centrifuged at 1,800 ×g for 10 min to obtain serum that was then stored at -80°C. Because VEGF levels increase over time due to degranulation of platelets (28), blood samples were processed within 30 min. Serum concentrations of VEGF were measured in duplicate with an enzyme-linked immunosorbent assay (ELISA) kit (Quantikine Human VEGF Immunoassay; R&D Systems, Minneapolis, MN, USA), by an investigator who was blinded to the clinical information of the patients. Measurements of AFP, AFP-L3, and DCP was performed by lectin-affinity electrophoresis coupled with antibody-affinity blotting method or a microchip capillary electrophoresis and liquid-phase binding assay using a μTSAWako i30 auto-analyzer (Wako Pure Chemical Industries, Ltd., Osaka, Japan) (5, 29).

Evaluation of HCC. The diagnosis of HCC was performed using clinical criteria and the findings obtained by B-mode ultrasonography (US), computed tomography (CT) angiography, or magnetic resonance imaging (MRI) (30, 31).

Statistical analysis. Statistical analysis was performed using the Statistical Package for the Social Sciences (SPSS version 11.0; SPSS, Chicago, IL, USA) and Ekuseru-Toukei 2010 (Social Survey Research Information Co., Ltd., Tokyo, Japan).

Receiver operating characteristics (ROC) curves were drawn in order to determine the best cut-off value of serum VEGF and to compare the accuracy of each tumor marker with that of VEGF. Dunnett's test was employed for comparisons between the control group and the CLC group, while the Tukey-Kramer test was used to compare each pair of groups and the Wilcoxon rank sum test was used for two groups without correspondence. A probability of less than 0.05 was considered to indicate statistical significance.

Results

The patients with CLC were divided into the following three groups. Twenty-eight of the 87 patients had CLC without HCC (CLC group), 11 patients had CLC with solitary HCC (HCC group) and 48 patients had CLC with advanced HCC (aHCC group). The control group consisted of 20 men and 17 women, aged 24-75 years (mean±SD, 48.5±13 years). There were 17 men and 11 women aged 42-78 years (61.4±8 years) in the CLC group, nine men and two women aged 58-75 years (65.4±6 years) in the HCC group, and 42 men and six women aged 57-83 years (69.8±5 years) in the aHCC group. The Child-Pugh class was A for 16 patients in the CLC group, nine patients in the HCC group, and 30 patients in the aHCC group, while it was B for seven, two, and 14 patients and C for five, none, and four patients, respectively. There were seven patients with stage I disease and four patients with stage II disease in the HCC group, while seven patients had stage III disease, 34 patients stage IVA, and seven patients stage IVB in the aHCC group (Table I).

Serum VEGF and liver function. Figure 1 shows the serum VEGF levels in the patients with CLC with or without HCC. There was no significant difference of serum VEGF between

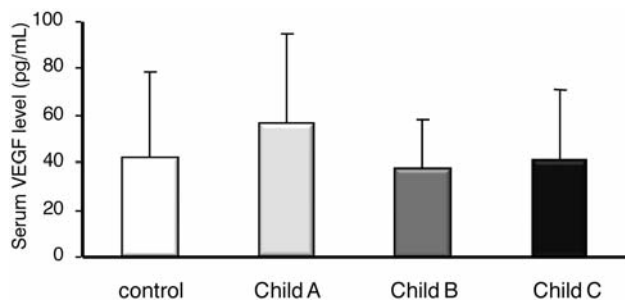


Figure 1. Serum levels of vascular endothelial growth factor (VEGF) in patients with liver cirrhosis (CLC) stratified according to Child-Pugh class. There were no significant differences of VEGF levels between the control and CLC groups. There were also no significant differences between the control group and each CLC subgroup stratified according to Child-Pugh class.

the control group (35.78±19.0 pg/ml) and the CLC group (49.48±34.4 pg/ml). In the CLC group, there were no significant differences of VEGF among the three Child-Pugh classes (class A: 41.66±36.74, class B: 37.76±20.17, class C: 41.38±29.54 pg/ml). The serum VEGF level of the HCC group (206.65±109.23 pg/ml) was significantly higher than that of the control group (35.78±18.96 pg/ml) ($p<0.05$ by Dunnett's test). The VEGF level of the aHCC group (343.88±241.85 pg/ml) was also significantly higher than that of the control group ($p<0.01$ by Dunnett's test) (Figure 2), but there was no significant difference of VEGF between the control group and the CLC group.

Detection of HCC. We evaluated which tumor marker was most useful for the detection of HCC. The cut-off values were 15 ng/ml for serum AFP, 15% for serum AFP-L3, 40 mAU/ml for serum DCP, and 108 pg/ml for serum VEGF. Using these values, the sensitivity was 0.98 and the specificity was 0.46 for VEGF, while the respective values were 0.76 and 0.62 for AFP, 0.49 and 0.88 for AFP-L3, and 0.54 and 0.77 for DCP (Table II). VEGF showed the highest sensitivity among the serum tumor markers. The cut-off values for serum AFP, AFP-L3, and DCP were obtained from the guideline of the Japanese Society of Hepatology (16). The cut-off value for VEGF was the optimum value shown by the ROC curve using the Youden index (Figure 3). Although it has been reported that the specificity of VEGF is very high and other serum tumor markers are similar (15), we re-assessed the performance of each tumor marker by creating ROC curves. The area under the ROC curve (AUC) for serum VEGF was 0.98, while the AUC values for serum AFP, AFP-L3, and DCP were 0.71, 0.62, and 0.61, respectively (Figure 4). In addition, the accuracy of VEGF was 0.894, while that of AFP, AFP-L3, and DCP was 0.714, 0.615, and 0.614, respectively (Table III). For diagnosis of HCC, serum VEGF had the largest AUC on ROC analysis

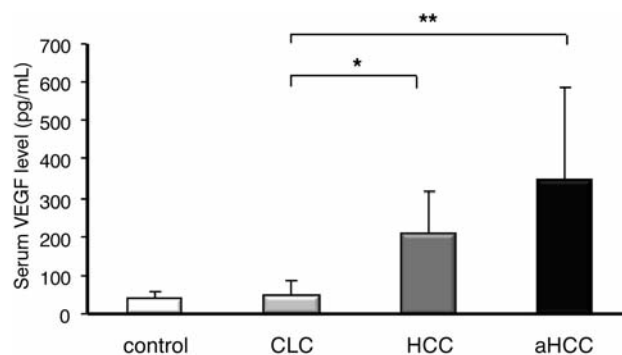


Figure 2. Serum level of vascular endothelial growth factor (VEGF) in patients with liver cirrhosis (CLC) with or without hepatocellular carcinoma (HCC). The VEGF levels of the HCC group were significantly higher than those of the control group ($*p<0.05$ by Dunnett's test) and the VEGF levels of the advanced HCC (aHCC) group were also significantly higher than those of the control group ($**p<0.01$ by Dunnett's test). However, there was no significant difference of VEGF levels between the control and CLC groups.

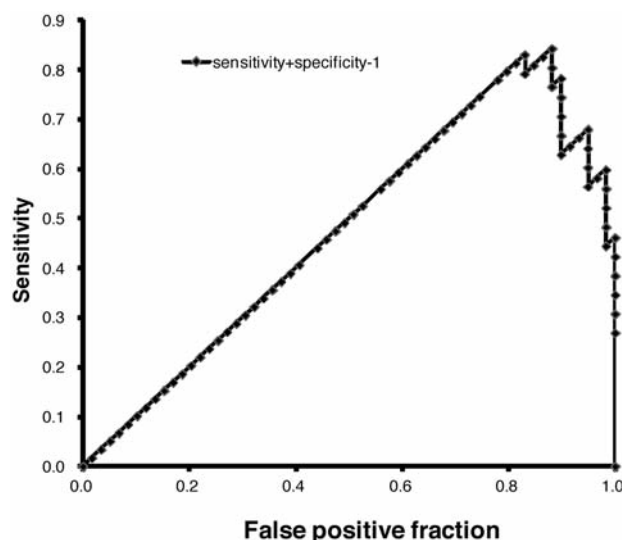


Figure 3. The cut-off value of serum vascular endothelial growth factor (VEGF) was the optimum value indicated by the receiver operating characteristic (ROC) curve drawn using the Youden index.

and had the highest accuracy. Moreover, the accuracy of VEGF was higher than that of a combination of the other three tumor markers (AFP, AFP-L3, and DCP). These results indicate that the serum VEGF level was more useful for the diagnosis of HCC than the other tumor markers in patients with CLC.

Tumor markers and tumor type. In the aHCC group, the serum level of AFP was higher when patients had diffuse tumors (84,787.2±122,280.7 ng/dl) than when patients had

multiple tumors (7699.9±18974 ng/dl) ($p < 0.01$ by the Tukey-Kramer test) or giant tumors (10,886.5±12,451 ng/dl) ($p < 0.05$ by the Tukey-Kramer test). However, there were no significant differences among the three tumor types for serum VEGF (multiple: 311.0±198 pg/ml, diffuse: 412.7±393 pg/ml, giant: 553.3±304 pg/ml), serum AFP-L3 (multiple: 26.5±27%, diffuse: 46.8±23%, giant: 20.9±30%), or serum DCP (multiple: 8751.6±31997 mAU/ml, diffuse: 30351.0±68107 mAU/ml, giant: 38415.0±32656 mAU/ml) (Figure 5).

Tumor markers and tumor stage. In the aHCC group, there were no significant differences of the serum levels of tumor markers among the different stages of HCC and the data were as follows: serum VEGF (stage III: 368.0±225 pg/ml, stage IVA: 324.2±247 pg/ml, stage IVB: 415.3±250 pg/ml), serum AFP (stage III: 2692.4±6301 ng/ml, stage IVA: 21859.1±59404 ng/ml, stage IVB: 13852.6±24713 ng/ml), serum AFP-L3 (stage III: 33.9±27%, stage IVA: 31.2±28%, stage IVB: 3.8±4%), and serum DCP (stage III: 4183.4±8064 mAU/ml, stage IVA: 15088.7±44306 mAU/ml, stage IVB: 19814.1±28902 mAU/ml) (Figure 6). However, the VEGF level was higher in patients with vascular invasion (489.0±268 pg/ml) than in patients without vascular invasion (304.3±217 pg/ml) ($p < 0.05$ by Wilcoxon's rank sum test) (Figure 7).

Discussion

El-Assal *et al.* reported that VEGF protein expression was lower in HCC than in the corresponding non-tumorous liver (32). However, it has also been reported that the vascular endothelial cells in tumor tissues show strong immunostaining for VEGF, whereas these cells do not show appreciable staining in non-tumorous tissues, and tumorous vascular endothelial cells may be the main target of VEGF released from HCC cells (33, 34). In addition, Mise *et al.* reported that VEGF is involved in neovascularization and infiltration of cancer cells into the tumor capsule in patients with HCC (35). Moreover, it was reported that VEGF levels are low under stable conditions, but hypoxia causes elevation of VEGF with tumor progression and oxygen tension plays a major role in VEGF expression (36, 37). With regard to the other tumor markers, it was reported that AFP is produced due to de-differentiation of cancer cells (38); AFP-L3 becomes detectable due to increased fucosylation of AFP because of increased GDP-fucose activity related to up-regulation of the *FX* gene expression in HCC cells (39); and DCP increases because of the low vitamin K concentration and hypoxia around HCC cells (40-42). Therefore, it seems that the measurement of VEGF detects a factor required for proliferation of HCC, while other markers indirectly detect the tumor. It is important to clarify the usefulness of VEGF as

Table II. Sensitivity and specificity for each tumor marker.

		Cut-off value			
AFP		≤15 ng/dl			
AFP-L3		≤15%			
DCP		≤40 m AU/ml			
VEGF		≤108 pg/ml			

VEGF: Vascular endothelial growth factor, AFP: α-fetoprotein; AFP-L3: lens culinaris agglutinin-reactive fraction of AFP; DCP: des-γ-carboxyprothrombin (DCP); HCC: hepatocellular carcinoma.

Parameter		HCC		Total
		+	-	
AFP	Positive	44	10	54.0
	Negative	14	16	30.0
	Total	58	26	
	Sensitivity		0.76	
	Specificity		0.62	
AFP-L3	Positive	26	3	29.0
	Negative	27	22	49.0
	Total	53	25	
	Sensitivity		0.49	
	Specificity		0.88	
DCP	Positive	31	6	37.0
	Negative	26	20	46.0
	Total	57	26	
	Sensitivity		0.54	
	Specificity		0.77	
VEGF	Positive	58	14	72.0
	Negative	1	12	13.0
	Total	59	26	
	Sensitivity		0.98	
	Specificity		0.46	

a tumor marker by comparison with other tumor markers in patients with liver cirrhosis with HCC. In the present study, there was no significant difference of the serum VEGF levels between the control group and the CLC group and there were also no significant differences of VEGF among the three Child-Pugh classes in the CLC group. The serum VEGF levels of the HCC group were significantly higher than that of the control group and the VEGF levels of the aHCC group were also significantly higher than that of the control group, but there was no significant difference of VEGF between the control group and the CLC group. These results indicated that development of HCC in patients with liver cirrhosis might be predicted by an increasing serum level of VEGF, although the VEGF levels were not related to liver function. We evaluated which serum tumor marker was most useful for the detection of HCC. As a result, VEGF showed higher sensitivity than the other tumor markers and it had the largest AUC on ROC analysis, as well as the highest accuracy. Furthermore, the

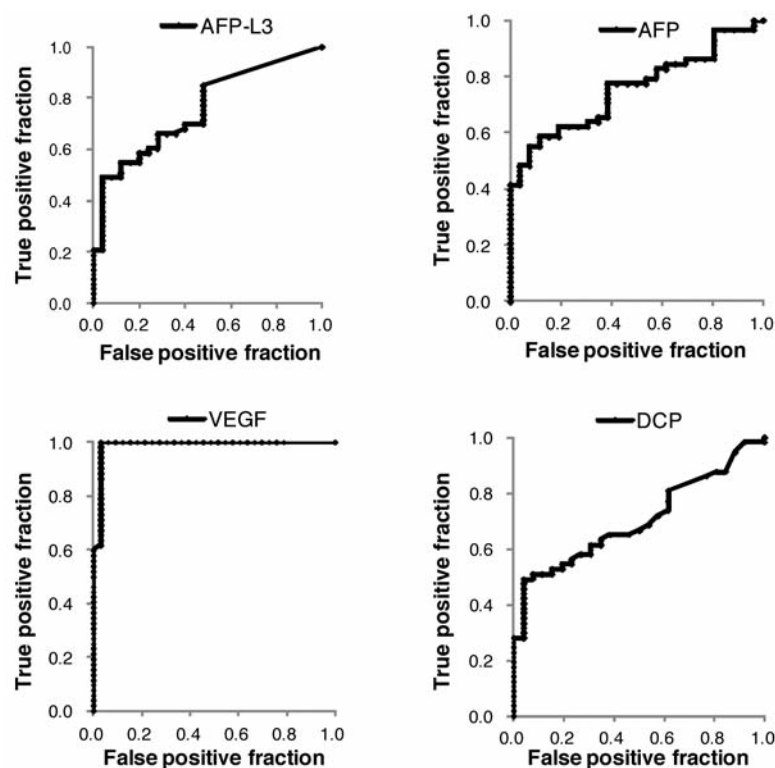


Figure 4. Performance of tumor markers assessed by receiver operating characteristic (ROC) analysis. The area under the ROC curve (AUC) for serum vascular endothelial growth factor (VEGF) was 0.98, while the AUC values for serum α -fetoprotein (AFP), lens culinaris agglutinin-reactive fraction of AFP (AFP-L3), and *des*- γ -carboxyprothrombin (DCP) were 0.71, 0.62, and 0.61, respectively.

Table III. Diagnostic accuracy for various tumor markers.

Marker	Sensitivity	Specificity	Accuracy	Area under the curve
AFP (cut-off <15 ng/ml)	0.759	0.615	0.714	0.755
AFP-L3 (cut-off <15%)	0.491	0.880	0.615	0.755
DCP (cut-off <40 mAU/ml)	0.544	0.769	0.614	0.702
VEGF (cut-off <108 pg/ml)	0.864	0.962	0.894	0.988
IAFP+AFP-L3+DCP	0.868	0.480	0.744	?

VEGF: Vascular endothelial growth factor; AFP: D α -fetoprotein; AFP-L3: lens culinaris agglutinin-reactive fraction of AFP; DCP: *des*- γ -carboxyprothrombin (DCP).

accuracy of VEGF was higher than that of the combination of three other tumor markers. These results indicate that serum VEGF is more useful for detection of HCC than other serum tumor markers in patients with CLC. Thus, addition of a test for VEGF might improve the performance of HCC screening, although there are also many unknown factors regarding the production of the other three tumor markers.

In this study, we estimated the usefulness of serum tumor markers in patients with aHCC in relation to the tumor type, stage, and vascular invasion. Assessment of the relation between various serum markers and tumor type showed that there were

no significant differences of VEGF, AFP-L3, and DCP levels among the three tumor types, although serum AFP levels were higher in patients with diffuse tumors. It has been reported that AFP is produced due to the de-differentiation of cancer cells (38), and that HCC is often well-differentiated at an early stage and undergoes de-differentiation as it grows (43). Unlike AFP, production of DCP depends on a low concentration of vitamin K and hypoxia around HCC cells (40-42). In the present study, serum AFP was not notably increased because there were many well-differentiated carcinomas. It was reported that early HCC (Edmondson-Steiner grade 1) is occasionally hypovascular on

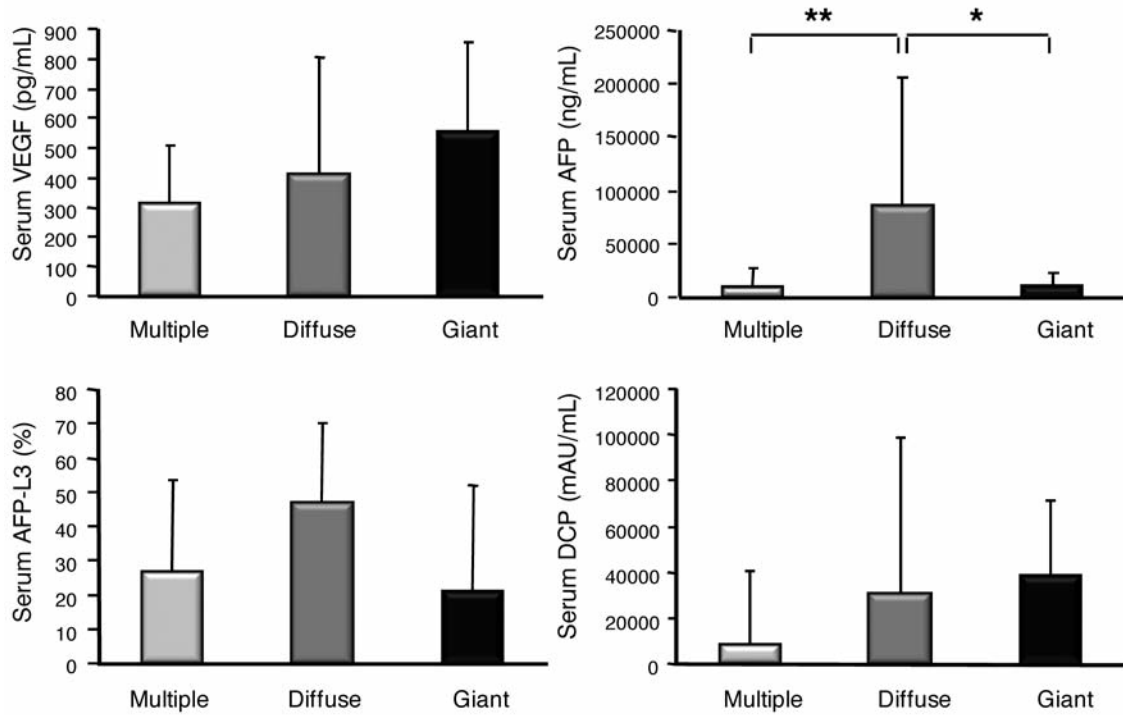


Figure 5. Tumor marker levels in each tumor type from the advanced hepatocellular carcinoma (aHCC) group. The serum level of α -fetoprotein (AFP) was higher in patients with diffuse tumors than in those with multiple tumors (** $p < 0.01$ by the Tukey-Kramer test) or giant tumors (* $p < 0.05$ by the Tukey-Kramer test). However, there were no significant differences of serum vascular endothelial growth factor (VEGF), lens culinaris agglutinin-reactive fraction of AFP (AFP-L3), or des- γ -carboxyprothrombin (DCP) among the three tumor types.

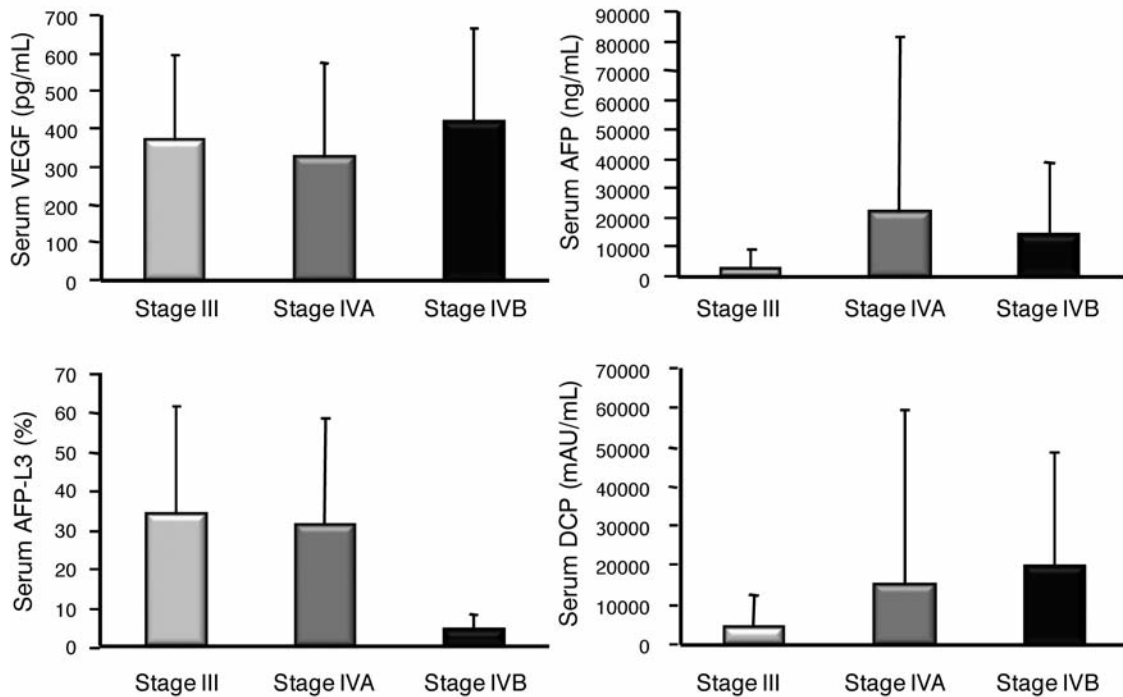


Figure 6. Tumor marker levels for each stage of hepatocellular carcinoma (HCC). There were no significant differences among each stage for any of the tumor markers. VEGF: Vascular endothelial growth factor, AFP: α -fetoprotein, AFP-L3: lens culinaris agglutinin-reactive fraction of AFP, DCP: des- γ -carboxyprothrombin (DCP).

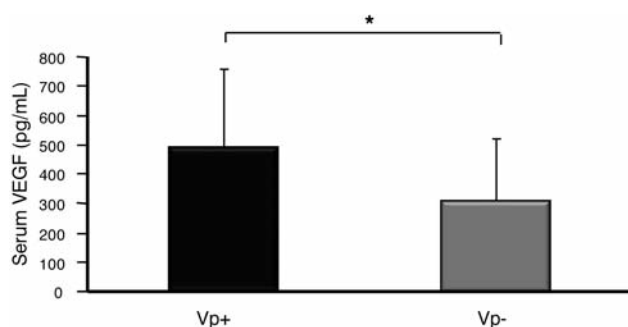


Figure 7. Serum vascular endothelial growth factor (VEGF) levels in patients from the advanced hepatocellular carcinoma (aHCC) group with or without vascular invasion. Serum VEGF was higher in patients with vascular invasion (Vp+) than in patients without vascular invasion (Vp-) ($p < 0.05$ by the Wilcoxon rank sum test).

angiography or CT arteriography (44) and that the number of arteries in a hepatic nodule increases during progression from adenomatous hyperplasia to atypical adenomatous hyperplasia and then HCC (45). Stroescu *et al.* reported that overexpression of VEGF was more frequent in large HCCs than small HCCs and that VEGF expression was far stronger in patients with poorly-differentiated HCC (46). Suzuki *et al.* reported that large HCC nodules (>3 cm) tended to have internal hypoxia and necrosis, with up-regulation of the expression of VEGF mRNA (21). In the present study, serum VEGF levels decreased in the order of giant>diffuse>multiple tumors, although there were no significant differences among the three tumor types. These results might indicate that the serum levels of VEGF is high in patients with early small tumors that are well-differentiated and decreases with tumor progression, and that diffuse tumors are mainly well-differentiated, while multiple tumors exhibit intermediate differentiation and giant tumors are affected by hypoxia and necrosis. Moreover, VEGF levels were higher in patients with vascular invasion than in patients without vascular invasion, although there were no significant differences in the levels of any tumor marker among the tumor stages. It has been reported that patients with HCC with vascular invasion develop numerous microscopic intrahepatic metastases and that patients with HCC, undetectable by imaging, have high serum levels of VEGF (47, 48). This might indicate that angiogenesis by microscopic intrahepatic HCC is reflected in the serum VEGF level.

Conclusion

The present findings suggested that the serum levels of VEGF might be a useful predictor of the presence of HCC in patients with CLC, while serum AFP and VEGF might be important for predicting tumor type and vascular invasion, respectively.

References

- 1 Abelev GI: Production of embryonal serum alpha-globulin by hepatomas: review of experimental and clinical data. *Cancer Res* 28: 1344-1350, 1968.
- 2 O'Connor GT, Tatarinov YS, Abelev GI and Uriel J: A collaborative study for the evaluation of a serologic test for primary liver cancer. *Cancer* 25: 1091-1098, 1970.
- 3 Di Bisceglie AM, Sterling RK, Chung RT, Everhart JE, Dienstag JL, Bonkovsky HL, Wright EC, Everson GT, Lindsay KL, Lok AS, Lee WM, Morgan TR, Ghany MG, Gretch DR; HALT-C Trial Group: Serum alpha-fetoprotein levels in patients with advanced hepatitis C: Results from the HALT-C Trial. *J Hepatol* 43: 434-441, 2005.
- 4 Ezaki T, Yukaya H, Ogawa Y, Chang YC and Nagasue N: Elevation of alpha-fetoprotein level without evidence of recurrence after hepatectomy for hepatocellular carcinoma. *Cancer* 61: 1880-1883, 1988.
- 5 Taketa K, Endo Y, Sekiya C, Tanikawa K, Koji T, Taga H, Satomura S, Matsuura S, Kawai T and Hirai H: A collaborative study for the evaluation of lectin-reactive alpha-fetoproteins in early detection of hepatocellular carcinoma. *Cancer Res* 53: 5419-5423, 1993.
- 6 Aoyagi Y, Saitoh A, Suzuki Y, Igarashi K, Oguro M, Yokota T, Mori S, Suda T, Isemura M and Asakura H: Fucosylation index of alpha-fetoprotein, a possible aid in the early recognition of hepatocellular carcinoma in patients with cirrhosis. *Hepatology* 17: 50-52, 1993.
- 7 Sato Y, Nakata K, Kato Y, Shima M, Ishii N, Koji T, Taketa K, Endo Y and Nagataki S: Early recognition of hepatocellular carcinoma based on altered profiles of alpha-fetoprotein. *N Engl J Med* 328: 1802-1806, 1993.
- 8 Fujiyama S, Moroshita T, Hashiguchi O and Sato T: Plasma abnormal prothrombin (*des*-gamma-carboxy prothrombin) as a marker of hepatocellular carcinoma. *Cancer* 61: 1621-1628, 1988.
- 9 Liebman HA, Furie BC, Tong MJ, Blanchard RA, Lo KJ, Lee SD, Coleman MS and Furie B: *Des*-gamma-carboxy (abnormal) prothrombin as a serum marker of primary hepatocellular carcinoma. *N Engl J Med* 310: 1427-1431, 1984.
- 10 Ando E, Tanaka M, Yamashita F, Kuromatsu R, Takada A, Fukumori K, Yano Y, Sumie S, Okuda K, Kumashiro R and Sata M: Diagnostic clues for recurrent hepatocellular carcinoma: Comparison of tumor markers and imaging studies. *Eur J Gastroenterol Hepatol* 15: 641-648, 2003.
- 11 Beppu T, Sugimoto K, Shiraki K, Tameda M, Kusagawa S, Nojiri K, Tanaka J, Yamamoto N, Takei Y, Takaki H, Uraki J, Nakatsuka A, Yamakado K and Takeda K: Clinical significance of tumor markers in detection of recurrent hepatocellular carcinoma after radiofrequency ablation. *Int J Mol Med* 26: 425-433, 2010.
- 12 Bruix J: Clinical management of hepatocellular carcinoma. Conclusion of the Barcelona-2000 EASL conference. *J Hepatol* 35: 421-430, 2001.
- 13 Omata M: Asian Pacific Association for the Study of the Liver consensus recommendations on hepatocellular carcinoma. *Hepatol Int* 4: 439-474, 2010.
- 14 Benson AB 3rd, Abrams TA, Ben-Josef E, Bloomston PM, Botha JF, Clary BM, Covey A, Curley SA, D'Angelica MI, Davila R, Ensminger WD, Gibbs JF, Laheru D, Malafa MP, Marrero J, Meranze SG, Mulvihill SJ, Park JO, Posey JA, Sachdev J, Salem R, Sigurdson ER, Sofocleous C, Vauthey JN, Venook AP, Goff

- LW, Yen Y and Zhu AX: NCCN clinical practice guidelines in oncology: hepatobiliary cancers. *J Natl Compr Canc Netw* 7: 350-391, 2009.
- 15 Kudo M, Izumi N, Kokudo N, Matsui O, Sakamoto M, Nakashima O, Kojiro M, Makuuchi M; HCC Expert Panel of Japan Society of Hepatology: Management of hepatocellular carcinoma in Japan: Consensus-Based Clinical Practice Guidelines proposed by the Japan Society of Hepatology (JSH) 2010 updated version. *Dig Dis* 29: 339-64, 2011.
 - 16 Bruix J and Sherman M: Management of hepatocellular carcinoma: An update. *Hepatology* 53: 1020-1022, 2011.
 - 17 Semela D and Dufour JF: *In*: Vascular endothelial growth factor signaling. *Signaling Pathways in Liver Disease*. Dufour JF, Clavien PA (eds.). Springer-Verlag, Berlin Germany, pp. 91-104, 2005.
 - 18 Miura H, Miyazaki T, Kuroda M, Oka T, Machinami R, Kodama T, Shibuya M, Makuuchi M, Yazaki Y, Ohnishi S: Machinami R, Kodama T, Shibuya M, Makuuchi M, Yazaki Y and Ohnishi S: Increased expression of vascular endothelial growth factor in human hepatocellular carcinoma. *J Hepatol* 27: 854-861, 1997.
 - 19 Yamaguchi R, Yano H, Iemura A, Ogasawara S, Haramaki M and Kojiro M: Expression of vascular endothelial growth factor in human hepatocellular carcinoma. *Hepatology* 28: 68-77, 1998.
 - 20 Yoshiji H, Kuriyama S, Hicklin DJ, Huber J, Yoshii J, Miyamoto Y, Kawata M, Ikenaka Y, Nakatani T, Tsujinoue H and Fukui H: KDR/FLK-1 is a major regulator of vascular endothelial growth factor-induced tumor development and angiogenesis in murine hepatocellular carcinoma cells. *Hepatology* 30: 1179-1186, 1999.
 - 21 Suzuki K, Hayashi N, Miyamoto Y, Yamamoto M, Ohkawa K, Ito Y, Sasaki Y, Yamaguchi Y, Nakase H, Noda K, Enomoto N, Arai K, Yamada Y, Yoshihara H, Tujimura T, Kawano K, Yoshikawa K and Kamada T: Expression of permeability factor/vascular endothelial growth factor in human hepatocellular carcinoma. *Cancer Res* 56: 3004-3009, 1996.
 - 22 Ferrara N and Davis-Smyth T: The biology of vascular endothelial growth factor. *Endocr Rev* 18: 4-25, 1997.
 - 23 Moon WS, Rhyu KH, Kang MJ, Lee DG, Yu HC, Yeum JH, Koh GY and Tarnawski AS: Overexpression of VEGF and angiopoietin 2: A key to high vascularity of hepatocellular carcinoma? *Mod Pathol* 16: 552-557, 2003.
 - 24 Jinno K, Tanimizu M, Hyodo I, Nishikawa Y, Hosokawa Y, Doi T, Endo H, Yamashita T and Okada Y: Circulating vascular endothelial growth factor (VEGF) is a possible tumor marker for metastasis in human hepatocellular carcinoma. *J Gastroenterol* 33: 376-382, 1998.
 - 25 Llovet JM, Ricci S, Mazzaferro V, Hilgard P, Gane E, Blanc JF, de Oliveira AC, Santoro A, Raoul JL, Forner A, Schwartz M, Porta C, Zeuzem S, Bolondi L, Greten TF, Galle PR, Seitz JF, Borbath I, Häussinger D, Giannaris T, Shan M, Moscovici M, Voliotis D, Bruix J; SHARP Investigators Study Group: Sorafenib in advanced hepatocellular carcinoma. *N Engl J Med* 359: 378-390, 2008.
 - 26 Cheng AL, Kang YK, Chen Z, Tsao CJ, Qin S, Kim JS, Luo R, Feng J, Ye S, Yang TS, Xu J, Sun Y, Liang H, Liu J, Wang J, Tak WY, Pan H, Burock K, Zou J, Voliotis D and Guan Z: Efficacy and safety of sorafenib in patients in the Asia-Pacific region with advanced hepatocellular carcinoma: a phase III randomized, double-blind, placebo-controlled trial. *Lancet Oncol* 10: 25-34, 2009.
 - 27 Desmet VJ, Gerber M, Hoofnagle JH, Manns M and Scheuer PJ: Classification of chronic hepatitis: diagnosis, grading and staging. *Hepatology* 19: 1511-1520, 1994.
 - 28 Ferroni P, Spila A, D'Alessandro R, Martini F, Iacovone F, Ettorre GM, Vennarecci G, Santoro R, Puoti C and Guadagni F: Platelet activation and vascular endothelial growth factor 165 release in hepatocellular cancer. *Clin Chim Acta* 412: 450-454, 2011.
 - 29 Kagebayashi C, Yamaguchi I, Akinaga A, Kitano H, Yokoyama K, Satomura M, Kurosawa T, Watanabe M, Kawabata T, Chang W, Li C, Bousse L, Wada HG and Satomura S: Automated immunoassay system for AFP-L3% using on-chip electrokinetic reaction and separation by affinity electrophoresis. *Anal Biochem* 388: 306-311, 2009.
 - 30 Kudo M: Imaging diagnosis of hepatocellular carcinoma and remnant/borderline lesions. *Semin Liver Dis* 19: 297-309, 1999.
 - 31 Torzilli G, Minagawa M, Takayama T, Inoue K, Hui AM, Kubota K, Ohtomo K and Makuuchi M: Accurate preoperative evaluation of liver mass lesions without fine-needle biopsy. *Hepatology* 30: 889-893, 1999.
 - 32 El-Assal ON, Yamanoi A, Soda Y, Yamaguchi M, Igarashi M, Yamamoto A, Nabika T and Nagasue N: Clinical significance of microvessel density and vascular endothelial growth factor expression in hepatocellular carcinoma and surrounding liver: Possible involvement of vascular endothelial growth factor in the angiogenesis of cirrhotic liver. *Hepatology* 27: 1554-1562, 1998.
 - 33 Plate KH, Breier G, Weich HA and Risau W: Vascular endothelial growth factor is a potential angiogenesis factor in human gliomas *in vivo*. *Nature* 359: 845-848, 1992.
 - 34 Brown LF, Berse B, Tognazzi K, Manseau EJ, Van de Water L, Senger DR, Dvorak HF and Rosen S: Vascular permeability factor mRNA and protein expression in human kidney. *Kidney Int* 42: 1457-1461, 1992.
 - 35 Mise M, Arii S, Higashitani H, Furutani M, Niwano M, Harada T, Ishigami S, Toda Y, Nakayama H, Fukumoto M, Fujita J and Imamura M: Clinical significance of vascular endothelial growth factor and basic fibroblast growth factor gene expression in liver tumor. *Hepatology* 23: 455-464, 1996.
 - 36 von Marschall Z, Cramer T, Höcker M, Höcker M, Finkenzeller G, Wiedenmann B and Rosewicz S: Dual mechanism of vascular endothelial growth factor upregulation by hypoxia in human hepatocellular carcinoma. *Gut* 48: 87-96, 2001.
 - 37 Harris AL: Hypoxia – a key regulatory factor in tumor growth. *Nat Rev Cancer* 2: 38-47, 2002.
 - 38 Yeh SH, Chen PJ, Lai MY: Allelic loss on chromosomes 4q and 16q in hepatocellular carcinoma: Association with elevated alpha-fetoprotein production. *Gastroenterology* 110: 184-192, 1996.
 - 39 Noda K, Miyoshi E, Gu J, Gao CX, Nakahara S, Kitada T, Honke K, Suzuki K, Yoshihara H, Yoshikawa K, Kawano K, Tonetti M, Kasahara A, Hori M, Hayashi N and Taniguchi N: Relationship between elevated FX expression and increased production of GDP-L-fucose, a common donor substrate for fucosylation in human hepatocellular carcinoma and hepatoma cell lines. *Cancer Res* 63: 6282-6289, 2003.
 - 40 Murata K and Sakamoto A: Impairment of clathrin-mediated endocytosis via cytoskeletal change by epithelial to fibroblastoid conversion in HepG2 cells: a possible mechanism of des-γ-carboxy prothrombin production in hepatocellular carcinoma. *Int J Oncol* 33: 1149-55, 2008.

- 41 Murata K, Suzuki H, Okano H, Oyamada T, Yasuda Y and Sakamoto A: Cytoskeletal changes during epithelial-to-fibroblastoid conversion as a crucial mechanism of des- γ -carboxy prothrombin production in hepatocellular carcinoma. *Int J Oncol* 35: 1005-1014, 2009.
- 42 Mizuta T, Ozaki I, Eguchi Y, Yasutake T, Kawazoe S, Fujimoto K and Yamamoto K: The effect of menatetrenone, a vitamin K2 analog, on disease recurrence and survival in patients with hepatocellular carcinoma after curative treatment: a pilot study. *Cancer* 106: 867-872, 2006.
- 43 Kojiro M: Pathological evolution of early hepatocellular carcinoma. *Oncology* 62: 43-47, 2002.
- 44 Takayasu K, Shima Y, Muramatsu Y, Goto H, Moriyama N, Yamada T, Makuuchi M, Yamasaki S, Hasegawa H, Okazaki N, Hirohashi S and Kishi K: Angiography of small hepatocellular carcinomas: analysis of 105 resected tumors. *AJR Am J Roentgenol* 147: 525-529, 1986.
- 45 Ueda K, Terada T, Nakamura Y and Matsui O: Vascular supply in adenomatous hyperplasia of the liver and hepatocellular carcinoma: a morphometric study. *Hum Pathol* 23: 619-626, 1992.
- 46 Stroescu C, Dragnea A, Ivanov B, Pechianu C, Herlea V, Sgarbura O, Popescu A and Popescu I: Expression of p53, BCL-2, VEGF, Ki67 and PCNA and prognostic significance in hepatocellular carcinoma. *J Gastrointest Liver Dis* 17: 411-417, 2008.
- 47 Matsumata T, Kanematsu T, Takenaka K, Yoshida Y, Nishizaki T and Sugimachi K: Patterns of intrahepatic recurrence after curative resection of hepatocellular carcinoma. *Hepatology* 9: 457-460, 1989.
- 48 Toyosaka A, Okamoto E, Mitsunobu M, Oriyama T, Nakao N and Miura K: Pathologic and radiographic studies of intrahepatic metastasis in hepatocellular carcinoma; the role of efferent vessels. *HPB Surg* 10: 97-103, 1996.

Received December 12, 2012

Revised January 31, 2013

Accepted January 31, 2013