

東邦大学学術リポジトリ



OPAC

東邦大学メディアセンター

タイトル	Comparison between quantitative stiffness measurements and ultrasonographic findings of fresh carotid plaques
別タイトル	新鮮頸動脈プラークの硬度と術前超音波所見との比較
作成者（著者）	近藤, 康介
公開者	東邦大学
発行日	2017.04.27
掲載情報	東邦大学大学院医学研究科 博士論文. 61.
資料種別	学位論文
内容記述	主査：渡邊善則 / タイトル：Comparison between quantitative stiffness measurements and ultrasonographic findings of fresh carotid plaques / 著者：Kosuke Kondo, Masaaki Nemoto, Naoyuki Harada, Daisuke Fukushima, Hiroyuki Masuda, Nobuo Sugo / 掲載誌：Ultrasound in Medicine and Biology / 巻号・発行年等：43(1):138 144, 2017 / 本文ファイル: 出版者版
著者版フラグ	ETD
報告番号	32661乙第2865号
学位記番号	乙第2713号
学位授与年月日	2017.04.27
学位授与機関	東邦大学
DOI	info:doi/10.1016/j.ultrasmedbio.2016.08.014
その他資源識別子	http://www.sciencedirect.com/science/article/pii/S0301562916302502
メタデータのURL	https://mylibrary.toho.u.ac.jp/webopac/TD39003827

● *Original Contribution*

COMPARISON BETWEEN QUANTITATIVE STIFFNESS MEASUREMENTS AND ULTRASONOGRAPHIC FINDINGS OF FRESH CAROTID PLAQUES

KOSUKE KONDO, MASAOKI NEMOTO, NAOYUKI HARADA, DAISUKE FUKUSHIMA, HIROYUKI MASUDA,
and NOBUO SUGO

Department of Neurosurgery (Omori), School of Medicine, Faculty of Medicine, Toho University, Ota-ku, Tokyo, Japan

(Received 27 February 2016; revised 13 June 2016; in final form 12 August 2016)

Abstract—Using a stiffness meter, we quantitatively measured the stiffness of fresh plaques that had been excised by carotid endarterectomy. The objective of this study was to clarify the correlation between plaque stiffness and pre-operative carotid ultrasonographic findings, and predict the stiffness of plaques before surgery by comparison with the stiffness of common items. The study population comprised 44 patients (44 lesions) who had undergone carotid endarterectomy at our institution between December 2009 and October 2014. The stiffness of excised fresh plaques was measured using a stiffness meter and compared with the pre-operative echographic findings for the plaques and the stiffness of selected foods and common items. The mean stiffness value for all plaques was 4.52 ± 3.30 MPa (mean \pm standard deviation). The plaques exhibiting calcification were significantly harder ($p = 0.001$). On classification of lesions on the basis of echographic findings, plaque hardness was in the order low-echoic (15 lesions) < iso-echoic (20 lesions) < high-echoic (9 lesions) ($p = 0.02$). The stiffness of the low-echoic group was equivalent to that of tofu or sliced cheese, whereas the plaques in the iso- and high-echoic groups exhibited stiffness similar to that of ham and a plastic eraser, respectively. A significant correlation was observed between the quantitative stiffness values of carotid plaques and their brightness on carotid ultrasonography. Using these data, operators might be able to predict plaque stiffness from pre-operative echographic findings. In addition, it might be useful for operators to compare such quantitative stiffness measurements with stiffness data for foods and common items to gain an understanding of the state of the target plaque before treatment. (E-mail: k-kondo@med.toho-u.ac.jp) © 2016 World Federation for Ultrasound in Medicine & Biology.

Key Words: Carotid plaque, Ultrasonography, Plaque stiffness, Carotid endarterectomy, Stiffness meter.

INTRODUCTION

Carotid artery stenosis is caused by arteriosclerotic changes in the cervical carotid bifurcation. It was previously considered to develop more frequently in Westerners, but its incidence in Japan has increased with changes in diet, lifestyle and aging (Iwasaki et al. 2008). An arteriosclerosis-induced localized intimal protrusion exceeding 1 mm is termed a *plaque*. The thickening of such plaques leads to carotid artery stenosis, which can cause cerebral infarction (Cao et al. 2003;

Davies 2000; Inoue et al. 2007; Nowaczenco et al. 2003; O’Leary et al. 1999).

Cerebral infarctions develop from carotid artery stenosis *via* two main pathogenic pathways: hemodynamic development caused by the progression of stenosis and embolisms caused by plaque dispersion (Molloy and Markus 1999; Verhoeven et al. 2005). In the former, the risk of cerebral infarction can be reduced by resolving stenosis, and the surgical indication is decided based on the degree of stenosis and the presence or absence of other neurologic symptoms (Barnett et al. 1998; European Carotid Surgery Trialists’ Collaborative Group 1995, 1998; Executive Committee for the Asymptomatic Carotid Atherosclerosis Study 1995; Hobson et al. 1993; Mayberg et al. 1991; North American Symptomatic Carotid Endarterectomy Trial Collaborators 1991; Rothwell et al. 1994). For the latter, plaques with various properties likely to serve as a source of embolism have been reported, but evidence

Address correspondence to: Kosuke Kondo, Department of Neurosurgery (Omori), School of Medicine, Faculty of Medicine, Toho University, 6-11-1, Omori-nishi, Ota-ku, Tokyo, 143-8541, Japan. E-mail: k-kondo@med.toho-u.ac.jp

Conflict of interest disclosure: The authors have nothing to disclose.

is still insufficient. Thus, the conditions for surgical indication based on plaque properties have not yet been established (Aburahma *et al.* 2002; Grønholdt *et al.* 2001; Rothwell *et al.* 1994; Yuan *et al.* 2002).

Carotid ultrasonography is a non-invasive, simple test that is generally used to examine carotid artery stenosis. In addition to being useful for measuring the rate of stenosis, it is superior in evaluating plaque properties. Echo findings of plaques likely to become a source of embolism include low echogenicity, heterogeneity, ulceration and irregular surface (Elatrozy *et al.* 1998; Lee 2014). Of these, high consistency of the brightness with histopathologic findings is known (Czernuszewicz *et al.* 2015). Close involvement of soft plaque in the development of embolic infarction has been pointed out, and the subjective evaluation of plaque stiffness has occasionally been reported (Lee *et al.* 1992; Ohayon *et al.* 2008; Williamson *et al.* 2003).

Carotid stenosis is treated mainly by carotid endarterectomy (CEA) and carotid artery stenting (CAS). CEA is a surgical treatment in which the intima-media complex (IMC) of the stenotic region is excised (Javid and Tylon 1978). CAS is an interventional therapy in which the stenotic region is dilated by inserting a metal stent (Diethrich *et al.* 1996; Ederle *et al.* 2007). Although it is a newer method than CEA, performing CAS with a protective device to prevent distal embolisms has been found to be comparably effective and tolerable compared with CEA in high-risk patients (Gurm *et al.* 2008; Yadav *et al.* 2004).

In the study described here, we used a stiffness meter to quantitatively measure the stiffness of fresh plaques that had been excised by CEA. For this method of measuring the carotid intima, past literature is helpful in measuring the mechanical properties (Maher *et al.* 2009; Stemper *et al.* 2005). The objective of this study was to clarify the correlation between the quantitative stiffness values of plaques and their pre-operative echographic findings, and to obtain data that could be used to predict plaque stiffness before treatment. In addition, the stiffness of the plaques was compared with those of selected foods and common items to provide operators with easy-to-understand examples of stiffness.

METHODS

Study sample and data collection

This study was approved by the ethics committee of Toho University (Approval No. 2500622035). Written informed consent was obtained from all patients for CEA.

Patient population

Of 47 consecutive patients treated with CEA at our institution between December 2009 and October 2014,

comparisons of plaque stiffness with pre-operative carotid ultrasonography findings were possible in 44 patients (44 lesions), who were subsequently selected for participation in this study (including 41 males, mean age: 69.7 ± 7.4 y).

Carotid ultrasonography

A XARIO SSA-660 A (Toshiba Medical Systems, Tochigi, Japan) was used as the measurement device, and a PLT-805 AT (Toshiba Medical Systems, Tochigi, Japan) and a PLT-704 AT (Toshiba Medical Systems, Tochigi, Japan) were used as transducers. The frequency of the transducer was 8.0 MHz. During each examination, the neck of the subject, who was in the supine position, was extended to widen the observation field, and the head was tilted toward the healthy side. Tomographic images of the carotid artery were obtained along the minor and major vascular axes. Supplementary cans of difficult-to-visualize regions were obtained in two or more anterior and lateral directions, and the common carotid artery, carotid bulb and internal carotid artery were specified as essential observation regions. To evaluate the plaques, intima-media thickness (IMT) of the thickest part of the plaque, that is, the maximum IMT (max IMT), was measured on tomographic images obtained in the systolic phase of the artery. From these measurements, diameter- and area-based degrees of stenosis of the target artery were determined using the European Carotid Surgery Trial (ECST) and area methods, respectively (European Carotid Surgery Trialists' Collaborative Group 1991). The presence or absence of ulceration of the plaque surface was also evaluated. In addition, the brightness of the narrowest region of the plaque was classified as low-echoic, iso-echoic or high-echoic based on the brightness of the IMC near the plaque. Plaques that were difficult to classify were assigned to the mixed type, and when the brightness of a plaque's internal echo signals could not be determined because of calcification, it was regarded as indistinguishable.

Quantitative stiffness measurement with a stiffness meter

A CR-500 DX-S II rheometer (Sun Scientific, Tokyo, Japan) was used as the stiffness meter (Fig. 1a). Stiffness was measured by pressing the sample on a measurement table with a special adaptor (Fig. 1b). Rheo Data Analyzer VR.2.8 g3 (Sun Scientific, Tokyo, Japan) was used as analytical software, and stiffness values are presented in megapascals (MPa). Tofu, sliced cheese, ham, a plastic eraser and a stick of gum were selected as reference materials as they are common and recognizable items, and their stiffness is easy to imagine. These materials were cut into 1×1 -cm pieces, and the




Fig. 1. (a) Stiffness meter. (b) Special adaptor used to obtain the measurements (left: frontal view, right: oblique view).

stiffness of 20 samples of each material was measured to evaluate the reproducibility of the stiffness meter.

During CEA, carotid shunt insertion was performed in all patients, and the target plaques were excised *en bloc*. The excised plaques were examined, and the narrowest region on pre-operative carotid ultrasonography was identified and cut out as a 1×1 -cm specimen. The specimen was measured within 1 h of its excision using the stiffness meter installed in the operating room. A sample was placed on the lower platen, and the upper platen was moved to apply a small compressive pre-load of 0.1 N to the sample at a cross-head speed of 0.1 mm/s. Samples were fixed to the lower platen with the luminal and vascular wall sides up and down, respectively.

Comparison with clinical data

The presence or absence of underlying disease, findings on pre- or post-operative brain magnetic resonance imaging (MRI, 1.5 T, Excelart Vantage MRT-2003/P3, Toshiba Medical Systems) and the presence or absence of surgical complications were investigated in each patient. Digital subtraction angiography (AREX-VC830 A, Toshiba Medical Systems) was performed before surgery in all patients, and the rate of stenosis was measured using the North American Symptomatic Carotid Endarterectomy Trial (NASCET) method (Barnett et al. 1998; North American Symptomatic Carotid Endarterectomy Trial Collaborators 1991). These data were compared with the plaque stiffness measurements.

For statistical analysis, the Mann–Whitney *U*-test was used for comparisons of categorical data. For comparisons of numerical data, one-way analysis of variance (ANOVA) and the Kruskal–Wallis test were used. For comparisons among multiple groups, the Kruskal–Wallis test and multiple-comparison analysis (the Steel–Dwass method) were employed. *p* Values < 0.05 were regarded as indicating significance.

RESULTS

Stiffness values of foods and common items

The stiffness values of the five reference items increased in the order: tofu, sliced cheese, ham, plastic eraser and stick of gum (Fig. 2). The standard deviation of the measured values was small for all items, indicating the accuracy of the stiffness meter and its ability to obtain stable measurements.

Comparison between plaque stiffness and clinical findings

The results obtained for the 44 lesions are summarized in Table 1. The mean stiffness value for all plaques was 4.52 ± 3.30 MPa (mean \pm standard deviation). Three patients developed complications after surgery: cerebral infarctions in 2 patients (cases 2 and 20) and hyperperfusion-induced intracerebral hemorrhaging in

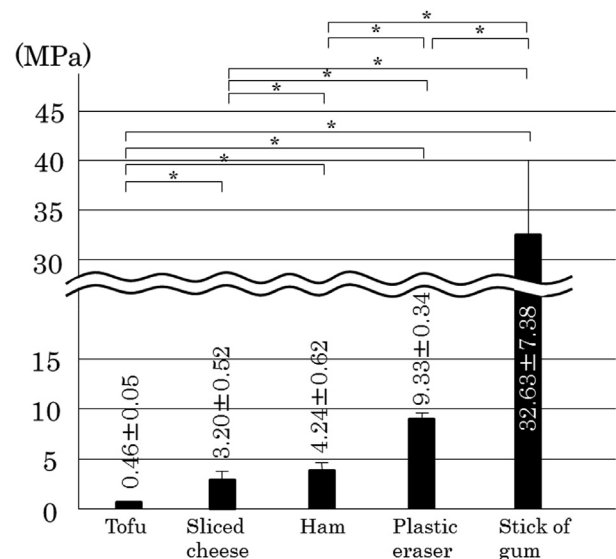


Fig. 2. Comparison of the stiffness values of selected foods and common daily items. **p* < 0.001

Table 1. Summary of cases

Case no.	Age/sex	Side	Symptoms	Stenotic rate (%)		Echo findings	Max IMT (mm)	Ulcer	Calcification	Complications	Stiffness (MPa)
				ECST	Area						
1	80/M	R	+	72	90	Low	4.6	+	–	–	0.13
2	40/M	L	+	78	81	Low	4.5	–	–	+	0.57
3	70/F	R	–	68	85	Iso	3.7	–	–	–	1.06
4	70/M	L	+	55	68	Low	3.8	+	–	–	1.07
5	62/M	R	–	57	74	Iso	4.3	+	–	–	1.25
6	67/M	L	–	56	43	Iso	2.8	–	+	–	1.25
7	76/M	L	+	76	81	Low	4.2	+	–	–	1.37
8	60/M	R	–	76	82	Iso	5.0	–	–	–	1.45
9	77/M	R	–	79	92	Low	5.7	+	–	–	1.48
10	77/M	R	–	60	74	Low	4.5	+	–	–	1.56
11	70/M	R	–	58	78	Low	5.6	–	–	–	1.56
12	75/M	R	–	69	78	Iso	3.9	–	–	–	1.94
13	73/M	L	–	45	69	Low	3.0	+	–	–	2.06
14	71/M	R	+	52	68	Iso	3.8	–	–	–	2.16
15	66/M	L	–	68	79	Iso	6.8	+	–	–	2.41
16	74/M	R	–	79	91	Low	3.9	–	–	–	2.66
17	67/M	R	+	55	60	High	4.7	–	+	–	2.76
18	78/M	L	–	60	83	Iso	6.3	–	–	–	2.84
19	69/M	R	+	77	93	Low	6.7	+	–	–	3.22
20	63/M	R	+	67	84	Low	5.8	+	–	+	3.42
21	78/M	R	–	66	83	Iso	4.6	–	–	–	3.57
22	66/M	L	+	74	84	Iso	4.4	–	+	+	3.62
23	51/M	L	+	74	93	Low	6.9	–	–	–	3.69
24	68/M	L	–	67	75	Iso	4.5	–	+	–	4.51
25	74/F	R	+	52	77	Low	3.5	–	–	–	4.66
26	65/M	L	+	69	91	Iso	6.0	–	–	–	4.70
27	76/M	R	+	67	81	Iso	5.7	+	+	–	5.07
28	63/M	R	–	80	87	Iso	5.6	+	–	–	5.13
29	77/M	R	+	67	87	Iso	3.3	+	+	–	5.33
30	69/M	R	–	79	96	High	4.7	–	+	–	5.40
31	75/M	R	–	59	66	Iso	4.2	+	–	–	5.57
32	71/M	R	+	78	92	Iso	7.4	+	–	–	5.61
33	70/M	L	+	67	72	Iso	5.4	+	–	–	5.80
34	70/M	L	–	60	84	Low	3.5	–	–	–	7.01
36	79/M	L	–	70	—	High	4.1	–	+	–	7.16
37	69/M	R	–	56	75	High	3.5	–	+	–	7.51
38	68/M	R	–	76	82	High	3.7	–	+	–	7.57
39	70/M	L	+	60	79	Iso	4.4	–	+	–	7.80
40	70/M	L	–	67	87	Iso	6.6	–	–	–	8.25
41	64/M	L	+	77	90	High	5.5	–	+	–	8.85
42	76/M	R	+	80	88	High	4.8	–	+	–	12.25
43	77/M	R	–	90	95	Iso	5.5	–	–	–	12.65
44	66/F	L	+	62	76	High	3.5	–	+	–	14.12

ECST = European Carotid Surgery Trial; max IMT = maximum intima–media thickness.

one (case 22). The mean stenotic rates on ultrasonography according to the ECST and area methods were $67.3 \pm 9.9\%$ and $80.3 \pm 10.7\%$, respectively, and the mean max IMT was 4.98 ± 1.86 mm. Comparison of the categorical data and plaque stiffness measurements revealed that the plaques that exhibited calcification were significantly harder than the other plaques ($p = 0.001$) (Table 2). The lesions were classified into low-echoic (15 lesions), iso-echoic (20 lesions) and high-echoic (9 lesions) groups based on their echographic findings, and the plaque stiffness values of the three groups were compared. Significant differences were noted among the groups, and a trend toward increasing plaque hardness from the low- to high-echoic groups was detected (Fig. 3).

None of the continuous variables, including age, pre-operative degree of stenosis (according to the NASCET, ECST and area methods) and max IMT exhibited significant correlations with plaque stiffness. It was not possible to evaluate stenosis using the area method in one patient (case 36) because of severe calcification.

DISCUSSION

To our knowledge, there have been two studies in which the physical properties of carotid plaque were quantitatively measured. *Stemper et al. (2005)* measured the tension of the carotid intima to elucidate the mechanism of intimal failure induced by blunt carotid artery

Table 2. Comparison between categorical factors and plaque stiffness

Factors	N	Stiffness		p value
		Mean	SD	
Sex				
Male	41	4.37	3.01	0.623
Female	3	6.62	6.74	
Side				
Right	25	4.20	3.20	0.467
Left	19	4.94	3.46	
Symptoms				
Present	21	4.91	3.60	0.453
Absent	23	4.16	3.04	
MRI (pre)				
Positive	33	4.68	3.60	0.839
Negative	11	4.03	2.21	
Ulcer				
Present	16	3.15	1.98	0.060
Absent	28	5.30	3.66	
Calcification				
Present	15	6.68	3.37	0.001
Absent	29	3.40	2.69	
Complications				
Present	3	2.54	3.27	0.274
Absent	41	4.66	3.35	
MRI (post)				
Positive	4	4.75	3.44	0.806
Negative	40	4.50	3.33	
Hypertension				
Present	41	4.57	3.27	0.592
Absent	3	3.83	4.36	
Diabetes mellitus				
Present	17	5.40	3.75	0.189
Absent	27	3.97	2.92	
Hyperlipidemia				
Present	27	4.66	2.88	0.392
Absent	17	4.30	3.96	

MRI = magnetic resonance imaging; SD = standard deviation.

injury. Maher et al. (2009) performed quantitative measurement using tensile and compressive tests in 14 cases of fresh plaque excised by CEA and compared the findings with the echo findings. They observed that calcified plaques were hard, and low-echoic plaques were soft, on the compressive test. On the compressive test of the 44 cases in our study, in addition to re-confirming the hardness of calcified plaques, significant differences were noted in stiffness among the low-, iso- and high-echoic groups, indicating that echo findings clearly reflect stiffness.

High consistency between the echo brightness and histopathologic findings is well known (Czernuszewicz et al. 2015). Low-echoic plaques are soft because these contain lipids and hematoma components; iso-echoic plaques comprise mainly fibrous component; and high-echoic plaques physically harden through calcification (Lee et al. 1992; Ohayon et al. 2008; Williamson et al. 2003). It is assumed that the correlation between the echo findings and plaque stiffness observed in our study reflected the pathologic findings.

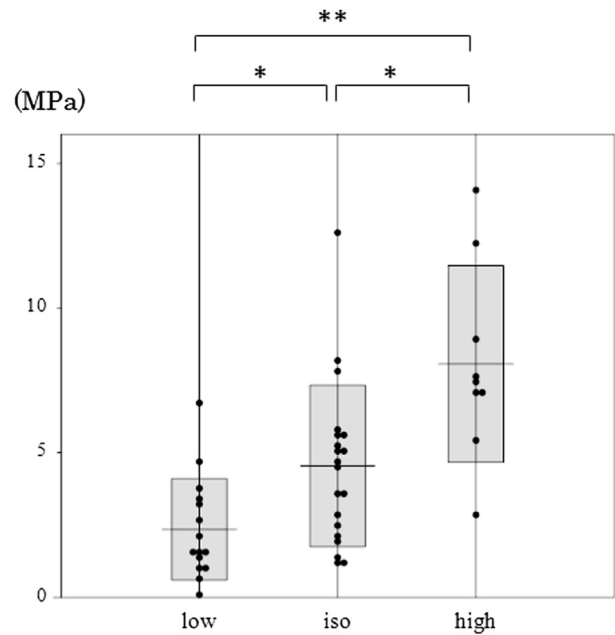


Fig. 3. Comparison of plaque stiffness among the low-, iso- and high-echoic groups. * $p < 0.05$. ** $p < 0.01$.

Neurosurgeons and vascular surgeons are aware that plaque stiffness strongly influences complications of CEA (Cantelmo et al. 1998; Crawley et al. 1997; Lennard et al. 1997; Mommertz et al. 2010). In soft plaques, there is a risk that vibration or retraction of the blood vessel during CEA may cause scattering of a part of the plaque to the periphery (Cantelmo et al. 1998; Lennard et al. 1997; Mommertz et al. 2010). In hard plaques with calcification, dissection of IMC may be difficult or cause perforation of the vascular wall. In our study, the effects of echo findings and stiffness of plaques on post-operative embolic complications could not be clarified, suggesting that the development of post-operative embolic complications is not simply determined by plaque stiffness alone, but various factors, such as the physical condition of the patient and surgical procedure, are involved in a complex manner. With respect to individual cases, plaques were not necessarily soft in 4 cases (cases 2, 20, 34 and 40) in which ischemic lesions were observed on post-operative diffusion-weighted imaging MRI. In contrast, in 2 cases (cases 2 and 20) in which symptomatic brain infarction occurred after surgery, plaque stiffness was 0.57 and 3.42, respectively, lower than the mean in this study, and the echo findings were low-echoic in both cases. For these cases, surgery should be very carefully performed.

These findings also apply to another treatment for carotid artery stenosis, CAS. In soft plaques, when percutaneous transluminal angioplasty (PTA) is performed before and after placing a stent, it causes cracks or

overextension of the intima, through which fat and thrombus in the plaque flow out and cause microembolisms (Castaneda-Zuniga *et al.* 1980; Crawley *et al.* 1997). It is also clear that hard plaque calcification is a risk factor of carotid stent fracture. In addition, the presence of calcification is involved in restenosis after CAS (Coppi *et al.* 2010). It was suggested that echography is an effective examination capable of predicting the risk of complications of CAS. It was clarified that specific prediction of plaque stiffness by operators before CEA and CAS may provide information useful in reducing post-operative complications.

For this purpose, plaque stiffness was compared with the stiffness of common daily items so that operators could imagine plaque stiffness. Stiffness was within the range 0.13–6.77 MPa; the mean was 2.35 in the group with pre-operative low-echoic plaque and was equivalent to the stiffness of tofu to sliced cheese. In the iso-echoic group, the mean was 4.55, close to that of ham. In the high-echoic group, the mean was 8.07, similar to that of a plastic eraser. Plaque stiffness may be specifically assumed based on the relationship among quantitative plaque stiffness, its echo findings and the stiffness data of foods and common items. Previously, prediction of plaque stiffness was dependent on the operator's experience, but the findings of this study may enable inexperienced operators to provide objective information.

CONCLUSIONS

We have reported that quantitative plaque stiffness measurements obtained with a stiffness meter are significantly correlated with echographic findings. By combining this finding with the data we provided on stiffness values of selected foods and common items, operators might be able to better understand the stiffness of a target plaque before treatment.

Acknowledgments—We thank Chiaki Nishimura, PhD, Professor Emeritus of Toho University, for helping us with the statistical processing.

REFERENCES

- Aburahma AF, Thiele SP, Wulu JT Jr. Prospective controlled study of the natural history of asymptomatic 60% to 69% carotid stenosis according to ultrasonic plaque morphology. *J Vasc Surg* 2002;36:437–442.
- Barnett HJ, Taylor DW, Eliasziw M, Fox AJ, Ferguson GG, Haynes RB, Rankin RN, Clagett GP, Hachinski VC, Sackett DL, Thorpe KE, Meldrum HE, Spence JD. Benefit of carotid endarterectomy in patients with symptomatic moderate or severe stenosis. North American Symptomatic Carotid Endarterectomy Trial Collaborators. *N Engl J Med* 1998;339:1415–1425.
- Cantelmo NL, Babikian VL, Samaraweera RN, Gordon JK, Pochay VE, Winter MR. Cerebral microembolism and ischemic changes associated with carotid endarterectomy. *J Vasc Surg* 1998;27:1024–1031.
- Cao JJ, Thach C, Manolio TA, Psaty BM, Kuller LH, Chaves PH, Polak JF, Sutton-Tyrell K, Herrington DM, Price TR, Cushman M. C-reactive protein, carotid intima-media thickness, and incidence of ischemic stroke in the elderly: The Cardiovascular Health Study. *Circulation* 2003;108:166–170.
- Castaneda-Zuniga WR, Formanek A, Tadavarthy M. The mechanism of balloon angioplasty. *Radiology* 1980;135:565–571.
- Coppi G, Moratto R, Veronesi J, Nicolosi E, Silingardi R. Carotid artery stent fracture identification and clinical relevance. *J Vasc Surg* 2010;51:1397–1405.
- Crawley F, Clifton A, Buckenham T, Loosemore T, Taylor RS, Brown MM. Comparison of hemodynamic cerebral ischemia and microembolic signals detected during carotid endarterectomy and carotid angioplasty. *Stroke* 1997;28:2460–2464.
- Czernuszewicz TJ, Homeister JW, Caughey MC, Farber MA, Fulton JJ, Ford PF, Marston WA, Vallabhaneni R, Nichols TC, Gallippi CM. Non-invasive in vivo characterization of human carotid plaques with acoustic radiation force impulse ultrasound: Comparison with histology after endarterectomy. *Ultrasound Med Biol* 2015;41:685–697.
- Davies MJ. The pathophysiology of acute coronary syndromes. *Heart* 2000;83:361–366.
- Diethrich EB, Ndiaye M, Reid DB. Stenting in the carotid artery: Initial experience in 110 patients. *J Endovasc Surg* 1996;3:42–62.
- Ederle J, Featherstone RL, Brown MM. Percutaneous transluminal angioplasty and stenting for carotid artery stenosis. *Cochrane Database Syst Rev* 2007;4:CD000515.
- Elatrozy T, Nicolaidis A, Tegos T, Zarka AZ, Griffin M, Sabetai M. The effect of B-mode ultrasonic image standardisation on the echodensity of symptomatic and asymptomatic carotid bifurcation plaques. *Int Angiol* 1998;17:179–186.
- European Carotid Surgery Trialists Collaborative Group. MRC European carotid surgery trial: interim results of symptomatic patients with severe (70–99%) or with mild (0–29%) stenosis. *Lancet* 1991;337:1235–1243.
- European Carotid Surgery Trialists Collaborative Group. Risk of stroke in the distribution of an asymptomatic carotid artery. *Lancet* 1995;345:209–212.
- European Carotid Surgery Trialists' Collaborative Group. Randomised trial of endarterectomy for recently symptomatic carotid stenosis: Final results of the MRC European Carotid Surgery Trial (ECST). *Lancet* 1998;351:1379–1387.
- Executive Committee for the Asymptomatic Carotid Atherosclerosis Study. Endarterectomy for asymptomatic carotid artery stenosis. *J Am Med Assoc* 1995;273:1421–1428.
- Grønholdt ML, Nordestgaard BG, Schroeder TV, Vorstrup S, Sillesen H. Ultrasonic echolucent carotid plaques predict future strokes. *Circulation* 2001;104:68–73.
- Gurm HS, Yadav JS, Fayad P, Katzen BT, Mishkel GJ, Bajwa TK, Ansel G, Strickman NE, Wang H, Cohen SA, Massaro JM, Cutlip DE. Long-term results of carotid stenting versus endarterectomy in high-risk patients. *N Engl J Med* 2008;358:1572–1579.
- Hobson RW II, Weiss DG, Fields WS, Goldstone J, Moore WS, Towne JB, Wright CB. Efficacy of carotid arterectomy for asymptomatic carotid stenosis. The Veterans Affairs Cooperative study group. *N Engl J Med* 1993;328:221–227.
- Inoue K, Matsumoto M, Shono T, Toyokawa S, Moriki A. Increased intima media thickness and atherosclerotic plaques in the carotid artery as risk factors for silent brain infarcts. *J Stroke Cerebrovasc Dis* 2007;16:14–20.
- Iwasaki M, Kuroda S, Yasuda H, Nakayama N, Saito H, Iwasaki Y. Natural course of carotid artery contralateral to carotid endarterectomy in Japan. *No Shinkei Geka* 2008;36:1103–1107.
- Javid M, Tylon C. Neurosurgical experience with carotid endarterectomy at University Hospitals (1954–1976). *Wis Med J* 1978;77:65–68.
- Lee RT, Richardson SG, Loree HM, Grodzinsky AJ, Gharib SA, Schoen FJ, Pandian N. Prediction of mechanical properties of human atherosclerotic tissue by high-frequency intravascular ultrasound imaging: An in vitro study. *Arterioscler Thromb* 1992;12:1–5.
- Lee W. General principles of carotid Doppler ultrasonography. *Ultrasonography* 2014;33:11–17.

- Lennard N, Smith J, Dumville J, Abbott R, Evans DH, London NJ, Bell PR, Naylor AR. Prevention of postoperative thrombotic stroke after carotid endarterectomy: The role of transcranial Doppler ultrasound. *J Vasc Surg* 1997;26:579–584.
- Maher E, Creane A, Sultan S, Hynes N, Lally C, Kelly DJ. Tensile and compressive properties of fresh human carotid atherosclerotic plaques. *J Biomech* 2009;42:2760–2767.
- Mayberg MR, Wilson SE, Yatsu F, Weiss DG, Messina L, Hershey LA, Colling C, Eskridge J, Deykin D, Winn HR. Carotid endarterectomy and prevention of cerebral ischemia in symptomatic carotid stenosis. Veterans Affairs Cooperative studies Program 309 Trialist Group. *JAMA* 1991;266:3289–3294.
- Molloy J, Markus HS. Asymptomatic embolization predicts stroke and TIA risk in patients with carotid artery stenosis. *Stroke* 1999;30:1440–1443.
- Mommertz G, Das M, Langer S, Koepfel TA, Krings T, Mess WH, Schiefer J, Jacobs MJ. Early control of distal internal carotid artery during carotid endarterectomy: Does it reduce cerebral microemboli? *J Cardiovasc Surg (Torino)* 2010;51:369–375.
- North American Symptomatic Carotid Endarterectomy Trial Collaborators. Beneficial effect of carotid endarterectomy in symptomatic patients with high-grade carotid stenosis. *N Engl J Med* 1991;325:445–453.
- Nowaczynski M, Sarzynska-Dlugosz I, Czlonkowska A. Prevalence of carotid arteries atherosclerotic changes in ischemic stroke patients. *Neurol Neurochir Pol* 2003;37:27–36.
- Ohayon J, Finet G, Gharib AM, Herzka DA, Tracqui P, Heroux J, Rioufol G, Kotys MS, Elagha A, Pettigrew RI. Necrotic core thickness and positive arterial remodeling index: Emergent biomechanical factors for evaluating the risk of plaque rupture. *Am J Physiol Heart Circ Physiol* 2008;295:H717–H727.
- O’Leary DH, Polak JF, Kronmal RA, Manolio TA, Burke GL, Wolfson SK Jr. Carotid-artery intima and media thickness as a risk factor for myocardial infarction and stroke in older adults. Cardiovascular Health Study Collaborative Research Group. *N Engl J Med* 1999;340:14–22.
- Rothwell PM, Gibson RJ, Slattery J, Warlow CP. Prognostic value and reproducibility of measurements of carotid stenosis: A comparison of three methods on 1001 angiograms. European Carotid Surgery Trialists’ Collaborative Group. *Stroke* 1994;25:2440–2444.
- Stemper BD, Yoganandan N, Pintar FA. Methodology to study intimal failure mechanics in human internal carotid arteries. *J Biomech* 2005;38:2491–2496.
- Verhoeven B, Hellings WE, Moll FL, de Vries JP, de Kleijn DP, de Bruin P, Busser E, Schoneveld AH, Pasterkamp G. Carotid atherosclerotic plaques in patients with transient ischemic attacks and stroke have unstable characteristics compared with plaques in asymptomatic and amaurosis fugax patients. *J Vasc Surg* 2005;42:1075–1081.
- Williamson SD, Lam Y, Younis HF, Huang H, Patel S, Kaazempur-Mofrad MR, Kamm RD. On the sensitivity of wall stresses in diseased arteries to variable material properties. *J Biomech Eng* 2003;125:147–155.
- Yadav JS, Wholey MH, Kuntz RE, Fayad P, Katzen BT, Mishkel GJ, Bajwa TK, Whitlow P, Strickman NE, Jaff MR, Popma JJ, Snead DB, Cutlip DE, Firth BG, Ouriel K. Protected carotid-artery stenting versus endarterectomy in high-risk patients. *N Engl J Med* 2004;351:1493–1501.
- Yuan C, Zhang SX, Polissar NL, Echelard D, Ortiz G, Davis JW, Ellington E, Ferguson MS, Hatsukami TS. Identification of fibrous cap rupture with magnetic resonance images is highly associated with recent transient ischemic attack or stroke. *Circulation* 2002;105:181–185.