

# 東邦大学学術リポジトリ



## OPAC

東邦大学メディアセンター

タイトル	Total Resection With Long Term Globe Preservation for Optic Pathway Glioma Case Report and Review of the Literature
作成者（著者）	Masuda, Hiroyuki / Kondo, Kosuke / Nemoto, Masaaki / Fukushima, Daisuke / Ando, Syunpei / Sugo, Nobuo / Harada, Naoyuki
公開者	The Medical Society of Toho University
発行日	2017.6
ISSN	21891990
掲載情報	Toho Journal of Medicine. 3(2). p.71 74.
資料種別	学術雑誌論文
内容記述	Case Report
著者版フラグ	publisher
JaLCDOI	info:doi/10.14994/tohojmed.2016.033
メタデータのURL	<a href="https://mylibrary.toho u.ac.jp/webopac/TD28626835">https://mylibrary.toho u.ac.jp/webopac/TD28626835</a>

**Case Report**

# Total Resection With Long-Term Globe Preservation for Optic Pathway Glioma

## Case Report and Review of the Literature

Hiroyuki Masuda\* Kosuke Kondo Masaaki Nemoto  
Daisuke Fukushima Syunpei Ando Nobuo Sugo  
and Naoyuki Harada

Department of Neurosurgery (Omori), School of Medicine, Faculty of Medicine, Toho University

---

**ABSTRACT:** We report a case of optic pathway glioma (OPG) treated by full resection with long-term globe preservation. A 3-year-old Asian boy with right exophthalmos and visual loss received a diagnosis of right intraorbital tumor at another hospital and was referred to our department. Magnetic resonance images showed a tumor localized from the intraorbital cavity to the optic nerve, without invasion of the globe or optic chiasm. The tumor was fully resected with the optic nerve, and the ophthalmic artery was preserved. After the operation, he was discharged with loss of vision and eye movement disorder but without other complications. The pathological diagnosis was pilocytic astrocytoma. Magnetic resonance images obtained 5 years after the operation confirmed the absence of tumor recurrence, preservation of globe form, and absence of enophthalmos and facial deformity. Total resection is associated with a good prognosis in patients with an anteriorly located optic pathway glioma, as was confirmed in the present case. For cosmetic and psychological reasons, surgical treatment for children should include globe preservation and maintenance of globe blood flow.

Toho J Med 3 (2): 71–74, 2017

---

**KEYWORDS:** optic pathway glioma, pilocytic astrocytoma, intraorbital tumor, globe preservation

Optic pathway glioma (OPG) is relatively rare, accounting for 2% to 5% of all brain tumors in children. Most OPGs develop in the first 10 years of life.<sup>1,2)</sup> About 70% of OPGs are classified as neurofibromatosis type 1, while others are sporadic.<sup>2)</sup> When OPGs develop in the chiasma or hypothalamus, surgical resection is limited,<sup>3)</sup> and chemotherapy or radiotherapy is often performed.<sup>4–6)</sup> In contrast, anteriorly located tumors localized from the intraorbital cavity to the optic nerve can be fully resected, unless they reach the chiasma, and long-term survival is likely.<sup>7)</sup> The cos-

metic outcomes of globe-preserving OPG have not been adequately studied.<sup>7–9)</sup> We describe a pediatric case of anteriorly located OPG treated by full resection with long-term globe preservation, and review the relevant literature.

### Case presentation

A 3-year-old Asian boy

Chief complaint: Right visual loss

Present illness: At age 1 year, the patient developed gradually progressive disturbance of lateral gaze and

---

6–11–1 Omorinishi, Ota, Tokyo 143–8541, Japan  
\*Corresponding Author: tel: +81–(0)3–3762–4151  
e-mail: h-masuda@med.toho-u.ac.jp  
DOI: 10.14994/tohojmed.2016.033

Received Nov. 29, 2016; Accepted Mar. 14, 2017  
Toho Journal of Medicine 3 (2), June 1, 2017.  
ISSN 2189–1990, CODEN: TJMOA2

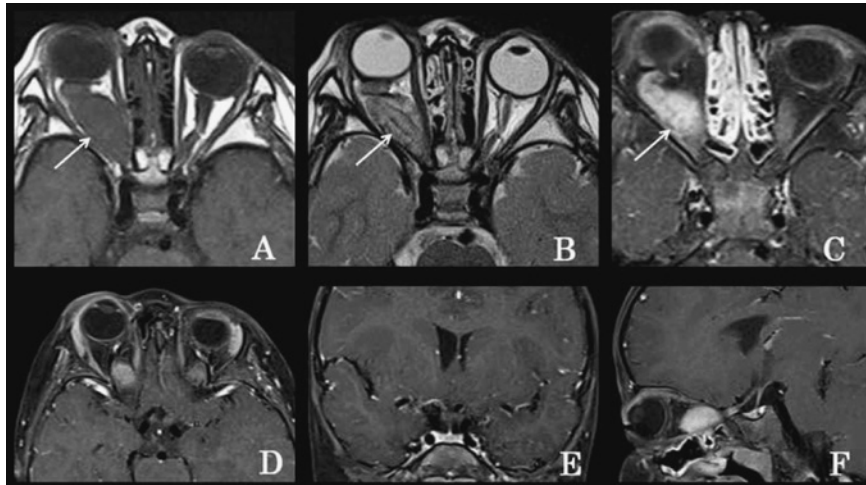


Fig. 1 Preoperative MRI scans

A: T1-weighted image, B: T2-weighted image, C: fat-suppressed T1-weighted image with gadolinium enhancement. The arrow indicates the intraorbital tumor. D: axial image at optic chiasm level (T1-weighted image with gadolinium enhancement), E: coronal image at optic chiasm level, F: sagittal image at optic chiasm level.

exophthalmos of the right eye. At age 3 years, his parents noticed right visual loss, and brought him to a local hospital for evaluation. Right intraorbital tumor was diagnosed, and he was referred to our department.

Past and family history: Unremarkable

Neurological findings: He was conscious and exhibited right exophthalmos, right eyelid swelling, and disturbance of right lateral gaze. Right visual acuity was limited to light perception.

Physical findings: There were no café au lait macules, skin neurofibroma, or Lisch nodule suggesting neurofibromatosis 1.

Imaging findings: Computed tomography (CT) showed an isodense tumor lesion with regular margins in the right orbital cavity. There was no acoustic tumor suggesting neurofibromatosis 2. T1- and T2-weighted magnetic resonance imaging (MRI) scans revealed an isointense tumor in the right muscle cone (Fig. 1A, B). On fat-suppressed T1-weighted images, the tumor was homogeneously visualized by gadolinium (Fig. 1C). MRI indicated that the tumor did not invade the optic chiasm (Fig. 1D, E, F).

Surgical findings: The intraorbital tumor was resected. After right frontotemporal craniotomy, anterior clinoidectomy was performed via the epidural space, for optic canal unroofing. In the orbital cavity, examination of the space between the levator muscle and lateral rectus muscle exposed a white glossy hard tumor (Fig. 2). There was no tu-

mor invasion of the globe. The globe and ophthalmic artery were preserved, and the tumor and intraorbital optic nerve were resected. In the intracranial cavity, the tumor was localized in the optic nerve anterior to the optic chiasm (Fig. 2). The optic nerve was cut and fully resected (Fig. 2C). The tumor was histopathologically diagnosed as a pilocytic astrocytoma. After the operation, exophthalmos improved, and he was discharged with blindness in the right eye and eye movement disorder but without neurological deficits. MRI scans obtained 5 years after the operation confirmed the absence of tumor recurrence, preservation of globe form, and absence of enophthalmos and facial deformity (Fig. 3).

## Discussion

The Dodge Classification is used to classify OPGs into 3 stages according to anatomical location: Stage 1 tumors involve only the optic nerves (Dodge I), Stage 2 tumors involve the chiasm, with or without nerve involvement (Dodge II), and Stage 3 tumors involve the hypothalamus or other adjacent structures (Dodge III).<sup>10,11</sup> OPG location is closely associated with clinical symptoms. Visual loss is often observed in patients with Dodge I tumors mainly located in the orbital cavity, exophthalmos, strabismus. Patients with Dodge II or III intracranial tumors tend to develop endocrine abnormalities in addition to visual loss.<sup>8</sup> Tumor location is also important in treatment planning.

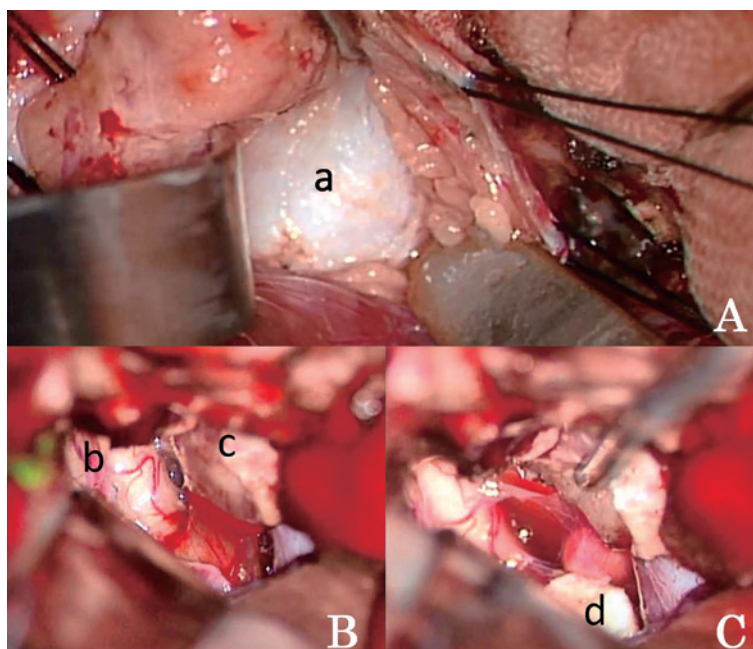


Fig. 2 Intraoperative photographs

A: intraorbital view. B: view of right frontotemporal craniotomy. C: view of right frontotemporal craniotomy after tumor resection.  
a: tumor, b: left optic nerve, c: right optic nerve and tumor, d: stump of the cut right optic nerve

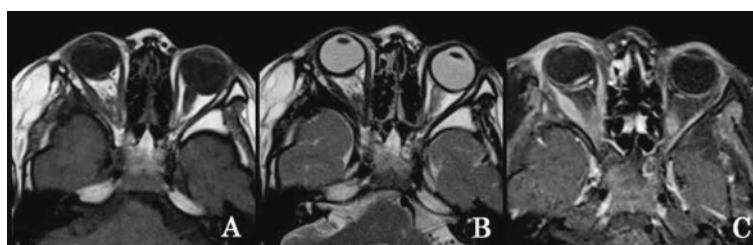

Fig. 3 Follow-up magnetic resonance imaging (MRI) scans 5 years after surgery

A: T1-weighted image, B: T2-weighted image, C: fat-suppressed T1-weighted image with gadolinium enhancement.

Surgery for Dodge III OPGs may injure the hypothalamus, visual apparatus, and vascular structures. Therefore, radical surgery is generally difficult, and chemotherapy or radiotherapy may be indicated.<sup>12)</sup> Anteriorly located Dodge I tumors localized in a single optic nerve require surgery in patients with progressive disfiguring proptosis or blindness.<sup>13)</sup> In a study of surgery for OPGs, 50 of 87 patients underwent surgery. The 10 patients (11%) who underwent total tumor resection had anteriorly located tumors localized in the optic nerve and a 10-year survival rate of 95%.<sup>6)</sup> Wright et al reported that among 9 patients who under-

went tumor resection for an anteriorly located tumor and macroscopically normal chiasm, the 6 patients with no evidence of pathological invasion of the chiasm did not experience recurrence.<sup>7)</sup> However, globe preservation in surgical tumor resection has not been adequately evaluated. Cosmetically, enucleation in children results in the long-term complications of enophthalmos and orbit deformation. Psychologically, it induces anxiety, stress, and depression and interferes with patients' future social participation.<sup>14)</sup> When artificial eyes are used in children, careful coping is necessary for growth-associated changes in the shape and size

of the eye socket.<sup>14)</sup> Because of these problems, active globe preservation is desirable in children with OPGs.

Previous studies of total resection for anteriorly located tumors reported that some patients required enucleation later. In a previous study of 9 patients with OPGs, 3 patients required enucleation during follow-up after total resection.<sup>7)</sup> One patient exhibited tumor growth into the vitreous and developed glaucoma. Another exhibited glioma growth from a small amount of residual tumor that remained attached to the posterior surface of the globe after the initial procedure. The other patient had multiple cystic recurrences of the tumor. Thus, tumor growth or recurrence required enucleation in all 3 patients. A case report described a 4-year-old boy who developed pain and severe photophobia due to postoperative globe ischemia and later required enucleation.<sup>9)</sup> In a study of 7 patients, enucleation was necessary for 2 patients. One developed corneal perforation due to marked proptosis caused by intraorbital tumor growth. The other developed tractional retinal detachment after the initial operation and required enucleation.<sup>8)</sup> These studies suggest that the major causes of enucleation are tumor growth or recurrence and globe ischemia. Our patient had a Dodge I anteriorly located tumor, which could be totally resected. In addition, ophthalmic artery blood flow could be preserved during surgery. These characteristics may explain why long-term globe preservation was possible.

### Conclusions

As in the present case, patients with anteriorly located OPGs are candidates for total resection and have a good prognosis. Because of its cosmetic and psychological benefits, surgery with active globe preservation and maintenance of globe blood flow is recommended for children.

**Funding:** None declared.

**Conflicts of interest:** None declared.

### References

- 1) Czyzyk E, Jóźwiak S, Roszkowski M, Schwartz RA. Optic pathway gliomas in children with and without neurofibromatosis 1. *J Child Neurol.* 2003; 18: 471-8.
- 2) Listernick R, Charrow J, Greenwald M, Mets M. Natural history of optic pathway tumors in children with neurofibromatosis type 1: a longitudinal study. *J Pediatr.* 1994; 125: 63-6.
- 3) El Beltagy MA, Reda M, Enayet A, Zaghoul MS, Awad M, Zekri W, et al. Treatment and outcome in 65 children with optic pathway gliomas. *World Neurosurg.* 2016; 89: 525-34.
- 4) Campagna M, Opocher E, Viscardi E, Calderone M, Severino SM, Cermakova I, et al. Optic pathway glioma: long-term visual outcome in children without neurofibromatosis type-1. *Pediatr Blood Cancer.* 2010; 55: 1083-8.
- 5) Doganis D, Pourtsidis A, Tsakiris K, Baka M, Kouri A, Bouhout-sou D, et al. Optic pathway glioma in children: 10 years of experience in a single institution. *Pediatr Hematol Oncol.* 2016; 33: 102-8.
- 6) Jenkin D, Angyalfi S, Becker L, Berry M, Buncic R, Chan H, et al. Optic glioma in children: surveillance, resection, or irradiation? *Int J Radiat Oncol Biol Phys.* 1993; 25: 215-25.
- 7) Wright JE, McNab AA, McDonald WI. Optic nerve glioma and the management of optic nerve tumours in the young. *Br J Ophthalmol.* 1989; 73: 967-74.
- 8) Kaufman LM, Doroftei O. Optic glioma warranting treatment in children. *Eye (Lond).* 2006; 20: 1149-64.
- 9) Loh CK, Weis B, van Velthoven V, Reiff C, Rössler J. Photophobia in a blind eye after removal of a progressive orbital optic glioma with denervation. *J Neurol Sci.* 2015; 358: 522-4.
- 10) Dodge HW Jr, Love JG, Craig WM, Dockerty MB, Kearns TP, Holman CB, et al. Gliomas of the optic nerves. *AMA Arch Neurol Psychiatry.* 1958; 79: 607-21.
- 11) Taylor T, Jaspan T, Milano G, Gregson R, Parker T, Ritzmann T, et al; PLAN Study Group. Radiological classification of optic pathway gliomas: experience of a modified functional classification system. *Br J Radiol.* 2008; 81: 761-6.
- 12) Sutton LN, Molloy PT, Sernyak H, Goldwein J, Phillips PL, Rorke LB, et al. Long-term outcome of hypothalamic/chiasmatic astrocytomas in children treated with conservative surgery. *J Neurosurg.* 1995; 83: 583-9.
- 13) Jahraus CD, Tarbell NJ. Optic pathway gliomas. *Pediatr Blood Cancer.* 2006; 46: 586-96.
- 14) Shaikh SR, Gangurde AP, Shambharkar VI. Changing ocular prostheses in growing children: a 5-year follow-up clinical report. *J Prosthet Dent.* 2014; 111: 346-8.