

Perioperative Monitoring of Serum p53 Antibody Titers in Japanese Women Undergoing Surgical Treatment After Neoadjuvant Chemotherapy for Locally Advanced Breast Cancer

Yorichika Kubota¹⁾ Hideaki Shimada^{1)*} Fumi Saito¹⁾
Tetsuo Nemoto²⁾ Hideaki Ogata¹⁾ and Hironori Kaneko¹⁾

¹⁾Division of General and Gastroenterological Surgery (Omori), Department of Surgery,
School of Medicine, Faculty of Medicine, Toho University

²⁾Department of Surgical Pathology (Omori), School of Medicine, Faculty of Medicine, Toho University

ABSTRACT

Background: The clinicopathological relevance of serum p53 antibodies (s-p53-Abs) in advanced breast cancer is not well understood. We evaluated the clinicopathological importance of s-p53-Abs titers in patients after surgical treatment and neoadjuvant chemotherapy for breast cancer.

Methods: We retrospectively analyzed the records of 43 consecutive female patients with primary locally advanced breast cancer who were surgically treated after neoadjuvant chemotherapy at Toho University Omori Medical Center between January 2010 and December 2014. S-p53-Abs, carcinoembryonic antigen (CEA), and cancer antigen (CA) 15-3 were assessed perioperatively, and the clinicopathological relevance of these tumor markers was analyzed.

Results: Eleven (26%) patients were s-p53-Abs – positive; however, s-p53-Abs status was not associated with any clinicopathological feature. Three of these 11 patients developed recurrence. The rate of positive test results for CEA and/or s-p53-Abs was significantly higher than that for CEA alone (44% vs 21%, respectively; $p = 0.04$). In addition, the positive rate for CA15-3 and/or s-p53-Abs was higher than that for CA15-3 alone (53% vs 33%, respectively; $p = 0.08$). The s-p53-Abs titer decreased in 10 of 11 (91%) patients after surgery and increased in 1 patient, who later developed brain metastasis. Seven patients with positive s-p53-Abs titers seroconverted and did not develop recurrence. In contrast, s-p53-Abs titers remained positive in 3 patients, 2 of whom developed brain metastases.

Conclusions: Perioperative monitoring of s-p53-Abs titers may be useful in detecting residual cancer cells. Extremely high s-p53-Abs titers suggest an increased risk of brain metastasis.

Toho J Med 3 (2): 58–65, 2017

KEYWORDS: serum p53 antibodies, locally advanced breast cancer, neoadjuvant chemotherapy, brain metastasis, perioperative monitoring

Genomic sequencing revealed that 20% to 30% of patients with breast cancer have p53 mutations.¹⁾ Most p53 mutations lead to synthesis of a stabilized mutant protein that has a much longer half-life than that of the wild-type p53 protein. Overexpression of mutant p53 protein induces production of serum p53 IgG antibodies (s-p53-Abs) in 18% to 34% of patients with breast cancer.²⁻¹⁰⁾ Previous studies enrolled from 24 to 153 patients, most of whom had early breast cancer. Because of the high sensitivity of s-p53-Abs testing, even among patients with early disease, the Japanese Ministry of Health, Labour and Welfare approved the use of s-p53-Abs as a tumor marker for breast cancer, in 2007.

We previously reported that monitoring of s-p53-Abs titers predicts tumor recurrence in patients with breast cancer, possibly because antibody response detects residual cancer cells.¹¹⁾ The presence of s-p53-Abs before treatment was associated with poor prognosis.⁶⁾ Because previous reports mainly enrolled patients with early breast cancer, the clinical relevance of s-p53-Abs in advanced breast cancer is not clear. Moreover, there is little information on the potential association of change in perioperative s-p53-Abs titer with treatment efficacy in advanced breast cancer. This study analyzed the clinical effects of pretreatment and perioperative changes in s-p53-Abs titers in patients with locally advanced breast carcinoma.

Methods

Patients

We retrospectively analyzed the medical records of 43 consecutive female patients with primary locally advanced breast cancer who were treated surgically after neoadjuvant chemotherapy at Toho University Omori Medical Center from January 2010 through December 2014. This study was approved by the relevant institutional review board (#21-93, #24-001, #26-256). Median age was 54 (range, 34 – 77) years. Male patients and patients with distant metastatic disease were excluded from the analysis. Eight patients had c-stage II disease, 33 had c-stage III disease, and 2 had occult disease. TNM classification was established by means of pathological examinations of preoperative needle biopsies, in accordance with the general guidelines for clinical and pathological recording of breast

cancer of the Japanese Breast Cancer Society.¹²⁾ Expression of human epidermal growth factor receptor 2 (HER2) was evaluated by core needle biopsy before starting neoadjuvant chemotherapy: 25 patients were HER2-positive and 18 were HER2-negative. After surgery, all patients underwent regular follow-up clinical examinations and imaging studies until the end of November 2016 or death. Postoperative recurrence was defined as positive findings on a clinical examination and ultrasonography or on computed tomography scanning, F-18-fluorodeoxyglucose positron-emission tomography, and magnetic resonance imaging.

Chemotherapy

All 25 HER2-positive patients were treated with 4 cycles of FEC100 (fluorouracil 500 mg/m², epirubicin 100 mg/m², and cyclophosphamide 500 mg/m²) every 3 weeks, followed by 4 cycles each of docetaxel (75 mg/m²) and trastuzumab (8 mg/kg for the first cycle and 6 mg/kg for the second to fourth cycles), every 3 weeks.¹³⁾

Some patients received paclitaxel, 80 mg/m² weekly, instead of docetaxel. Fifteen of the 18 HER2-negative patients were treated with FEC100, followed by docetaxel (one 75-mg/m² dose) or nab-paclitaxel (260 mg/m²). Three HER2-negative patients were treated with 6 cycles of nab-paclitaxel (130 mg/m²) and gemcitabine (1200 mg/m²) twice every 3 weeks.

Serum samples and enzyme immunoassay for s-p53-Abs, carcinoembryonic antigen, and cancer antigen 15-3

Serum samples were analyzed before and after chemotherapy and after surgery. The s-p53-Abs titer was assessed with a highly specific and quantitative p53 Abs ELISA kit (MESACUP™ anti-p53 Test; Medical & Biological Laboratories Co. Ltd., Nagoya, Japan).⁴⁾ We first evaluated the clinical effects of s-p53-Abs titer on the whole patient sample. Then, in subgroup analysis we analyzed seropositive patients and evaluated the prognostic impact of change in s-p53-Abs titer as a continuous variable. The cutoff value for s-p53-Abs was 1.3 U/ml. Carcinoembryonic antigen (CEA) concentrations were measured with the CEA-2 EIA kit (Elecsys CEAI, Roche Diagnostics K.K., Tokyo, Japan). The cutoff value for serum CEA was 5.0 ng/ml, in accordance with the manufacturer's recommen-

dations. Cancer antigen (CA) 15-3 concentration was measured with the CA15-3-2 EIA kit (Roche Diagnostics K.K.). The cutoff value for serum CA15-3 was 25.0 U/ml, in accordance with the manufacturer's recommendations.

Assessment of pathological response to neoadjuvant chemotherapy

The Response Assessment of Chemotherapy for Breast Carcinoma, proposed in the Japanese Classification of Breast Cancer,¹²⁾ was used to assess response in surgically resected specimens. Pathological effects were categorized into 6 groups (grade 0, 1a, 1b, 2a, 2b, and 3) based on morphological changes and the extent or absence of invasive cancer. Grade 1a was defined as "mild changes in cancer cells, regardless of the extent, and/or marked changes in <1/3 of the tumor." Grade 1b was defined as "marked changes in 1/3 to <2/3 of the tumor." Grade 2a was defined as "marked changes in $\geq 2/3$ of the tumor, but apparent remaining cancer cells." Grade 2b was defined as "marked changes approaching a complete response with only a few remaining cancer cells." The Japanese Classification of Breast Cancer defines "grade 3" as "no invasive cancer in the breast," which is equivalent to a "pathological complete response" in the National Surgical Adjuvant Breast and Bowel Project B-18 study. The presence of non-invasive cancer in the breast and nodal involvement in such cases was clearly noted.

Immunohistochemical staining for p53 and Ki-67

Paraffin-embedded tissue blocks of 3 formalin-fixed biopsy specimens from different areas of the tumor were cut into 4-mm-thick sections, deparaffinized in xylene, and dehydrated with graded alcohol concentrations. Hematoxylin and eosin (H&E) staining and immunostaining by the avidin-biotin-peroxidase method were performed. p53 protein overexpression was detected by anti-p53 monoclonal antibody (DO-7, 1:200, DAKO, Carpinteria, CA, USA). Ki-67 immunostaining was performed with a mouse monoclonal antibody (MIB-1, 1:200, DAKO, Glostrup, Denmark). Immunostaining was performed by using a BenchMark XT auto-stainer (Ventana Medical Systems Inc., Tucson, AZ, USA) according to the manufacturer's instructions. Ki-67 evaluation was performed by using a previously described method.¹⁴⁾ High Ki-67 expression was defined as a cutoff value of $\geq 14\%$ of tumor tissue.¹⁵⁾

Statistical analysis

Data are expressed as mean \pm standard deviation. Groups were compared with the Fisher exact test and unpaired t test. A *p* value of less than 0.05 was considered to

indicate statistical significance. All statistical analyses were performed by using Easy R (EZR) for Windows (32-bit version; Jichi Medical University, Shimotsuke, Tochigi, Japan).

Compliance with ethical standards

Ethics statement: This study was approved by the institutional review boards of the Chiba Cancer Center (#21-26) and Toho University School of Medicine (#22-112, #22-047). Additional informed consent was obtained from all patients for whom identifying information is included in this article.

Results

The associations of s-p53-Abs with preoperative clinicopathological features are shown in Table 1. Eleven (26%) patients were s-p53-Abs – positive; s-p53-Abs status was not associated with age, family history, tumor size, lymph node metastasis, estrogen receptor status, progesterone receptor status, HER2 status, presence of triple-negative (estrogen receptor – negative, progesterone receptor – negative, and HER2-negative) cancer, MIB-1 status, or conventional tumor markers. Patients with triple-negative tumors were more likely than other patients to be positive for s-p53-Abs, but the difference was not significant (27% vs 6%, respectively; *p* = 0.10).

Fig. 1 shows the rates of positive results for s-p53-Abs and conventional tumor markers. The overall positive rates were comparable for the 3 markers (s-p53-Abs, 26%; CEA, 21%; CA15-3, 33%). Assays that combined s-p53-Abs with a conventional tumor marker had better sensitivity. The rate of positive results for CEA and/or s-p53-Abs was significantly higher than that for CEA alone (44% vs 21%, respectively; *p* = 0.04). The positive rate for CA15-3 and/or s-p53-Abs was higher than that for CA15-3 alone (53% vs 33%, respectively; *p* = 0.08). Moreover, the positive rate for CEA and/or CA15-3 and/or s-p53-Abs was higher than that for CEA and/or CA15-3 (58% vs 37%, respectively; *p* = 0.08). The rates of positive test results for s-p53-Abs and conventional tumor markers are shown in Fig. 2. S-p53-Abs status was independent of the other 2 conventional tumor markers.

Fig. 3 shows s-p53-Abs titers in s-p53-Abs – positive patients before and after treatment. S-p53-Abs titers decreased in 10 of 11 patients after surgery and increased in 1 patient (Case 1), a 51-year-old woman with an axillary tumor who developed brain metastasis 23 days after surgery and died of the disease 120 days after surgery. Changes in

Table 1 Associations of s-p53-Abs status with preoperative clinicopathological characteristics

		s-p53-Abs-positive (n = 11)	s-p53-Abs-negative (n = 32)	p-Value ^c
Age (years)		51.5 ± 11.0	55.6 ± 10.7	0.28
Family history	Negative	10	26	0.66
	Positive	1	6	
T factor	Tx ^b , T1, T2	7	13	0.3
	T3, T4	4	19	
Lymph node metastasis	Negative	0	1	1
	Positive	11	31	
Estrogen receptor	Negative	5	9	0.46
	Positive	6	23	
Progesterone receptor	Negative	6	13	0.5
	Positive	5	19	
HER2	Negative	6	12	0.48
	Positive	5	20	
Triple negative	No	8	30	0.1
	Yes	3	2	
MIB-1 (%) ^a	<14.0	1	4	0.63
	≥14.0	8	13	
CEA	Negative	10	24	0.41
	Positive	1	8	
CA15-3	Negative	9	20	0.29
	Positive	2	12	
CEA + CA15-3	Negative	9	18	0.17
	Positive	2	14	

a. MIB-1 expression was analyzed after June 2013.

b. Tx, occult cancer with axillary lymph node metastases.

c. Fisher exact test and unpaired *t* test.

s-p53-Abs: serum p53 antibodies, CEA: carcinoembryonic antigen, CA15-3: cancer antigen 15-3

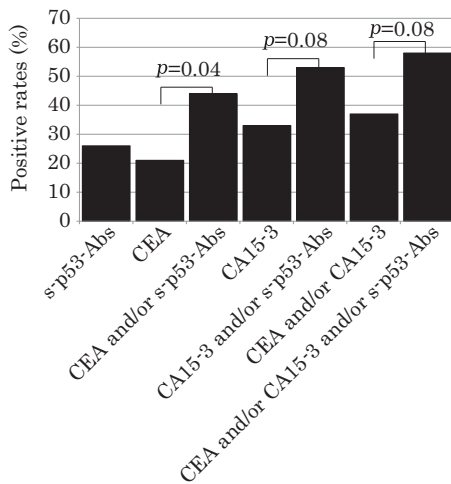


Fig. 1 Comparison of rates of positive results for serum tumor markers in patients with breast cancer.

S-p53-Abs: serum p53 antibodies, CEA: carcinoembryonic antigen, CA15-3: cancer antigen 15-3

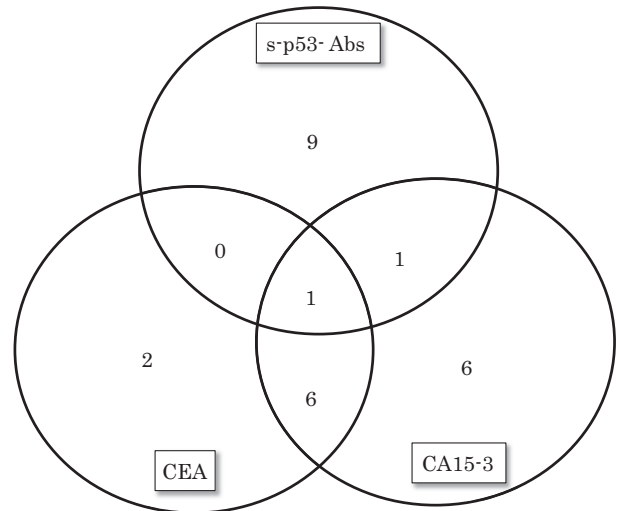


Fig. 2 Number of positive results for serum tumor markers in patients with breast cancer.

s-p53-Abs: serum p53 antibodies, CEA: carcinoembryonic antigen, CA15-3: cancer antigen 15-3

serum markers for the entire clinical course of this patient are shown in Fig. 4. Ultrasonography revealed swollen axillary lymph nodes, but mammography and ultrasonography showed no evidence of abnormal breast findings. The s-p53-Abs titer before treatment was 531 U/ml, but the re-

sults of CEA and CA15-3 testing were negative. Histological analysis of an excisional biopsy from an axillary tumor revealed metastatic breast cancer. After chemotherapy, her serum s-p53-Abs titer decreased to 20.3 U/ml, at which point axillary lymph node dissection was performed. Approximately 3 weeks after lymph node dissection, her serum titer increased to 25.8 U/ml and the patient began to complain of dizziness. Brain metastasis was detected by magnetic resonance imaging, but the results of CA15-3 and CEA testing remained negative. She underwent radiotherapy and chemotherapy, but the brain metastasis progressed rapidly, and she died 4 months after surgery.

The associations of s-p53-Abs status with pathological response and tumor recurrence are shown in Table 2. A pathological complete response was attained in 4 (9%) of 43 patients: 2 (18%; Cases 2 and 3) of 11 s-p53-Abs - positive patients and 2 (6%) of 32 s-p53-Abs - negative patients. Three of the 4 patients survived without recurrence. One of the 4 patients (Case 2) developed brain metastasis. There was no significant difference in recurrence rate between groups. Pretreatment hormone receptor expression patterns in the 4 patients with a complete response to neoadjuvant chemotherapy are shown in Table 3. One of

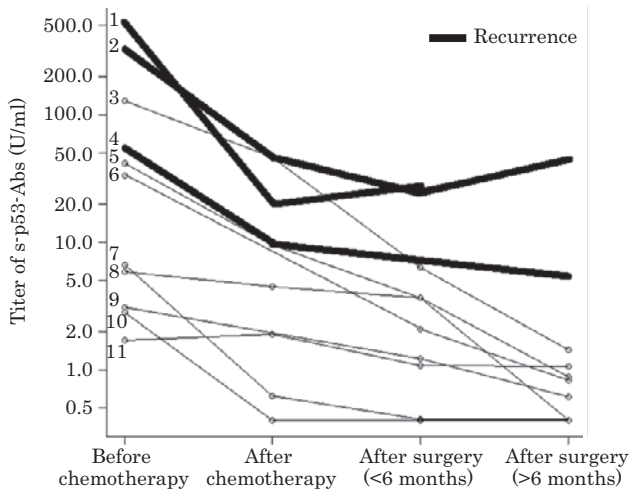


Fig. 3 Changes in serum p53 antibody titers of s-p53-Abs-positive patients before and after treatment. Patient 1 died 4 months after surgery, and Patient 4 died 2.5 years after surgery.

s-p53-Abs: serum p53 antibodies

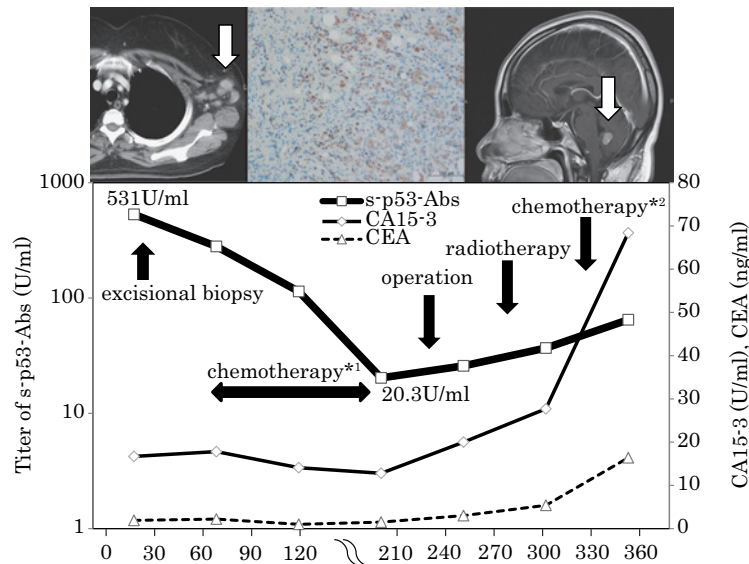


Fig. 4 Change in serum p53 antibody titers in 1 patient with recurrence. She died 4 months after surgery.

*1 Nab-paclitaxel 130 mg/m² iv + gemcitabine 1200 mg/m² iv, twice every 3 weeks for 6 cycles

*2 Epirubicin 60 mg/m² iv + cyclophosphamide 500 mg/m² iv + fluorouracil 500 mg/m² iv, once every 3 weeks for 4 cycles

s-p53-Abs: serum p53 antibodies, CEA: carcinoembryonic antigen, CA15-3: cancer antigen 15-3, iv: intravenous administer

Table 2 Associations of serum p53 antibody status with pathological response and tumor recurrence.

		s-p53-Abs-positive (n = 11)	s-p53-Abs-negative (n = 32)	p-Value ^a
Pathological response	Grade 1/2	9	30	0.27
	Grade 3	2	2	
Recurrence	Negative	8	21	1
	Positive	3	11	

a. Fisher exact test

s-p53-Abs: serum p53 antibodies

Table 3 Pretreatment hormone receptor expression in patients with complete pathological response to neoadjuvant chemotherapy

Case	s-p53-Abs	ER	PgR	HER2	Ki67	Chemotherapy regimen
A (Case 2)	Positive	Positive	Positive	Positive	30%	(i) Epirubicin + cyclophosphamide + fluorouracil (ii) Docetaxel + trastuzumab
B (Case 3)	Positive	Negative	Negative	Negative	39%	Nab-paclitaxel + gemcitabine
C	Negative	Negative	Negative	Positive	50%	(i) Epirubicin + cyclophosphamide + fluorouracil (ii) Docetaxel + trastuzumab
D	Negative	Positive	Negative	Positive	NA	(i) Epirubicin + cyclophosphamide + fluorouracil (ii) Docetaxel + trastuzumab

s-p53-Abs: serum p53 antibody, ER: estrogen receptor, PgR: progesterone receptor, HER2: human epidermal receptor 2, NA: not applicable

the 2 s-p53-Abs – positive patients was HER2-positive. Both s-p53-Abs – negative patients were positive for HER2. There was no significant association between s-p53-Abs status and hormone status.

Discussion

The rate of positive results was significantly higher for CEA combined with s-p53-Abs than for CEA alone. Thus, inclusion of s-p53-Abs status improved sensitivity for detection of breast cancer. Eleven of 32 s-p53-Abs – negative patients and 3 of 11 s-p53-Abs – positive patients developed recurrence. Because all 3 of these patients had positive results only for s-p53-Abs, adding s-p53-Abs could improve quality of follow-up. A previous study reported significant association of s-p53-Abs status with family history, triple-negative cancer, and estrogen receptor status³; however, s-p53-Abs status was not associated with any clinicopathological feature in the present study. A previous report found that patients with triple-negative breast cancer were more likely than other breast cancer patients to be s-p53-Abs – positive.⁷ This trend was also observed in the present study. The s-p53-Abs seropositivity rate was

slightly higher in patients with triple-negative tumors than in other patients, but the difference was of borderline significance, possibly because of the small number of patients at our center. s-p53-Abs status was significantly associated with survival in one study⁶ but not in another study.⁸

In our previous study of patients with esophageal carcinoma, high s-p53-Abs titers (≥ 10 U/ml) were associated with advanced cancer and poor outcomes.¹⁶ In the present study s-p53-Abs status was not associated with outcome, but 3 of the 6 patients in the high s-p53-Abs titer group (≥ 10 U/ml) developed recurrence. The 3 patients with recurrence (Cases 1, 2, and 4) had extremely high pretreatment titers (≥ 50 U/ml) and developed brain metastases. Although patients who achieved a pathological complete response continue to have significantly better rates of disease-free survival and overall survival, as compared with patients who did not,¹⁷ Case 2 developed brain metastasis. None of the 11 s-p53-Abs – negative patients with recurrent cancer developed brain metastases as the first recurrent lesion. The association between s-p53-Abs status and brain metastasis was statistically significant ($p=0.003$).

An association between p53 status and brain metastases from breast cancer was previously reported.¹⁸⁻²⁰⁾ Seropositive patients may thus be at higher risk for brain metastases, even after radical surgery.

In our previous case study, we reported that monitoring of s-p53-Abs was useful in predicting tumor recurrence in patients with advanced breast cancer, possibly because antibody response detects residual cancer cells.¹¹⁾ Similarly, residual cancer cells might have been detected during monitoring of s-p53-Abs during treatment in Case 1. Her s-p53-Abs titer was consistently positive, even after radical surgery. Because the results of testing for all other conventional tumor markers were negative in this patient, s-p53-Abs was helpful in assessing tumor burden.

Although p53 protein overexpression was previously found to be related to chemosensitivity,²¹⁾ s-p53-Abs status was not associated with pathological response or tumor recurrence in our present series. This discrepancy is attributable, in part, to differences in chemotherapy regimens and the small sample size. The relation between s-p53-Abs status and treatment response should be examined in a large-scale multicenter prospective study.

In conclusion, s-p53-Abs testing might be useful for detecting residual cancer cells in patients receiving treatment for locally advanced breast cancer.

This research was partly supported by a Grant in-Aid for Scientific Research (Nos. 24591961 and 21591717) from the Ministry of Education, Culture, Sports, Science and Technology of Japan.

Conflicts of interest: Hideaki Shimada received research grants from Medical & Biological Laboratories Co., Ltd., Nagoya, Japan. The other authors have no conflicts of interest to declare.

References

- 1) Fountzilias G, Giannoulatou E, Alexopoulou Z, Zagouri F, Timotheadou E, Papadopoulou K, et al. TP53 mutations and protein immunopositivity may predict for poor outcome but also for trastuzumab benefit in patients with early breast cancer treated in the adjuvant setting. *Oncotarget*. 2016; 7: 32731-53.
- 2) Shimada H, Ochiai T, Nomura F; Japan p53 Antibody Research Group. Titration of serum p53 antibodies in 1,085 patients with various types of malignant tumors: a multiinstitutional analysis by the Japan p53 Antibody Research Group. *Cancer*. 2003; 97: 682-9.
- 3) Yamamoto S, Chishima T, Adachi S, Harada F, Toda Y, Arioka H, et al. Serum p53 antibody in breast cancer. *Cancer Biomark*. 2014; 14: 203-6.
- 4) Müller M, Meyer M, Schilling T, Ulsperger E, Lehnert T, Zentgraf H, et al. Testing for anti-p53 antibodies increases the diagnostic sensitivity of conventional tumor markers. *Int J Oncol*. 2006; 29: 973-80.
- 5) Regele S, Kohlberger P, Vogl FD, Böhm W, Kreienberg R, Runnebaum IB. Serum p53 autoantibodies in patients with minimal lesions of ductal carcinoma in situ of the breast. *Br J Cancer*. 1999; 81: 702-4.
- 6) Kulić A, Sirotković-Skerlev M, Jelisivac-Cosić S, Herceg D, Kovac Z, Vrbanc D. Anti-p53 antibodies in serum: relationship to tumor biology and prognosis of breast cancer patients. *Med Oncol*. 2010; 27: 887-93.
- 7) Nozoe T, Mori E, Kono M, Iguchi T, Maeda T, Matsukuma A, et al. Serum appearance of anti-p53 antibody in triple negative breast cancer. *Breast Cancer*. 2012; 19: 11-5.
- 8) Willsher PC, Pinder SE, Robertson L, Nicholson RI, Ellis IO, Bell JA, et al. The significance of p53 autoantibodies in the serum of patients with breast cancer. *Anticancer Res*. 1996; 16: 927-30.
- 9) Schummer M, Thorpe J, Giraldez MD, Bergan L, Tewari M, Urban N. Evaluating serum markers for hormone receptor-negative breast cancer. *PLoS One*. 2015; 10: e0142911.
- 10) Lacombe J, Mangé A, Bougnoux AC, Prassas I, Solassol J. A multiparametric serum marker panel as a complementary test to mammography for the diagnosis of node-negative early-stage breast cancer and DCIS in young women. *Cancer Epidemiol Biomarkers Prev*. 2014; 23: 1834-42.
- 11) Kubota Y, Shimada H, Magoshi S, Saito F, Osaku T, Nemoto T, et al. Serum p53 antibody is a useful biomarker for long-term monitoring of breast cancer: Report of a recurrent case after surgery. *Toho J Med*. 2016; 2: 22-5.
- 12) The Japanese Breast Cancer Society (Ed) General rules for clinical and pathological recording of breast cancer 17th ed, Tokyo: Kanehara; 2012. p. 106.
- 13) Valachis A, Mauri D, Polyzos NP, Chlouverakis G, Mavroudis D, Georgoulas V. Trastuzumab combined to neoadjuvant chemotherapy in patients with HER2-positive breast cancer: a systematic review and meta-analysis. *Breast*. 2011; 20: 485-90.
- 14) Dowsett M, Nielsen TO, A'Hern R, Bartlett J, Coombes RC, Cuzick J, et al; International Ki-67 in Breast Cancer Working Group. Assessment of Ki67 in breast cancer: recommendations from the International Ki67 in Breast Cancer Working group. *J Natl Cancer Inst*. 2011; 103: 1656-64.
- 15) Goldhirsch A, Wood WC, Coates AS, Gelber RD, Thürlimann B, Senn HJ, et al. Strategies for subtypes—dealing with the diversity of breast cancer: highlights of the St Gallen International Expert Consensus on the Primary Therapy of Early Breast Cancer 2011. *Ann Oncol*. 2011; 22: 1736-47.
- 16) Shimada H, Nabeya Y, Okazumi S, Matsubara H, Funami Y, Shiratori T, et al. Prognostic significance of serum p53 antibody in patients with esophageal squamous cell carcinoma. *Surgery*. 2002; 132: 41-7.
- 17) Rastogi P, Anderson SJ, Bear HD, Geyer CE, Kahlenberg MS, Robidoux A, et al. Preoperative chemotherapy: updates of National Surgical Adjuvant Breast and Bowel Project Protocols B-18 and B-27. *J Clin Oncol*. 2008; 26: 778-85.
- 18) Chang J, Clark GM, Allred DC, Mohsin S, Chamness G, Elledge RM. Survival of patients with metastatic breast carcinoma: importance of prognostic markers of the primary tumor. *Cancer*. 2003; 97: 545-53.
- 19) Lo Nigro C, Vivenza D, Monteverde M, Lattanzio L, Gojis O, Garrone O, et al. High frequency of complex TP53 mutations in CNS

- metastases from breast cancer. *Br J Cancer*. 2012; 106: 397-404.
- 20) Arnold SM, Young AB, Munn RK, Patchell RA, Nanayakkara N, Markesbery WR. Expression of p53, bcl-2, E-cadherin, matrix metalloproteinase-9, and tissue inhibitor of metalloproteinases-1 in paired primary tumors and brain metastasis. *Clin Cancer Res*. 1999; 5: 4028-33.
- 21) Kim T, Han W, Kim MK, Lee JW, Kim J, Ahn SK, et al. Predictive significance of p53, Ki-67, and Bcl-2 expression for pathologic complete response after neoadjuvant chemotherapy for triple-negative breast cancer. *J Breast Cancer*. 2015; 18: 16-21.