

東邦大学学術リポジトリ



OPAC

東邦大学メディアセンター

タイトル	Effectiveness of laparoscopic subtotal cholecystectomy: Perioperative and long term postoperative results
別タイトル	周術期および長期成績からみた腹腔鏡下胆嚢亜全摘術の有用性
作成者(著者)	田村, 晃
公開者	東邦大学
発行日	2014.01
掲載情報	東邦大学大学院医学研究科 博士論文. 3.
資料種別	学位論文
内容記述	主査: 五十嵐良典 / タイトル: Effectiveness of laparoscopic subtotal cholecystectomy: Perioperative and long term postoperative results / 著者: Akira Tamura, Jun Ishii, Toshio Katagiri, Tetsuya Maeda, Yoshihisa Kubota, Hironori Kaneko / 掲載誌: Hepato Gastroenterology / 巻号・発行年等: 60 (126):1280-1283, 2013 / 本文ファイル: 査読後原稿
著者版フラグ	ETD
報告番号	32661乙第2804号
学位授与年月日	2014.1.23
学位授与機関	東邦大学
DOI	info:doi/10.5754/hge13094
メタデータのURL	https://mylibrary.toho-u.ac.jp/webopac/TD14303856

タイトル：

Effectiveness of laparoscopic subtotal cholecystectomy: Perioperative and long - term postoperative results

著者：

Akira Tamura, Jun Ishii, Toshio Katagiri, Tetsuya Maeda, Yoshihisa Kubota, Hironori Kaneko

掲載誌：

Hepato-Gastroenterology

巻号・発行年等：

60 (126) : 1280-1283, 2013

URL：

<http://rep.toho-u.ac.jp/modules/xoonips/detail.php?id=14303856>

INTRODUCTION

Laparoscopic cholecystectomy (LC) is now widespread and has become the gold standard treatment for patients requiring cholecystectomy. However, LC is sometimes dangerous in cases of severe cholecystitis. Surgeons must leave some gallbladder tissue in situ. Thus, laparoscopic subtotal cholecystectomy (LSC) remains an option in patients with severe inflammation. There is no universally accepted definition of LSC; however, Palanivelu et al (1) proposed a 3-group classification scheme based on inflammation severity. We utilized this scheme to classify patients who underwent LSC at our center into 3 subgroups. To evaluate the utility of LSC, we compared the perioperative and long-term results for LSC patients and subgroups with those for patients who underwent standard LC.

METHODOLOGY

Patients

LC is usually indicated in cases of cholecystitis accompanied by gallstones, asymptomatic gallstones, polyps or tumors in the gallbladder. We retrospectively analyzed data from 760 patents who underwent LC (including 89 LSC cases) at our center between January 2004 and December 2010.

Laparoscopic procedures

In our center, LC was performed with standard 4-port (one 12-mm and three 5-mm ports) technique, with carbon dioxide providing a constant pneumoperitoneal pressure of 10 mm Hg. As a rule, the operation was done by interns or residents (of which our center has 62 in total) who receive guidance throughout the procedure by 4 experienced supervising surgeons.

LC involves first exposing Calot's triangle, determining the locations of the cystic duct and cystic artery, and exposing them. However, before transacting the cystic duct and cystic artery, the liver bed is detached from the base of the gallbladder, after which the cystic duct can be isolated. Excision of the gallbladder is usually done with an electric hook-shaped scalpel, although laparoscopic coagulating shears can also be used. During these procedures, intraoperative cholangiography is routinely applied when possible in LSC and standard LC to confirm the location of the cystic duct, avoid the bile duct injury, and identify any remaining calculi. In addition, after removal of the gallbladder, postoperative intraperitoneal lavage is done with 2 to 3 L of warm saline solution. A drain is not usually inserted.

Laparoscopic subtotal cholecystectomy-I (LSC-I) was performed by leaving the posterior wall intact with the liver. The front wall of the gallbladder was first excised, and the remnant

mucosa was removed by mucosectomy. Then, the cystic duct was clipped or endolooped.

Laparoscopic subtotal cholecystectomy-II (LSC-II) was performed when inflammation in Calot's triangle was severe and the cystic duct could not be exposed. The infundibulum was divided circumferentially as close as was safely possible to the junction of the gallbladder and cystic duct. Then, the flap was closed with an autosuture device or endoloop.

Laparoscopic subtotal cholecystectomy-III (LSC-III) was performed for considerably severe cholecystitis. The gallbladder was separated from the liver, leaving its posterior wall intact on the liver bed. Then, because it was not able to exposed Calot's triangle, the gallbladder wall margin was closed by suture. Due to the difficulty of LSC-III, drainage was inserted to avoid possible complications from bile leakage.

Patients who underwent LSC-II and LSC-III were monitored by ultrasonography, computed tomography, or magnetic resonance imaging, after the procedure.

Outcomes investigated

The outcomes compared included perioperative variables such as operative time, volume of blood loss, postoperative clinical findings of inflammation (as indicated by white blood cell count [WBC] and C-reactive protein [CRP] on postoperative days 1 and 3), highest postoperative body temperature, number of postoperative hospitalization days, and presence of early complications. The results from LSC cases were compared with those from 671 standard LC (s-LC) cases done during the same period. The LSC cases were subdivided into LSC-I, LSC-II, and LSC-III cases, which were then each compared with s-LC cases.

The rate of intraoperative conversion to open laparotomy and incidence of bile duct injury

were compared between 415 cases of LC performed before the introduction of LSC (1992–2001) and after the introduction of LSC (774 cases, 2004–2010). Long-term results for LSC were also investigated, including recurrence of gallstones and development of gallbladder cancer. All comparisons were done using SPSS for Windows (version 13). Student's t-test was used to evaluate differences between groups, and a P value of 0.05 or less was considered to indicate statistical significance.

RESULTS

Background

Of the 760 LCs done during the study period, 11.7% (89 cases) were LSCs: 12 of these 89 cases were classified as LSC-I ($12/760 = 1.58\%$), 51 as LSC-II ($51/760 = 6.71\%$), and 26 as LSC-III ($26/760 = 3.42\%$) (Table 1).

Calot's triangle was difficult to expose at the start of surgery in 164 (21.6%) of the 760 cases, and percutaneous transhepatic gallbladder drainage (PTGBD) was inserted in 91 (12%) cases. As for the timing of operation, only 4 patients (0.53%) underwent surgery within 72 hours of the onset of cholecystitis symptoms. In all other cases, the operation was postponed until inflammation had subsided (Table 2).

Comparison of s-LC and LSC groups

Operative time was significantly longer and blood loss and postoperative CRP were significantly higher in LSC cases than in s-LC cases. Although no significant difference was found in highest postoperative body temperature, duration of postoperative hospital stay was significantly longer for LSC cases. Except for 1 case of postoperative bile leakage after s-LC, there were no intra- or postoperative complications arising from surgery among s-LC or LSC cases. Incidental gallbladder cancer was encountered in 6 s-LC cases and no LSC cases (Table 3).

Comparison of s-LC cases with LSC-I, LSC-II, and LSC-III subgroups

In comparisons of the s-LC group with each of the 3 LSC subgroups, operative time was significantly longer in all LSC subgroups (I, II, and III) as compared with s-LC cases, but blood loss was greater only in the LSC-II subgroup (Figs. 1 and 2).

WBC count was significantly higher in the LSC-I and LSC-III subgroups than in the s-LC group at postoperative day 1, but no other differences in WBC were observed. However, CRP level was significantly higher in all LSC subgroups, as compared with the s-LC group, on postoperative days 1 and 3 (Fig. 3).

No significant differences were seen with respect to highest postoperative body temperature and, as compared with s-LC patients, duration of hospitalization was significantly longer only in LSC-III cases (Fig. 4).

In a comparison of LCs done before and after the introduction of LSC, the percentage of procedures intraoperatively converted from LC to open laparotomy decreased from 6.75% (28/415 cases) to only 1.81% (14/774). Furthermore, bile duct injury also decreased, from 0.48% (2/415 cases) to 0% (0/774 cases) after LSC was introduced.

Long-term results in LSC groups

Long-term (1.5 to 8 years) follow-up of LSC cases revealed no cholecystitis or cancer in remnant gallbladder tissue and no peritoneal abscess formation. However, imaging studies after more than 2 years later showed gallstone recurrence in the remnant of 3 LSC-III cases (3/26 or 11.5% of LSC-III cases; 3/89 or 3.37% of all LSC cases). One of these patients had pancreatic cancer, and the gallstone was removed during pancreatectomy. The other 2 cases are asymptomatic and remain under observation.

DISCUSSION

Reports of subtotal cholecystectomy were being published even when open laparotomy was the standard treatment (2). It was reported that LSC was successful in avoiding serious bile duct injury and contributed to lower rates of intraoperative conversion to open laparotomy (3,4,5,6,7,8,9,10).

However, no study investigated the various LSC procedures required to treat cholecystitis of differing severity. In accordance with the 3-group classification scheme proposed by Palanivelu et al, (1) we used degree of inflammation to determine severity. LSC was significantly associated with longer operative time and higher postoperative CRP. In addition, blood loss was significantly greater in LSC-II cases, and postoperative hospital stays were longer in LSC-III cases. Nonetheless, the clear advantages of LSC (ie, lower rate of intraoperative conversion to open laparotomy and lower risk of bile duct injury) confirmed the usefulness of LSC. Of course, it should be noted that complete removal of the gallbladder is desirable in cholecystectomy cases, and LSC should thus not be decided upon easily.

LSCs are only a small fraction (1.4% to 13.3%) of all LC procedures (5,6,8,9,10,11,12,13), although the rate at our center, 11.7%, is relatively high. This may be due to the fact that although many centers immediately select LC to treat acute cholecystitis, our hospital usually has an internist provide initial acute-stage treatment with PTGBD equipment and antibiotics, which permits surgery to be postponed. Once cholecystitis is no longer acute, surgery is begun. However, this approach may result in localized fibrotic changes. Thus, at the time of the procedure, the gallbladder may often be more difficult to remove completely due to these changes, which may explain our relatively high rate of LSCs.

Although postoperative CRP was higher in the LSC group, it was not related with postoperative complications. Instead, elevated CRP may be due to the fact that the LSC procedure is more complex. Furthermore, drains were inserted as part of the procedure in all LSC-III patients and were removed after confirming the absence of bile leakage. This might have caused to the longer duration of postoperative hospitalization in LSC-III cases.

In LSC, the rates of bile leakage range from 1.8% to 15.4% (6,7,9,10,11,12), and the rate of postoperative peritoneal abscess formation rate is 2.2% to 3.8% (6,8). At our center, these operations were successfully concluded without postoperative bile leakage or peritoneal infection. With respect to abscess formation, we take pains at the end of the procedure to perform complete lavage with careful visual confirmation, which seems to prevent bile leakage. Furthermore, antibiotics are given during and after surgery, which appears to prevent postoperative infections.

During LSC, surgeons frequently have difficulty in obtaining intraoperative cholangiography due to the degree of inflammation. In cases in which cholangiography was impossible, we were only able confirm that sufficient bile flow from the cystic margin was present and that there were no calculi left in the remnant before closing. The absence of bile flow may be due to obstruction by a gallstone, and 2 of our LSC cases required conversion to open laparotomy for this reason. Calculi remain after LSCs in 1.1% to 13% of such procedures (1,6,8,11); however, we observed no cases of remaining calculi. Intraoperative conversion to open laparotomy is justified if remaining calculi must be removed. Three of our patients who underwent LSC-III had a recurrence of gallbladder stones; however, none had any sign of remaining calculi after the operation.

During LSC-III, the mucosa is excised whenever possible, and every attempt is made to close

the lumen by suture. As compared with LSC-II, in which it is possible to isolate the entire circumference of the infundibulum and close it off completely, the fact that more mucosa remains after LSC-III may cause lumen distension resulting in gallstone recurrence. The possibility of recurrence in LSC-III cases must thus be considered.

The long-term postoperative outcome of LSC is a very important factor in evaluating the usefulness of this procedure, but as yet there have been almost no detailed reports of such long-term results. Our own long-term findings show that, except for 3 cases of recurrent gallstones, there were no other serious problems such as cholecystitis, peritoneal abscess, or gallbladder cancer in the remnant. These findings suggest that such complications would be less frequent after LSC.

We consider LSC to be useful in carefully selected patients, ie, those in whom there is a lack of clear anatomic definition due to inflammation and/or fibrosis, as LSC can help the surgeon avoid the bile duct injury and resulting intraoperative complications and reduce the frequency of conversion to open laparotomy. Of course, surgeons must be reminded that selection of LSC-III may be associated with long-term recurrence of cholelithiasis in the gallbladder remnant.

REFERENCES

- 1) Palanivelu C, Rajan PS, Jani K et al: Laparoscopic cholecystectomy in chirrhotic patients : the role of subtotal cholecystectomy and its variants. J Am Coll Surg 2006; 203:145-151.
- 2) Bornman PC, Terblanche J: Subtotal cholecystectomy : for the difficult gallbladder in portal hypertension and cholecystitis. Surgery 1985; 98:1-6.
- 3) Hussain A: Difficult laparoscopic cholecystectomy : current evidence and strategies of management. Surg Laparosc Percutan Tech 2011; 21:211-217.
- 4) Singhal T, Balakrishnan S, Hussain A et al: Laparoscopic subtotal cholecystectomy : initial experience with laparoscopic management of difficult cholecystitis. Surgeon 2009; 7:263-268.
- 5) J Nakajima, A Sasaki, T Obuchi et al : Laparoscopic subtotal cholecystectomy for severe cholecystitis. Surg Today 2009; 39:870-875.
- 6) J.A.E. Philips, D.A. Lawes, A.J. Cook et al : The use of laparoscopic subtotal cholecystectomy for complicated cholelithiasis. Surg Endosc 2008; 22:1697-1700.
- 7) A. Horiuchi, Y. Watanabe, T. Doi et al : Delayed laparoscopic subtotal cholecystectomy in acute cholecystitis with severe fibrotic adhesions. Surg Endosc 2008; 22:2720-2723.
- 8) G. Beldi, A. Glattli : Laparoscopic subtotal cholecystectomy for severe cholecystitis. Surg Endosc 2003; 17:1437-1439.
- 9) PK Chowbey, A Sharma, R Khullar et al : Laparoscopic subtotal cholecystectomy : a review of 56 procedures. J Laparoendosc Adv Surg Tech A 2000; 10:31-34.
- 10) K. Michalowski, P.C. Bornman, J.E.J. Krige et al : Laparoscopic subtotal cholecystectomy in patients with complicated acute cholecystitis or fibrosis. Br J Surg 1998; 85:904-906.

- 1 1) S. Komatsu, H. Hasegawa, T Shiroko et al : Safety and complications of laparoscopic subtotal cholecystectomy for severe cholecystitis. Jpn J Gastroenterol Surg 2008; 41:1758-1764.
- 1 2) Ji W, Li LT, Li JS : Role of laparoscopic subtotal cholecystectomy in the treatment of complicated cholecystitis. Hepatobiliary Pancreat Dis Int 2006; 5:584-589.
- 1 3) P.K. Chowbey, S.K. Badyopadhyay, A. Sharma et al : Laparoscopic reintervention for residual gallstone disease. Surg Laparosc Percutan Tech 2003; 13:31-35.

Figure legends

Figure 1. Duration of surgery: s-LC vs LSC-I, LSC-II, and LSC-III

s-LC/standard Laparoscopic Cholecystectomy

LSC/Laparoscopic Subtotal Cholecystectomy

Figure 2. Intraoperative bleeding: s-LC vs LSC-I, LSC-II, and LSC-III

s-LC/standard Laparoscopic Cholecystectomy

LSC/Laparoscopic Subtotal Cholecystectomy

Figure 3. CRP values at 1 POD and 3 POD: s-LC vs LSC-I, LSC-II, and LSC-III

s-LC/standard Laparoscopic Cholecystectomy

LSC/Laparoscopic Subtotal Cholecystectomy

Figure 4. Postoperative hospitalization days: s-LC vs LSC-I, LSC-II, and LSC-III

s-LC/standard Laparoscopic Cholecystectomy

LSC/Laparoscopic Subtotal Cholecystectomy

Table 1 Surgical procedures for 760 LC cases (Jan 2004 to Dec 2010)

No. of cases, by procedure (n=760)	<table> <tr> <td>s-LC</td> <td>671</td> <td>(88.3%)</td> </tr> <tr> <td>LSC</td> <td>89</td> <td>(11.7%)</td> </tr> </table>	s-LC	671	(88.3%)	LSC	89	(11.7%)			
s-LC	671	(88.3%)								
LSC	89	(11.7%)								
No. of LSC cases in each procedure subgroup	<table> <tr> <td>LSC-I</td> <td>12</td> <td>(1.58%)</td> </tr> <tr> <td>LSC-II</td> <td>51</td> <td>(6.71%)</td> </tr> <tr> <td>LSC-III</td> <td>26</td> <td>(3.42%)</td> </tr> </table>	LSC-I	12	(1.58%)	LSC-II	51	(6.71%)	LSC-III	26	(3.42%)
LSC-I	12	(1.58%)								
LSC-II	51	(6.71%)								
LSC-III	26	(3.42%)								

s-LC /standard Laparoscopic Cholecystectomy

LSC /Laparoscopic Subtotal Cholecystectomy

Table 2 Intraoperative condition of gallbladder (cholecystitis severity) and timing of surgery

Gallbladder condition (cholecystitis severity)	
Cases in which exposure of Calot's triangle was difficult	164 (21.6%)
PTGBD inserted	91 (12.0%)
Timing of surgery	
Early surgery (within 72 hours of onset of cholecystitis symptoms)	4 (0.53%)

PTGBD/percutaneous transhepatic gallbladder drainage

Table 3 Characteristics of s-LC and LSC cases

	s-LC	LSC	P value
n	671	89	
Sex, male/female	351/320	58/31	
Age	55.7	62.9	
Operative time (min)	111.6	164.4	< 0.05
Blood loss (ml)	17.2	51.3	< 0.05
WBC (1POD) (cells/ μ l)	8647	9275	< 0.05
WBC (3POD) (cells/ μ l)	6174	6665	< 0.05
CRP (1POD) (mg/dl)	2.44	4.65	< 0.05
CRP (3POD) (mg/dl)	3.04	7.35	< 0.05
Highest postoperative temperature ($^{\circ}$ C)	37.5	37.6	0.236
Postoperative hospital stay (days)	4.71	6.19	< 0.05
Complications			
Bile duct injury	0	0	
Postoperative bile leakage	1	0	
Postoperative peritoneal abscesses	0	0	
Unsuspected gallbladder cancer	6	0	

s-LC /standard Laparoscopic Cholecystectomy

LSC /Laparoscopic Subtotal Cholecystectomy

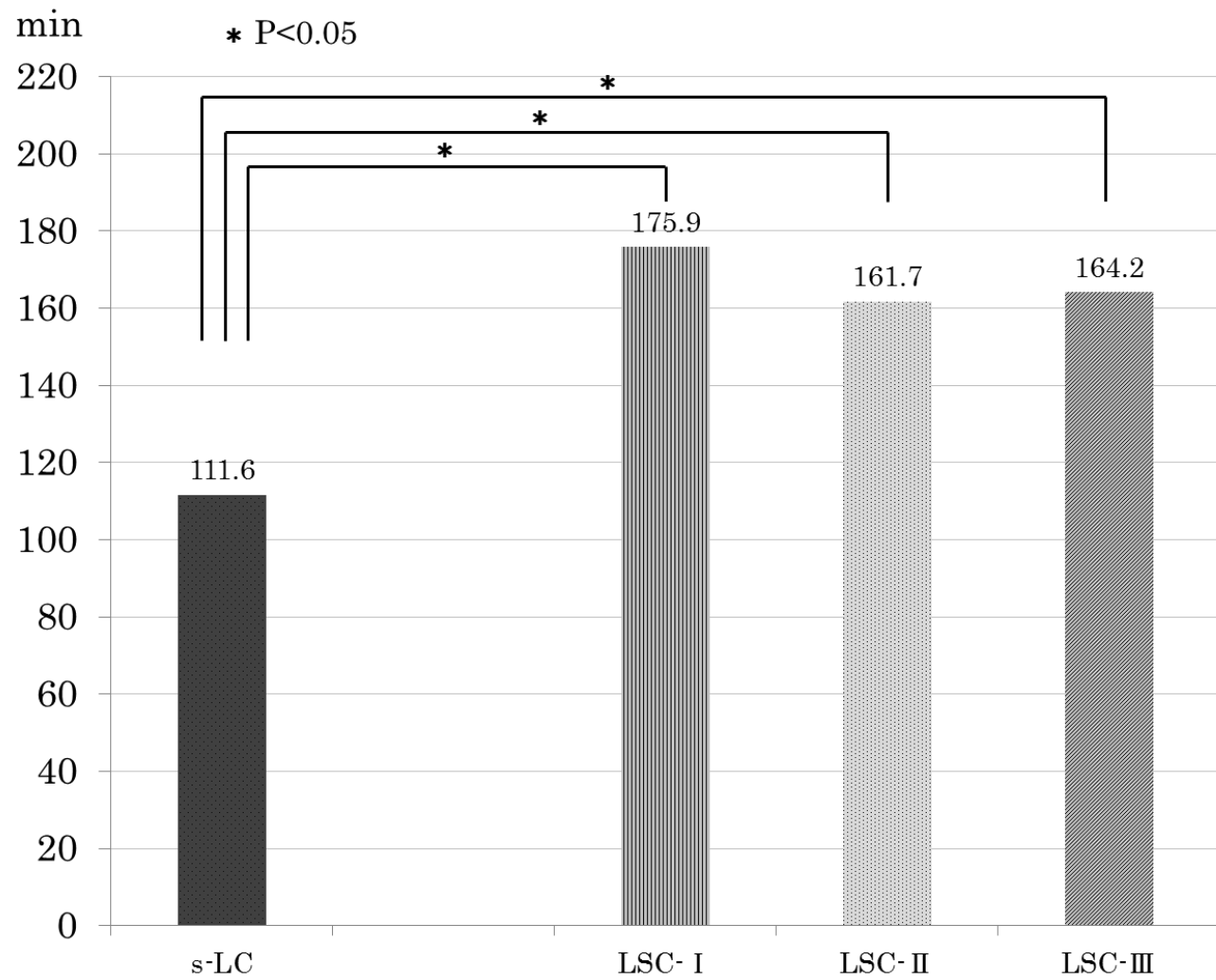


Figure1

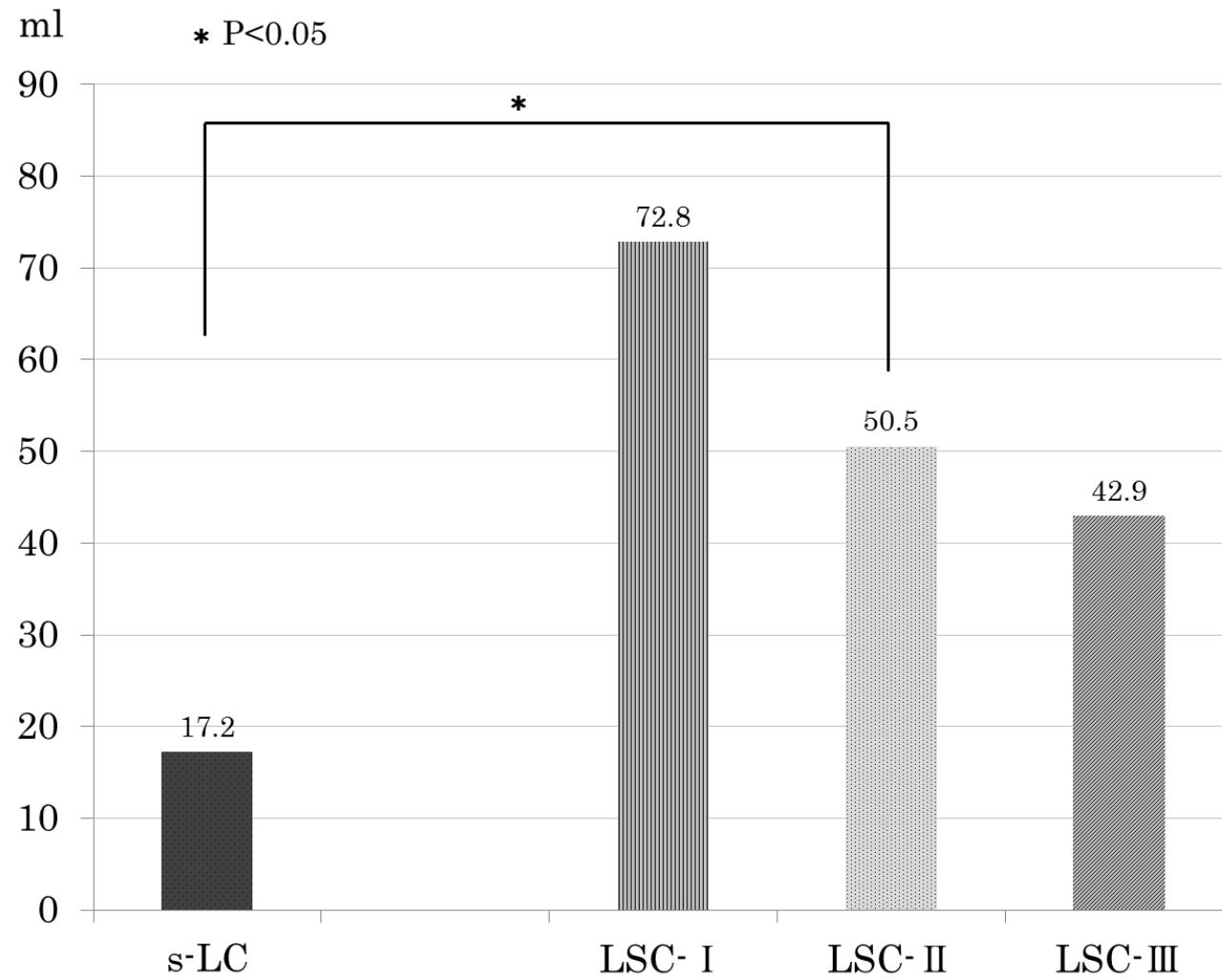


Figure2

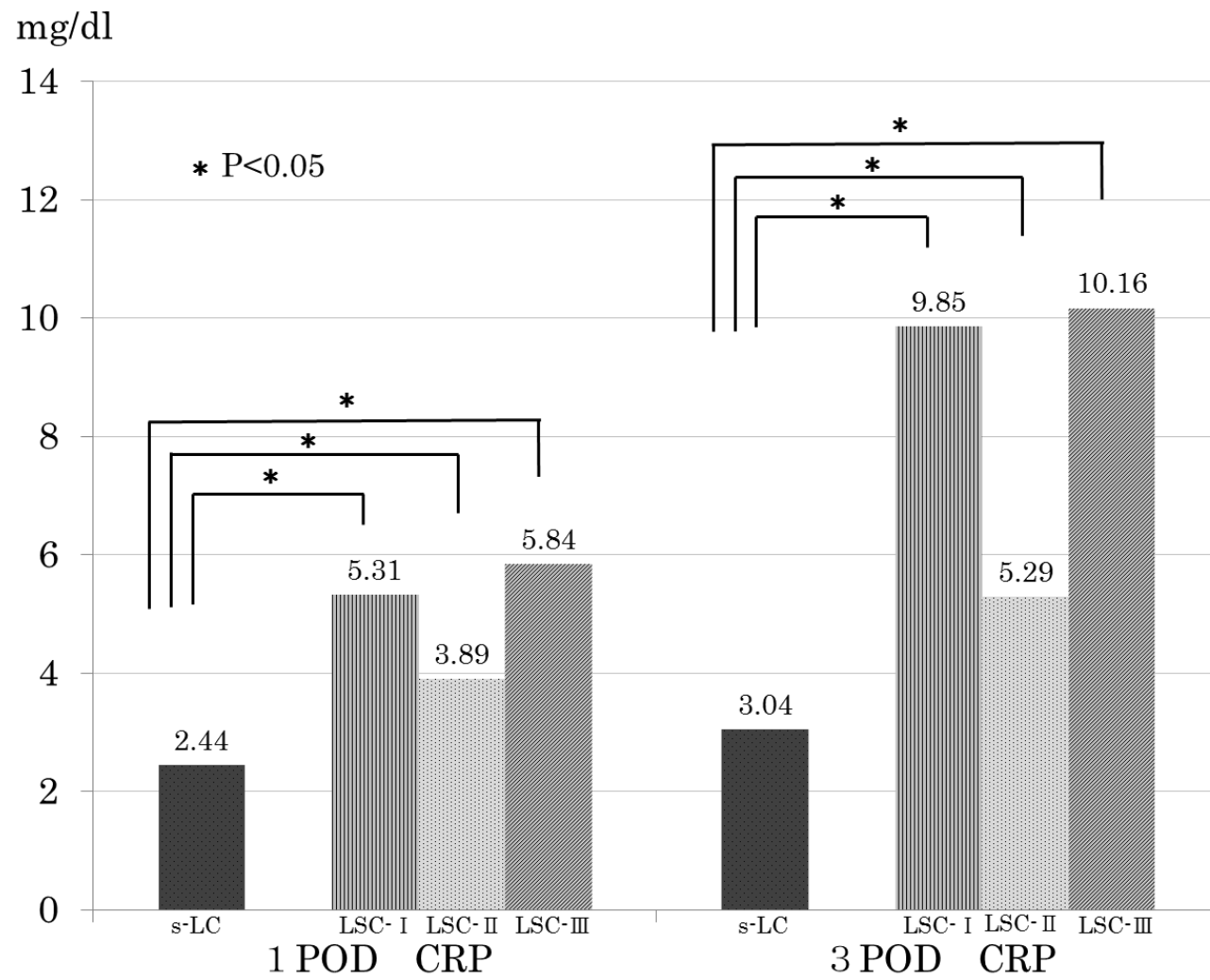


Figure3

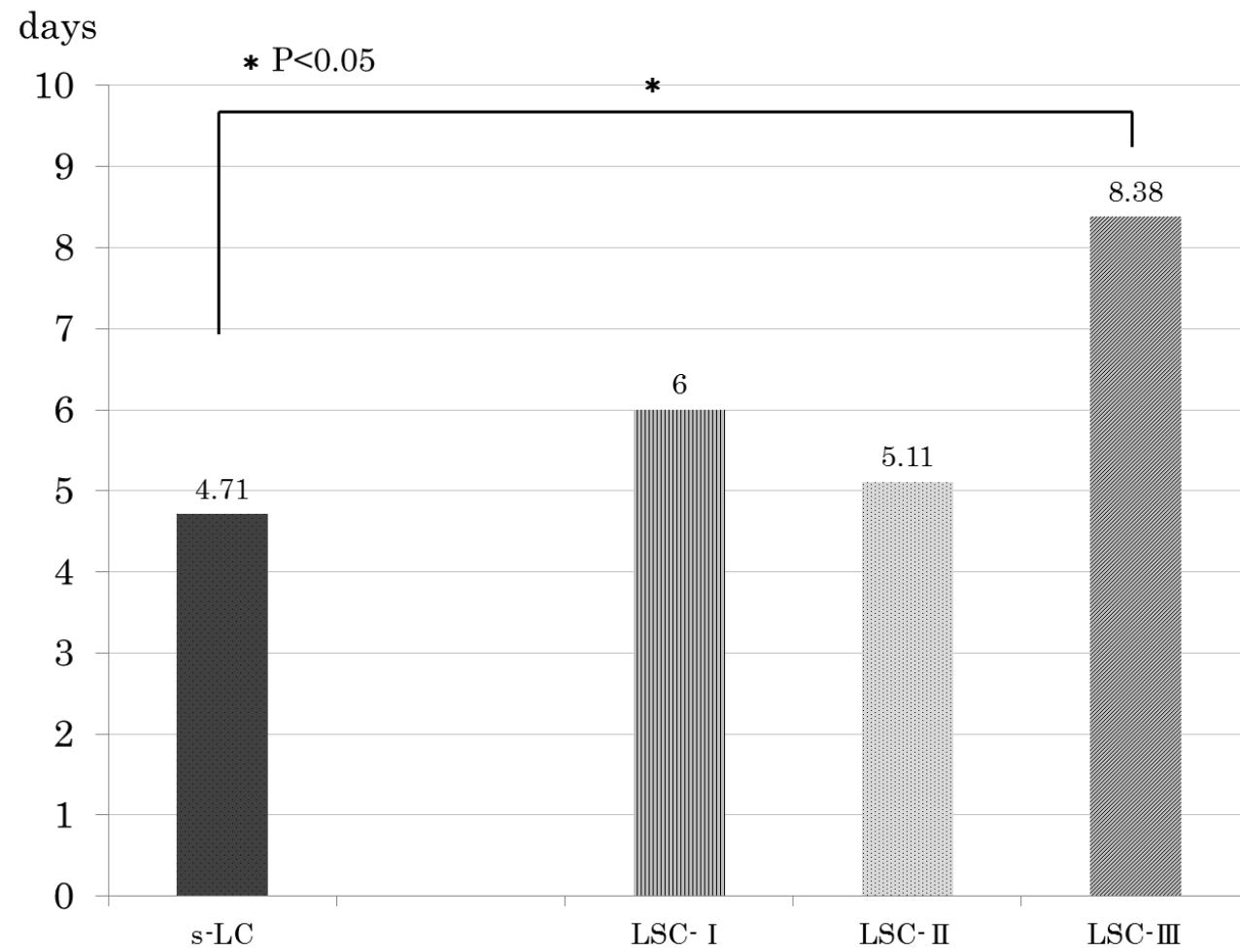


Figure4