

東邦大学学術リポジトリ

Toho University Academic Repository

タイトル	Indocyanine Green Fluorescence Angiography Aids in Intraoperative Management of an Adult with Ebstein Anomaly
作成者（著者）	Yuzo, Katayama / Tsukasa, Ozawa / Noritsugu, Shiono / Yoshinori, Watanabe
公開者	The Medical Society of Toho University
発行日	2017.9
ISSN	21891990
掲載情報	Toho Journal of Medicine. 3(3). p.93 95.
資料種別	学術雑誌論文
内容記述	Case Report
著者版フラグ	publisher
JaLCDOI	info:doi/10.14994/tohojmed.2016.038
メタデータのURL	https://mylibrary.toho u.ac.jp/webopac/TD11187213

Case Report

Indocyanine Green Fluorescence Angiography Aids in Intraoperative Management of an Adult with Ebstein Anomaly

Yuzo Katayama* Tsukasa Ozawa Noritsugu Shiono
and Yoshinori Watanabe

Division of Cardiovascular Surgery, Department of Surgery, Toho University Omori Medical Center

ABSTRACT: A 51-year-old man who had undergone a modified Carpentier procedure at age 32 years for Ebstein anomaly later developed chronic heart failure due to severe tricuspid regurgitation and atrial flutter with right heart dysfunction. Findings from indocyanine green fluorescence angiography were helpful in avoiding an unnecessary additional procedure of one and one half ventricle repair. At a 6-month follow-up examination, the patient was asymptomatic and had a normal sinus rhythm without administration of an antiarrhythmic agent.

Toho J Med 3 (3): 93–95, 2017

KEYWORDS: congenital heart surgery, adult, intraoperative examination

Case report

A 51-year-old man had received a diagnosis of Ebstein anomaly and Wolff-Parkinson-White syndrome at birth. At age 32 years he underwent a modified Carpentier operation for treatment of Ebstein anomaly and division of an accessory pathway. Tricuspid valve regurgitation and atrial flutter were diagnosed 15 years after surgery. He developed exertional breathlessness and palpitation and was referred to us after unsuccessful catheter ablation.

Grade 3/6 systolic regurgitant murmur was best heard at the apex. Electrocardiography revealed sinus rhythm with complete right bundle branch block and first-degree atrioventricular block at rest after administration of an antiarrhythmic agent (bisoprolol fumarate), which converted to atrial flutter during the episode (Fig. 1). Cardiac echocardiography revealed severe tricuspid regurgitation with

detachment of the artificial ring and enlargement of the right atrium and right ventricle (Fig. 2-A). Catheter angiography showed grade IV tricuspid regurgitation, with a dilated right atrium and decreased cardiac contractility of the right ventricle (Fig. 3-A) but without pulmonary hypertension. On the basis of these findings, we scheduled the patient for tricuspid valve replacement and isthmus block with preparation for one and one half ventricle repair.

After re-sternotomy and adhesiolysis, particularly around the superior vena cava (SVC), azygos vein, and right pulmonary artery (PA), elective cardiopulmonary bypass (CPB) was started. Cardiac standstill was achieved after administration of cardioplegic solution. Oblique right atriotomy revealed partial detachment of the artificial ring and an involuted septal leaflet and posterior leaflet (Fig. 2-B). As soon as the artificial ring and all leaflets were re-

6-11-1 Omorinishi, Ota, Tokyo 143-8541, Japan

*Corresponding Author: tel: +81-3-3762-4151

e-mail: yuuzou.katayama@med.toho-u.ac.jp

DOI: 10.14994/tohojmed.2016.038

Received Dec. 20, 2016; Accepted Apr. 23, 2017

Toho Journal of Medicine 3 (3), Sept. 1, 2017.

ISSN 2189-1990, CODEN: TJMOA2

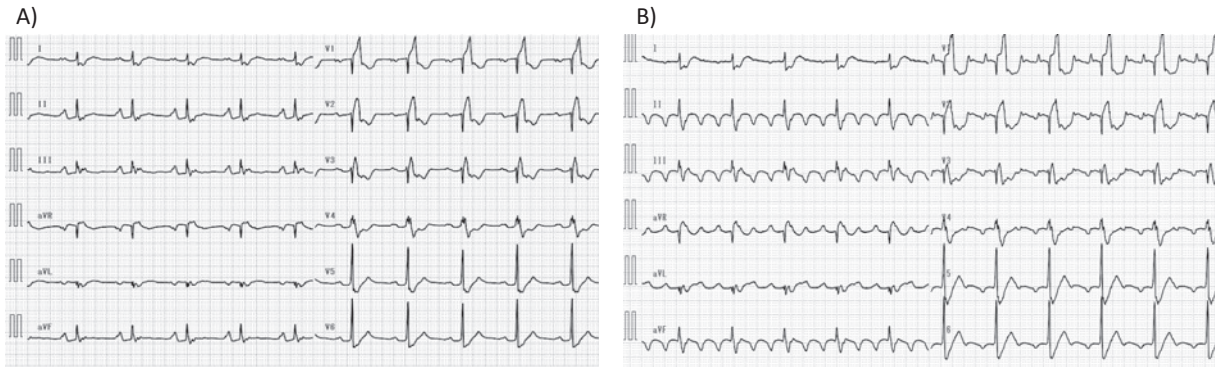


Fig. 1 Twelve-lead electrocardiograms at rest (A) and during an episode (B).

- A) Sinus rhythm with complete right bundle branch and first-degree atrioventricular block.
 B) 4:1 atrial flutter.

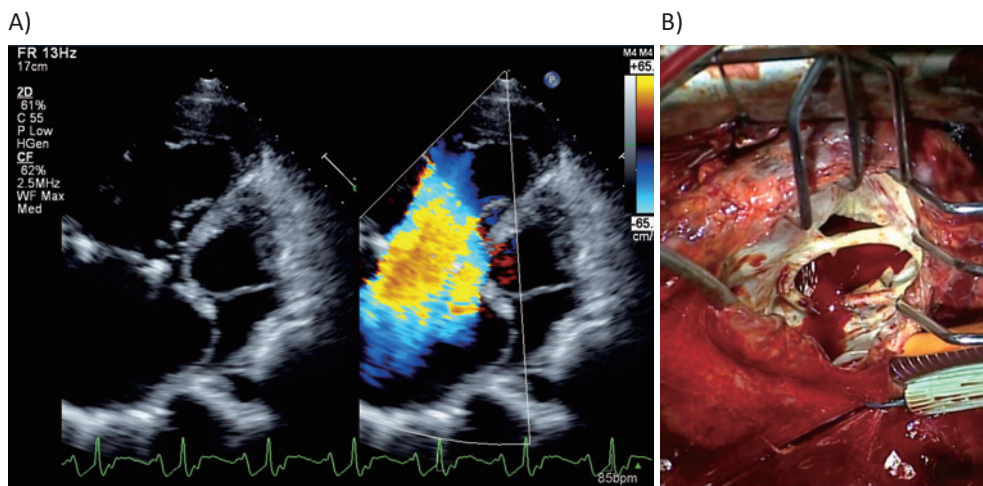


Fig. 2 The tricuspid valve and right heart in a preoperative cardiac echocardiogram (A) and in an operative photograph (B).

- A) Severe tricuspid regurgitation with detachment of the artificial ring and enlargement of the right atrium and right ventricle.
 B) Partial detachment of the artificial ring, and an involuted septal leaflet and posterior leaflet of the tricuspid valve.

moved, we performed tricuspid valve replacement with a bioprosthetic valve and isthmus block.

The patient was successfully weaned from CPB without removing the cannulas. Then, an intraoperative imaging device (PDE Near-Infrared Fluorescence Imager; Hamamatsu Photonics K.K.) was positioned over the operative field. Indocyanine green dye was administered from a jugular catheter, and a monitor was used to observe passage of contrast medium from the SVC to PA in real time (Fig. 3-B). The findings allowed us to forgo bidirectional Glenn anastomosis for one and one half ventricle repair.

Discussion

Because of advances in surgical and medical management, most patients with congenital heart disease (CHD), even complex CHD, can be expected to reach adulthood. Several studies have reported estimates of the number of adults with CHD, and the number of such patients is expected to increase dramatically^{1,2)}, particularly those with right heart dysfunction. Understanding of CHD in adults has greatly increased during the past decade in several fields, including imaging, arrhythmia, management, percutaneous interventions, surgical techniques, research, and

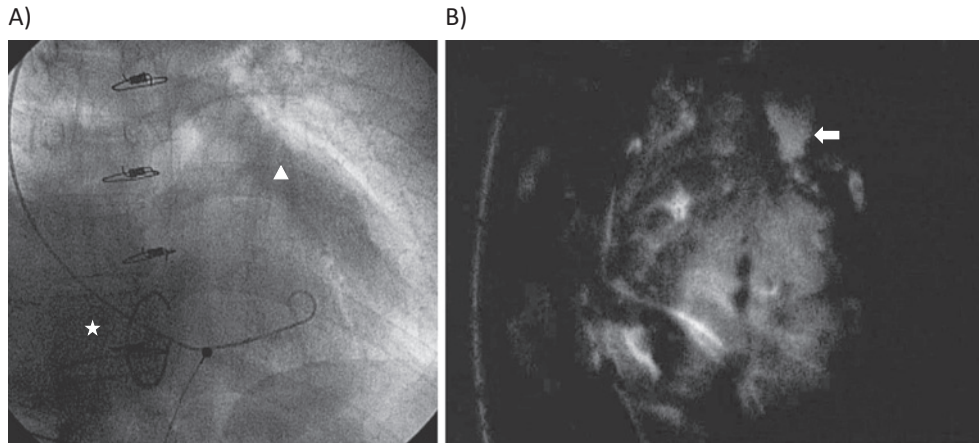


Fig. 3 Angiographic findings on preoperative right ventriculography (A) and indocyanine green fluorescence angiography (B).

A) Less contrast medium is visible at the site of grade IV tricuspid regurgitation (star) and in the anterograde pulmonary artery than in the right atrium (arrowhead).

B) Passage of contrast medium from the SVC to PA (arrow).

multidisciplinary care that extends beyond the cardiac realm³.

Indocyanine green is approved for use in humans and has been used safely for more than 40 years. It was initially found to be useful in measuring cardiac output and assessing hepatic function. It is also used for intraoperative evaluation of coronary artery bypass grafting in cardiac surgery⁴, and it has recently been used in transplant surgery, neurosurgery, and plastic surgery. However, few studies have examined the usefulness of intraoperative indocyanine green fluorescence angiography in congenital heart surgery⁵. In our patient, we were unable to determine preoperatively whether biventricular repair was possible, due to diminished cardiac contractility and the decreased capacity of the right ventricle after surgical treatment of Ebstein anomaly. Indocyanine green fluorescence angiography allowed us to visualize the smooth flow to the PA, and we were thus able to forgo an unnecessary additional procedure. To our knowledge, this is the first report of the use of indocyanine green fluorescence angiography

in adult congenital heart surgery.

All authors participated in the design of the case report and the drafting of the manuscript.

Conflicts of interest: None declared.

References

- 1) Warnes CA, Liberthson R, Danielson GK, Dore A, Harris L, Hoffman JJ, et al. Task force 1: the changing profile of congenital heart disease in adult life. *J Am Coll Cardiol.* 2001; 37: 1170-5.
- 2) Marelli AJ, Mackie AS, Ionescu-Ittu R, Rahme E, Pilote L. *Circulation.* 2007; 115: 163-72.
- 3) Ishizu T, Horigome H. Assessment and treatment of systemic right ventricular dyssynchrony. *Circ J.* 2015; 79: 519-21.
- 4) Hol PK, Lingaas PS, Lundblad R, Rein KA, Vatne K, Smith HJ, et al. Intraoperative angiography leads to graft revision in coronary artery bypass surgery. *Ann Thorac Surg.* 2004; 78: 502-5.
- 5) Kogon B, Fernandez J, Kanter K, Kirshbom P, Vincent B, Maher K, et al. The role of intraoperative indocyanine green fluorescence angiography in pediatric cardiac surgery. *Ann Thorac Surg.* 2009; 88: 632-6.