

東邦大学学術リポジトリ

Toho University Academic Repository

タイトル	Factors affecting functional medial ligament balancing in patients undergoing total knee arthroplasty for varus knees
別タイトル	内反膝の人工膝関節全置換術(TKA)における内側支持機構解離に影響を与える因子について
作成者(著者)	金子, 卓男 / 二木, 康夫 / 松本, 秀男 / 池上, 博泰 / 武者, 芳朗
公開者	東邦大学医学会
発行日	2012.11
ISSN	00408670
掲載情報	東邦医学会雑誌. 59(6). p.297-304.
資料種別	学術雑誌論文
内容記述	原著
著者版フラグ	publisher
JaLCDOI	info:doi/10.14994/tohoigaku.59.297
メタデータのURL	https://mylibrary.toho-u.ac.jp/webopac/TD00591131

Original Article

Factors Affecting Functional Medial Ligament Balancing in Patients Undergoing Total Knee Arthroplasty for Varus Knees

Takao Kaneko^{1)*} Yasuo Niki²⁾ Hideo Matsumoto³⁾
 Hiroyasu Ikegami¹⁾ and Yoshiro Musha¹⁾

¹⁾Department of Orthopaedic Surgery (Ohashi), School of Medicine, Faculty of Medicine, Toho University

²⁾Department of Orthopaedic Surgery, School of Medicine, Keio University

³⁾Institute for Integrated Sports Medicine, School of Medicine, Keio University

ABSTRACT

Background: We investigated factors affecting the degree of medial ligament release necessary for equal medial/lateral ligament balancing in patients undergoing total knee arthroplasty (TKA).

Methods: This study enrolled 112 patients (129 knees) who underwent TKA due to medial compartment knee osteoarthritis (OA) with varus deformity. The procedure for medial ligament release was divided into 3 steps, based on an original algorithm, and the associations between preoperative patient characteristics and release steps necessary for appropriate balancing was analyzed.

Results: The data showed that degree of medial release was proportional to preoperative femorotibial angle (FTA), whereas neither preoperative range of motion nor preoperative flexion angle was associated with medial ligament release. Correction of larger flexion contracture required more-advanced steps of medial ligament release. Severity of OA findings on radiographic classification was not associated with the degree of medial release intraoperatively. The results indicate that release of posterior oblique fibers and the posterior capsule was more important than release of anterior longitudinal fibers in achieving significant alleviation of preoperative flexion contracture with a posterior-stabilized prosthesis.

Conclusions: The FTA the presence of flexion contracture affected the site and degree of medial ligament release in patients undergoing TKA for varus knees.

J Med Soc Toho 59 (6): 297–304, 2012

KEYWORDS: knee osteoarthritis, total knee arthroplasty, medial collateral ligament, ligament balancing

Knee osteoarthritis (OA) is a common cause of disability, chronic pain, and limited activity in older adults. Total knee arthroplasty (TKA) is an effective strategy for managing OA; however, because the pathology of medial ligament contracture varies, there is no consensus as to the most appropriate sequence or method of medial ligament

release in varus knees resulting from medial compartment OA. Knee flexion contracture frequently accompanies severe varus deformity associated with OA, osteonecrosis, and rheumatoid arthritis and markedly influences the ability to engage in activities of daily living.

Peters et al. suggested that soft tissue balancing is an

1) 2-17-6 Ohashi, Meguro, Tokyo 153-8515

2, 3) 35 Shinanomachi, Shinjuku, Tokyo 160-8582

*Corresponding Author: tel: 03 (3468) 1251

e-mail: takaokaneko1208@yahoo.co.jp

Received Jan. 6, 2012; Accepted Nov. 1, 2012

Journal of the Medical Society of Toho University

59 (6), Nov. 1, 2012. ISSN 0040-8670. CODEN: TOIZAG

Table 1 Steps and sequence of medial ligament release

Step 1:	Deep layer of MCL and medial capsule
Step 2:	Release of POF or ALF of MCL according to status of medial tightness in knee flexion and extension.
	Step 2 subdivided as follows:
2a:	Step 1 + POF with part of semimembranosus tendon
2b:	Step 1 + ALF
2c:	Step 1 + POF + ALF
Step 3a:	Step 2a + posterior capsule
3b:	Step 2c + posterior capsule

MCL: medial collateral ligament, POF: posterior oblique fibers, ALF: anterior longitudinal fibers

important TKA surgical technique that produces promising stability and good long-term clinical results.¹⁻³⁾ Most patients with varus knee, which is present in most Japanese OA patients, have shortness of the medial soft tissue in flexion and require sufficient release of this tissue to achieve appropriate soft tissue balance. Recently, minimally invasive surgery (MIS) TKA has been developed to hasten recovery of range of motion (ROM) and muscular function after surgery and reduce the duration of hospital stays. However, in MIS TKA the length of the skin incision is short, and the area of visualization may thus be insufficient to achieve accurate soft tissue release. Furthermore, the number of radiographic outliers is greater with this technique than with standard TKA. Thus, preoperative prediction of the effect of medial soft tissue release is necessary for MIS TKA. Previous studies have identified factors that affect each step of medial soft tissue release in varus medial OA knees during posterior-stabilized TKA, but no study has investigated whether the effect of medial soft tissue release can be predicted preoperatively. We attempted to identify the preoperative patient characteristics that were associated with the degree of medial ligament release necessary for equal medial/lateral ligament balancing in TKA.

Methods

This study enrolled 112 patients (129 knees) who were diagnosed with symptomatic medial compartment OA of the knees and had a femorotibial angle (FTA) $\geq 176^\circ$. All patients underwent TKA between April 2004 and May 2009 at our institution. All TKAs were performed by the same surgeon, using the NexGen[®] LPS-Flex System (Zimmer, Inc., Warsaw, IN, USA). This implant is used for cruciate-sacrificed TKA. The study cohort comprised 20 men (23 knees) and 92 women (106 knees). Mean age was 69.3 years (range, 40-89 years). With regard to MIS surgi-

cal approach, the midvastus approach was used for the first 76 knees, and the subvastus approach was used for the subsequent 53 knees. Measured resection techniques were used for all surgical cases. All bone cuttings in the distal femur and the proximal tibia, and all excision of cruciate ligaments, were performed before adjusting medial/lateral balance.

Medial ligament release was divided into 3 steps, as shown in the Table 1 and Fig. 1. Step 1 was performed after the knee-joint opening procedure in all patients and minimum release for TKA and was defined as release of the deep fibers of the medial collateral ligament (MCL) and part of the medial capsule among the medial ligaments. Step 2a consisted of additional release of the posterior oblique fibers (POF) for tightness of the medial ligament during extension. Step 2b consisted of additional release of the anterior longitudinal fibers (ALF) of the MCL for medial tightness during knee flexion. Step 2c consisted of release of the whole MCL for medial tightness during both flexion and extension. Steps 3a and 3b included additional release of the posterior capsule after release steps 2a and 2c, respectively. Medial release was done until equal medial/lateral ligament balancing was acquired in both flexion and extension. When the medial side served as the fulcrum of rotation, the medial envelope was considered to be tighter than the lateral one, and thus, medial ligament release was performed until equal medial/lateral balancing was acquired. To measure ligament balance, the spacer block technique was used in 68 knees and the Natural Knee balancer (Zimmer Inc.) was used in 61 knees.

We also investigated the relationship between steps of medial ligament release necessary for equal medial/lateral ligament balancing and preoperative patient characteristics, *i.e.*, FTA, flexion contracture, radiographic classification of OA (Kellgren and Lawrence, Ahlbäck), and preoperative flexion angle. Two different radiographic classifica-

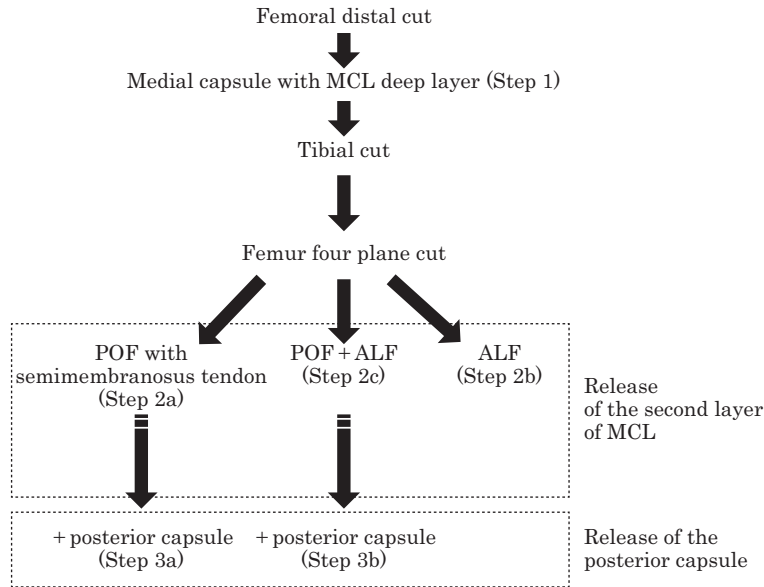


Fig. 1 Algorithm of medial ligament release, which is roughly divided into 3 steps. Step 1 is the release of the medial capsule and deep layer of MCL. Step 2 is the release of the second layers of medial structures, including POF and/or ALF. Step 3 is the release of the posterior capsule and part of the semimembranosus tendon.
MCL: medial collateral ligament, POF: posterior oblique fibers, ALF: anterior longitudinal fibers

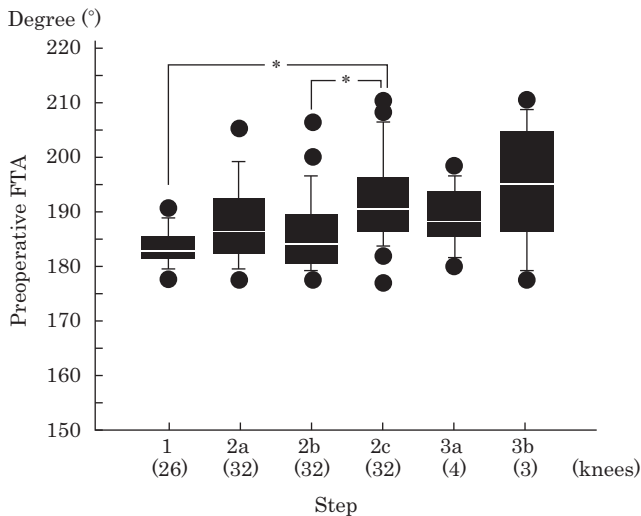


Fig. 2 Graph showing the relationship between preoperative mechanical alignment and degree of medial ligament release. Box-and-whisker plot shows preoperative FTA for each step needed to gain satisfactory medial/lateral balancing. The box shows the interquartile range and median; the whiskers show the range.
*p<0.05, Student *t*-test
FTA: femorotibial angle

were classified into grades 1 to 4 according to the presence of joint space narrowing and osteophyte formation. In the classification of Ahlbäck, OA severity was estimated according to the degrees of joint space narrowing and bone attrition (grade 1: joint space narrowing; grade 2: joint space obliteration; grade 3: bone attrition <5 mm; grade 4: bone attrition of 5-15 mm; grade 5: bone attrition >15 mm). Statistical analysis was performed using the Student *t*-test and multifactorial analysis of variance (ANOVA). A p value of 0.05 or less was considered to indicate statistical significance. To determine the extent of release necessary, comparisons were made among 3 groups classified according to flexion contracture.

Results

All knees required release of the medial capsule and the MCL deep layer. In 26 knees, this release step was sufficient to achieve satisfactory ligament balance (step 1). Additional release of the second layer of MCL was needed in 96 knees, including step 2a in 32 knees, step 2b in 32 knees, and step 2c in 32 knees. In the remaining 7 patients, further ligament release and release of the posterior capsule was required to achieve equal medial/lateral ligament balance (step 3a: 4 knees; step 3b: 3 knees).

tions were used in this study. In the radiographic classification of Kellgren and Lawrence, radiographic findings

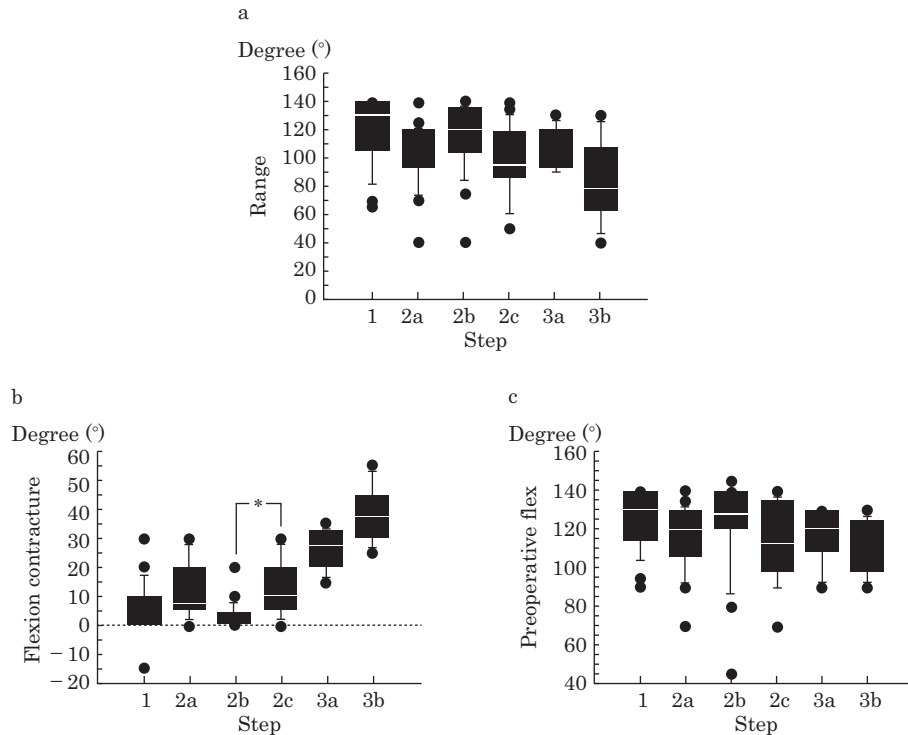


Fig. 3 Graphs showing relationships between preoperative range of motion (ROM) and degree of medial ligament release: total ROM and release steps (a), flexion contracture and release steps (b), and flexion angle and release steps (c). The box shows the interquartile range and median; the whiskers show the range.

* $p < 0.05$, multifactorial ANOVA

ANOVA: analysis of variance

FTA was not associated with release steps 1 to 2b. However, patients who underwent step 2c has a significantly greater FTA than did those requiring step 1 and step 2b (Fig. 2). FTA was significantly greater in patients requiring step 2c for release of ALF and POF. Preoperative ROM was not associated with the release steps required, while some patients with poor ROM required more release steps (Fig. 3a). Preoperative flexion contracture was associated with release steps required, while steps 1 to 2c were not associated with degree of flexion contracture. The preoperative flexion contracture angle required for release of POF and ALF (step 2c) was significantly greater ($p < 0.05$) than that required for ALF (step 2b) in multifactorial ANOVA (Fig. 3b), which indicates that release of POF was very important. There was no association between preoperative maximum flexion angle and release steps required (Fig. 3c).

We classified patients into 3 groups on the basis of preoperative flexion contracture angle. All but 1 patient with a flexion contracture angle less than 30° did not require release of the posterior capsule. However, 50% of patients

with a flexion contracture angle greater than 30° required such release (Fig. 4).

Preoperative radiographic knee assessment showed that most patients undergoing TKA had severe OA, according to the classification of Kellgren and Lawrence. However, this classification was not associated with the degree of medial release required intraoperatively. All knees that required step 3b release were classified as grade 5 according to the Ahlbäck classification, while step 3a release was required even in knees with lower grades (grade 1 or 3). These results indicate that ligament release is not dependent on degree of bone attrition (Fig. 5).

Discussion

Well-balanced soft tissue is essential in achieving good results when performing TKA.^{4,5)} Soft-tissue release must be done precisely, step by step.^{6,7)} Ligament balancing of medial structures of the knee involves modulation of complex ligament structures that behave differently in flexion and extension. The anatomic basis for the different functions of the 3 distinct layers of medial structures has been

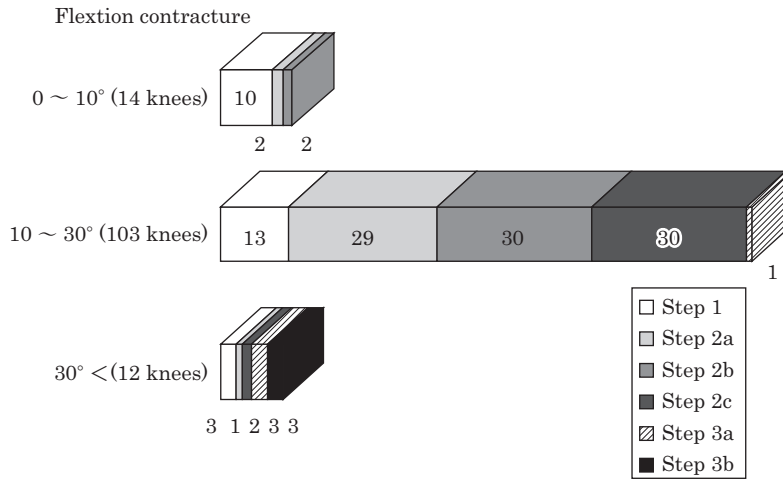


Fig. 4 Graph showing relationships between flexion contracture angle and release steps required.

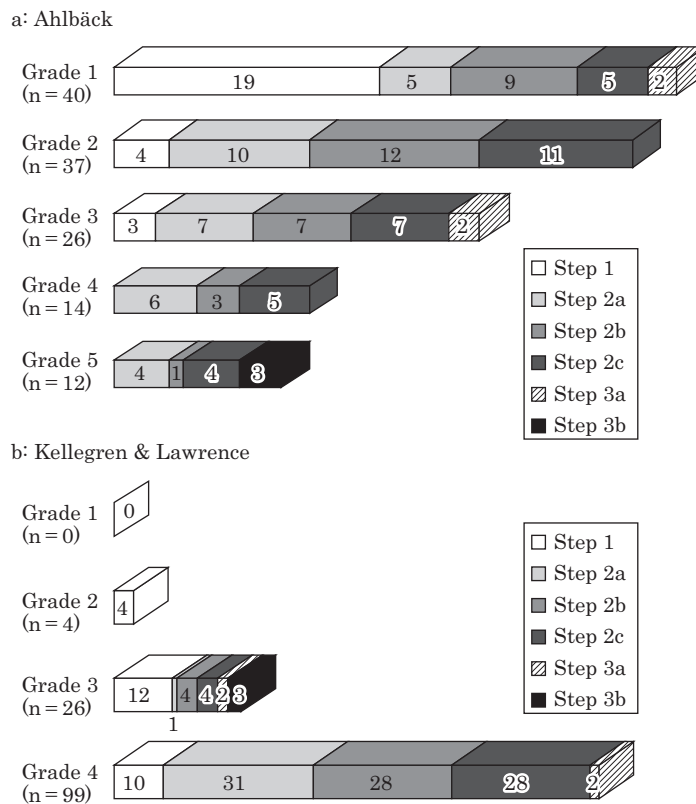


Fig. 5 Graph showing preoperative radiographic OA findings (a: Ahlbäck, b: Kellgren and Lawrence) and medial release steps needed to obtain satisfactory medial/lateral balancing. OA: osteoarthritis

established.⁸⁾ The outermost layer is formed by fusion of the medial patellar retinaculum, hamstrings, and gastrocnemius fascia. The innermost layer (the so-called “deep layer”) consists of the deep fibers of the MCL and the posteriorly positioned posteromedial joint capsule, which is

fused with the POF of the MCL in the intermediate layer. The intermediate layer consists of the ALF and the POF of the MCL. During medial/lateral ligament balancing in patients undergoing TKA for varus knees, the site and degree of medial structure release depends on the pathologic

condition of each knee, including the presence of limited extension (*i.e.*, flexion contracture), limited flexion, inherent posterior cruciate ligament (PCL), attenuation, contracture of the joint capsule, and PCL resection as a process of posterior-stabilized (PS) TKA.

Whiteside et al. suggested that the release site should be adjusted according to the differential pattern of medial tightness in knee extension and flexion.⁹⁻¹¹⁾ In knees with large flexion contracture suggestive of medial tightness in extension, it is important to release the POF of the MCL and part of the semimembranosus tendon, as well as the posterior joint capsule.¹²⁻¹⁴⁾ There were no patients requiring ALF release only in the present study (Fig. 4). In contrast, in knees that have no flexion contracture and are tighter, medially, in flexion than in extension, release of the ALF of the MCL is effective.^{9, 10)} We found that it was important to release the posterior joint capsule in knees with a large flexion contracture angle ($>30^\circ$). These observations are consistent with the results of previous studies, which suggest that release of the posterior joint capsule increased flexion angle without causing valgus instability.¹⁵⁻¹⁹⁾ In the present TKA series, a large proportion of cases required release of the ALF of the MCL. This was necessary primarily in knees that were tighter, medially, in flexion than in extension. The PCL reportedly functions as a medial structure that controls valgus instability, particularly in knee flexion.²⁰⁻²⁶⁾ Because the PCL was routinely cut and a PS prosthesis was used in all patients, we were unable to determine the importance of ALF release in this study. The present study showed that the presence of flexion contracture affected the site and degree of medial ligament release in patients undergoing TKA for varus knees. In addition, the findings indicate that, in alleviating preoperative flexion contracture, it was more important to release the POF and posterior capsule than to release ALF. Although many studies have investigated the effect of balanced soft tissue on operative technique, few have identified perioperative characteristics associated with the amount of soft tissue balancing needed during TKA. Mochizuki et al. suggested that preoperative factors of soft-tissue release in TKA included FTA under stress conditions, the magnitude of strain on a stress test, body mass index, and preoperative extension angle.²⁷⁾ The gap in flexion is decreased by reduction of the patella as compared with patellar eversion in patients with a poor preoperative angle of knee flexion.²⁸⁾

This study showed that degree of FTA and presence of

flexion contracture were associated with the degree of medial ligament release necessary for equal medial/lateral ligament balancing in patients undergoing TKA. We were able to predict a need for ALF and POF release in patients with an FTA greater than 200° and a need for release of the posterior joint capsule in patients with a flexion contracture angle greater than 30° .

This study has several limitations. First, preoperative varus-valgus stress testing was not performed. Stulberg et al.³⁾ suggested that the range of medial soft-tissue release increases when it is not reduced by varus-valgus stress testing among patients with an FTA greater than 200° . We identified important factors in the loosening of a ligament that was reduced by varus-valgus stress testing to the release of medial soft tissue of varus knees. We must determine whether it is not reduced by varus-valgus stress testing under general anesthesia in patients with an FTA less than 200° . In addition, 2 surgical approaches (midvastus and subvastus) were used in this study. Niki et al. suggested that the vastus splitting approach does not necessarily affect the intraoperative joint gap in TKA,²⁹⁾ and the difference in surgical approaches did not seem to affect the results of the present study. Another limitation of this study was that we used a knee balancer and spacer block for gap measurement in TKA. Many studies have investigated perioperative gap measurement in TKA, but none has determined the ideal force for gap measurement. Therefore, in the future we intend to measure gaps using standardized methods of perioperative gap measurement in TKA.

Conclusion

In summary, the presence of flexion contracture was the most important factor in determining the site and degree of medial ligament release in TKA for varus knees. This information may be of use to surgeons in predicting the site and degree of medial structure release before TKA. We were able to perform surgery more precisely and easily after meticulous preoperative evaluation of the degree of flexion contracture and extent of required medial release.

References

- 1) Peters CL: Soft-tissue balancing in primary total knee arthroplasty. *Instr Course Lect* **55**: 413-417, 2006
- 2) Insall JN, Binazzi R, Soudry M, et al: Total knee arthroplasty. *Clin Orthop Relat Res* (192): 13-22, 1985
- 3) Stulberg SD, Loan P, Sarin V: Computer- assisted navigation in

- total knee replacement: Results of an initial experience in thirty-five patients. *J Bone Joint Surg Am* **84-A** (Suppl 2): 90-98, 2002
- 4) Sim JA, Kwak JH, Yang SH, et al.: Utility of preoperative distractive stress radiograph for beginners to extent of medial release in total knee arthroplasty. *Clin Orthop Surg* **1**: 110-113, 2009
 - 5) Bottros J, Gad B, Krebs V, et al.: Gap balancing in total knee arthroplasty. *J Arthroplasty* **21** (4 Suppl 1): 11-15, 2006
 - 6) Yagishita K, Muneta T, Ikeda H: Step-by-step measurements of soft tissue balancing during total knee arthroplasty for patients with varus knees. *J Arthroplasty* **18**: 313-320, 2003
 - 7) Griffin FM, Insall JN, Scuderi GR: Accuracy of soft tissue balancing in total knee arthroplasty. *J Arthroplasty* **15**: 970-973, 2000
 - 8) Bartel DL, Marshall JL, Schieck RA, et al.: Surgical repositioning of the medial collateral ligament. An anatomical and mechanical analysis. *J Bone Joint Surg Am* **59**: 107-116, 1977
 - 9) Whiteside LA, Saeki K, Mihalko WM: Functional medial ligament balancing in total knee arthroplasty. *Clin Orthop Relat Res* (380): 45-57, 2000
 - 10) Saeki K, Mihalko WM, Patel V, et al.: Stability after medial collateral ligament release in total knee arthroplasty. *Clin Orthop Relat Res* (392): 184-189, 2001
 - 11) Buechel FF: A sequential three-step lateral release for correcting fixed valgus knee deformities during total knee arthroplasty. *Clin Orthop Relat Res* (260): 170-175, 1990
 - 12) Muratsu H, Matsumoto T, Kubo S, et al.: Femoral component placement changes soft tissue balance in posterior-stabilized total knee arthroplasty. *Clin Biomech (Bristol, Avon)* **25**: 926-930, 2010
 - 13) Matsumoto T, Muratsu H, Tsumura N, et al.: Joint gap kinematics in posterior-stabilized total knee arthroplasty measured by a new tensor with the navigation system. *J Biomech Eng* **128**: 867-871, 2006
 - 14) Kadoya Y, Kobayashi A, Komatsu T, et al.: Effects of posterior cruciate ligament resection on the tibiofemoral joint gap. *Clin Orthop Relat Res* (391): 210-217, 2001
 - 15) Heesterbeek PJ, Keijsers NL, Wymenga AB: Ligament releases do not lead to increased postoperative varus-valgus laxity in flexion and extension: A prospective clinical study in 49 TKR patients. *Knee Surg Sports Traumatol Arthrosc* **18**: 187-193, 2010
 - 16) Luring C, Hüfner T, Perlick L, et al.: The effectiveness of sequential medial soft tissue release on coronal alignment in total knee arthroplasty: Using a computer navigation model. *J Arthroplasty* **21**: 428-434, 2006
 - 17) Heesterbeek PJ, Wymenga AB: Correction of axial and rotational alignment after medial and lateral releases during balanced gap TKA. A clinical study of 54 patients. *Acta Orthop* **81**: 347-353, 2010
 - 18) Lüring C, Hüfner T, Perlick L, et al.: Soft tissue management in knees with varus deformity. Computer-assisted sequential medial ligament release. *Orthopade* **34**: 1118-1124, 2005 (G)
 - 19) Zhou D, Lv H: Techniques of soft tissue balance in total knee arthroplasty of varus knee. *Zhongguo Xiu Fu Chong Jian Wai Ke Za Zhi* **20**: 602-606, 2006 (C)
 - 20) Leopold SS, McStay C, Klafeta K, et al.: Primary repair of intraoperative disruption of the medial collateral ligament during total knee arthroplasty. *J Bone Joint Surg Am* **83-A**: 86-91, 2001
 - 21) Jeffcote B, Nicholls R, Schirm A, et al.: The variation in medial and lateral collateral ligament strain and tibiofemoral forces following changes in the flexion and extension gaps in total knee replacement. A laboratory experiment using cadaver knees. *J Bone Joint Surg Br* **89**: 1528-1533, 2007
 - 22) Mullaji AB, Padmanabhan V, Jindal G: Total knee arthroplasty for profound varus deformity: Technique and radiological results in 173 knees with varus of more than 20 degrees. *J Arthroplasty* **20**: 550-561, 2005
 - 23) Hirsch HS, Lotke PA, Morrison LD: The posterior cruciate ligament in total knee surgery. Save, sacrifice, or substitute? *Clin Orthop Relat Res* (309): 64-68, 1994
 - 24) Niki Y, Matsumoto H, Otani T, et al.: Accuracy of implant positioning for minimally invasive total knee arthroplasty in patients with severe varus deformity. *J Arthroplasty* **25**: 381-386, 2010
 - 25) Chin PL, Yang KY, Yeo SJ, et al.: Randomized control trial comparing radiographic total knee arthroplasty implant placement using computer navigation versus conventional technique. *J Arthroplasty* **20**: 618-626, 2005
 - 26) Matsumoto T, Muratsu H, Kubo S, et al.: Soft tissue tension in cruciate-retaining and posterior-stabilized total knee arthroplasty. *J Arthroplasty* **26**: 788-795, 2011
 - 27) Mochizuki T, Ikari K, Niki Y, et al.: Can we predict the amount of soft tissue release at preoperative planning of total knee arthroplasty in patients with osteoarthritis. *JOSKAS* **35**: 623-627, 2010 (J)
 - 28) Yoshino N, Watanabe N, Watanabe Y, et al.: Measurement of joint gap load in patella everted and reset position during total knee arthroplasty. *Knee Surg Sports Traumatol Arthrosc* **17**: 484-490, 2009
 - 29) Niki Y, Takeda Y, Kanagawa H, et al.: Effects of four different surgical approaches on intra-operative joint gap in posterior-stabilized total knee arthroplasty. *Knee Surg Sports Traumatol Arthrosc* **20**: 2026-2031, 2012

(J): in Japanese
(G): in German
(C): in Chinese

内反膝の人工膝関節全置換術 (TKA) における 内側支持機構解離に影響を与える因子について

金子 卓男¹⁾ 二木 康夫²⁾ 松本 秀男³⁾
池上 博泰¹⁾ 武者 芳朗¹⁾

¹⁾東邦大学医学部整形外科学講座 (大橋)

²⁾慶應義塾大学医学部整形外科学教室

³⁾慶應義塾大学スポーツ医学総合センター

要約

目的: 本研究は人工膝関節全置換術 (total knee arthroplasty : TKA) における内外側バランスを獲得するために必要な内側支持機構解離の方法およびそれに影響を与える因子について検討した。

対象および方法: 内反変形を伴った変形性膝関節症 (osteoarthritis : OA) に TKA を施行した 112 例 129 膝を対象とした。内側支持機構解離の方法は独自のアルゴリズムを作製し、3つの手順に分けた。術前の患者因子と内外側バランスが均等になるために必要な内側解離量について分析した。

結果: 術前の大腿脛骨角 (femorotibial angle : FTA) が大きければ、内側解離量は多くなった。OA の X 線分類による重症度は、術中の内側解離量と相関しなかった。術前の膝関節可動域と膝屈曲角度は、内側解離量に影響を与えなかったが、術前の屈曲拘縮が大きい例ほど内側側副靭帯、後斜走線維および後方関節包の解離を必要とした。後十字靭帯切除する人工関節を使用する際に、術前の屈曲拘縮を改善するためには前斜走線維よりも後斜走線維と後方関節包の剥離が重要であった。

結論: 内反膝の TKA を行う際、内側支持機構解離に影響する因子は、FTA の程度と屈曲拘縮の程度であると考えた。

東邦医学会誌 59(6) : 297-304, 2012

索引用語 : 変形性関節症, 人工膝関節全置換術, 内側側副靭帯, 靭帯バランス

1) 〒153-8515 東京都目黒区大橋 2-17-6

2, 3) 〒160-8582 東京都新宿区信濃町 35

東邦医学会雑誌 第 59 巻第 6 号, 2012 年 11 月 1 日

ISSN 0040-8670, CODEN: TOIZAG