

**Case Report**

# Bradycardia-Tachycardia Syndrome Detected by an Implantable Loop Recorder in a Patient with Syncope and Paroxysmal Atrial Fibrillation

Tadashi Fujino\* Takanori Ikeda Hitomi Yuzawa  
Hideyuki Sato Atsuko Abe Shunji Fukunaga  
Kenzaburo Kobayashi Yoshifumi Okano and Junichi Yamazaki

Division of Cardiovascular Medicine, Department of Internal Medicine (Omori), School of Medicine,  
Faculty of Medicine, Toho University

---

**ABSTRACT:** We describe a case of frequent unexplained syncopal episodes in a patient with negative results on conventional evaluations that was ultimately diagnosed with the use of an implantable loop recorder (ILR). An 83-year-old woman with a history of several presyncopal episodes was admitted to our hospital for a comprehensive evaluation. Findings from 12-lead electrocardiography (ECG), an electrophysiological study (EPS), and a tilt test were normal. Because she remained undiagnosed for 10 months, we implanted an ILR. Four months after implantation, paroxysmal atrial fibrillation (PAF) and atrial fibrillation (AF)/flutter followed by sinus arrest were captured, and these events corresponded to syncopal episodes. A diagnosis of bradycardia-tachycardia syndrome (BTS) was ultimately confirmed. The patient's quality of life (QOL) has substantially improved after pacemaker implantation, with no recurrence of syncope.

**J Med Soc Toho 59 (2): 68-72, 2012**

---

**KEYWORDS:** syncope, implantable loop recorder (ILR), bradycardia-tachycardia syndrome (BTS)

Syncope is common in the general population, and about 18% to 30% of patients with syncope remain undiagnosed.<sup>1-3)</sup> Electrocardiography (ECG) is frequently used to screen for cardiac disease, but the diagnostic yield is low. Holter monitoring was believed to be the only diagnostic tool that could provide a certain diagnosis. An electrophysiological study (EPS) was considered to be the key investigative method in patients with syncope. However, the sensitivity for paroxysmal sinus node dysfunction was very low at 37.5%.<sup>4)</sup> Tilt testing was also considered to be essential in the diagnosis of syncope. Although its specificity is approximately 90%, its sensitivity is approximately 50%. The diagnostic value of tilt testing is thus limited.<sup>5)</sup>

Implantable loop recorders (ILRs) were finally introduced in Japan in October 2009 and are expected to assist in the diagnosis of patients with unexplained syncope.

## Case Report

The patient was an 83-year-old woman who was receiving treatment for hypertension at a nearby hospital. She had had several presyncopal episodes, starting in December 2008, and had undergone 11 days of in-hospital evaluation at that center. However, after that comprehensive evaluation, which included EPS and tilt testing, the cause of the presyncope remained unexplained. Paroxysmal atrial fibrillation (PAF) without sinus arrest was detected

---

6-11-1 Omorinishi, Ota, Tokyo 143-8541

\*Corresponding Author: tel: 03 (3762) 4151

e-mail: fujino1101@med.toho-u.ac.jp

Received Nov. 30, 2011; Accepted Jan. 5, 2012

Journal of the Medical Society of Toho University

59 (2), Mar. 1, 2012. ISSN 0040-8670, CODEN: TOIZAG

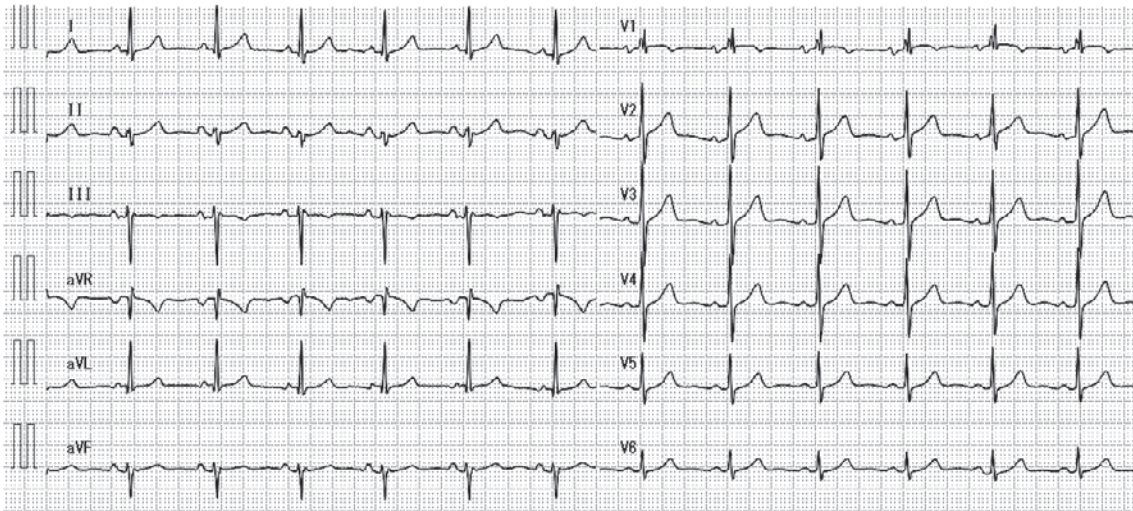


Fig. 1 A surface 12-lead electrocardiogram (ECG) on admission. The heart rate was 78 beats/minute. No ST-segment changes were seen in any leads. The PR interval was normal.

once on in-hospital monitoring, and anti-coagulation therapy was started. However, she continued to experience presyncope events when she bent forward at her torso or exerted herself. She was referred to our hospital in August 2009. In the middle of September, she had the first syncope episode, which was witnessed by her family. She was admitted to our hospital for comprehensive evaluation in early October.

The results of blood testing, 12-lead ECG (Fig. 1), and chest X-ray were normal. Coronary angiography, EPS, tilt test, carotid sinus massage, head magnetic resonance imaging (MRI), head computed tomography (CT), and electroencephalography (EEG) were performed again in our hospital, but all tests were negative. The maximum sinus node recovery time (SNRT) was 1155 msec. Additionally, we used pharmacologic denervation (administration of atropine 0.04 mg/kg and isoproterenol 0.2 mg/kg) to assess the SNRT. However, it was not prolonged (1285 msec). She underwent Holter monitoring every other month after the syncope. However, only PAF lasting 1 to 2 minutes was captured. Anticoagulation therapy was continued for the treatment of atrial fibrillation (AF), but she did not undergo medical treatment for the bradyarrhythmias.

She continued to have frequent unexplained presyncope episodes. Thus, we decided to implant an ILR (Reveal<sup>®</sup> DX Model 9528; Medtronic, Inc., Minneapolis, MN, USA). No arrhythmias were detected by the ILR for 4 months. In the middle of February 2010 (4 months after implantation), PAF and AF/flutter followed by sinus arrest were captured twice. One was a 5.8-second pause (Fig. 2) that corre-

sponded to a syncope event. Another was a 3.6-second pause that corresponded to a presyncope event. Because of the correlation of ECG findings and symptoms, a diagnosis of bradycardia-tachycardia syndrome (BTS) was confirmed. We removed the ILR and performed right atrial isthmus ablation and pacemaker implantation (PMI). The cavotricuspid isthmus ablation was also performed before the right ventricular pacing lead was placed, because both common atrial flutter and PAF had been occasionally recorded. During PMI, sinus-node function was again evaluated with pacing, and SNRT was normal. The patient had no syncope for a year, even though PAF was detected several times on the pacemaker recordings. Her quality of life (QOL), including her symptoms, also improved after PMI.

## Discussion

The tilt test and EPS have been used to evaluate patients with unexplained syncope when a cardiac cause was suspected. However, it was already reported in 2001 that the diagnostic rate of ILR monitoring was better than that of conventional tests, including tilt testing and EPS.<sup>6</sup> In addition, patients with 4 to 6 syncope events during the previous 2 years had a 50% risk of syncope recurrence in the next 2 years.<sup>7</sup> Furthermore, pooled data from 9 studies of a total of 506 patients with unexplained syncope showed that a diagnosis based on ECG documented by ILR was obtained in 35% of patients, among whom 56% had asystole or bradycardia and 11% had tachycardia.<sup>7</sup> In the present case, it would have been difficult to determine the cause of syncope by using conventional tests because the duration

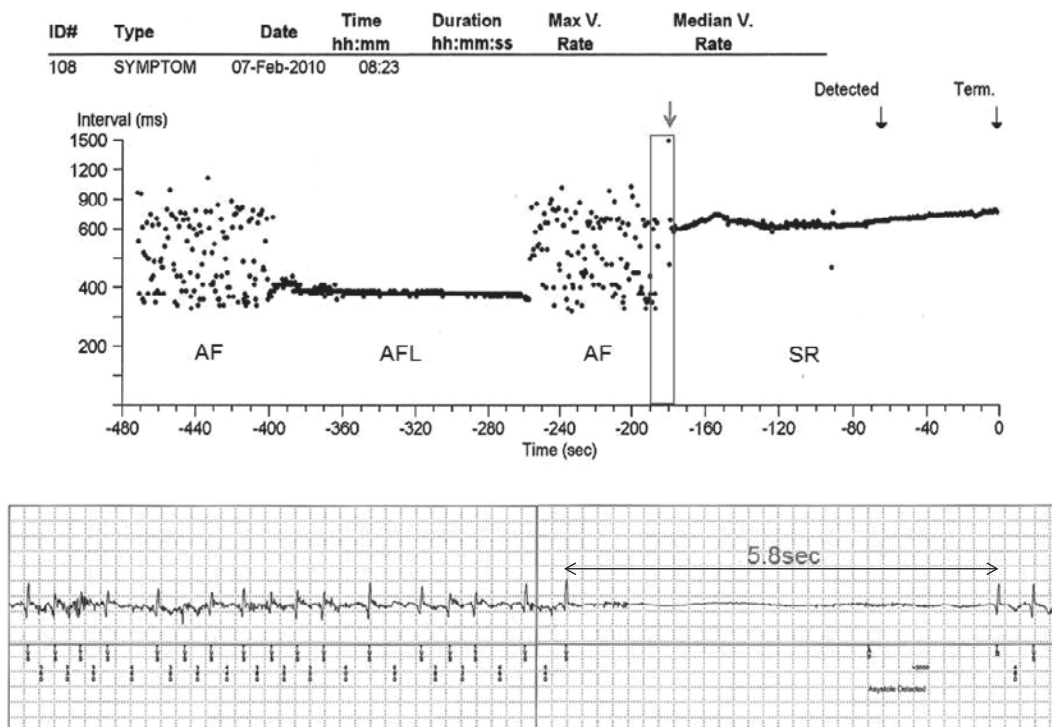


Fig. 2 Automatic activation of the implantable loop recorder by the patient after a syncopal episode. Atrial fibrillation (AF) with a rapid ventricular response was recorded, followed by a pause of 5.8 seconds. AFL: atrial flutter, SR: sinus rhythm

of the captured paroxysmal atrial fibrillation and/or flutter (PAF/PAFL) was shorter than 3 minutes. Her condition resembled sick sinus syndrome, on the basis of clinical features, including age, events triggered by quick posture changes, and PAF, but a definitive diagnosis could not be established. It is difficult to obtain a diagnosis with conventional tests in a case such as this because the sensitivity of EPS for sick sinus syndrome is low, due to the effect of the autonomic nervous system.

This case confirms that ILR is suitable for patients with recurrent, frequent syncopal episodes during a short period, if an arrhythmic cause is likely and they have normal heart function, no significant abnormal ECGs, and no family history. Actually, in the literature, 10% to 17% of ILR diagnoses were sick sinus syndrome.<sup>8-10</sup> Despite comprehensive evaluation at 2 hospitals, no definitive diagnosis could be obtained despite the considerable time and cost of the evaluations, which indicates that ILR is more cost-effective than conventional tests.<sup>11</sup> Indeed, an ILR probably should have been used early in the evaluations.

### Conclusion

We reported a case of frequent unexplained syncopal episodes, with negative findings on conventional tests, that

was successfully diagnosed by using an ILR. The patient's QOL improved substantially after PMI. Syncope and dizziness have not recurred as of 1 year after PMI.

### References

- 1) Krahn AD, Klein GJ, Yee R, et al: Final results from a pilot study with an implantable loop recorder to determine the etiology of syncope in patients with negative noninvasive and invasive testing. *Am J Cardiol* **82**: 117-119, 1998
- 2) Krahn AD, Klein GJ, Yee R, et al: Use of an extended monitoring strategy in patients with problematic syncope. *Reveal Investigators. Circulation* **99**: 406-410, 1999
- 3) Alboni P, Brignole M, Menozzi C, et al: Diagnostic value of history in patients with syncope with or without heart disease. *J Am Coll Cardiol* **37**: 1921-1928, 2001
- 4) Fujimura O, Yee R, Klein GJ, et al: The diagnostic sensitivity of electrophysiologic testing in patients with syncope caused by transient bradycardia. *N Engl J Med* **321**: 1703-1707, 1989
- 5) Stein KM, Slotwiner DJ, Mittal S, et al: Formal analysis of the optimal duration of tilt testing for the diagnosis of neurally mediated syncope. *Am Heart J* **141**: 282-288, 2001
- 6) Krahn AD, Klein GJ, Yee R, et al: Randomized assessment of syncope trial: Conventional diagnostic testing versus a prolonged monitoring strategy. *Circulation* **104**: 46-51, 2001
- 7) Task Force members, Brignole M, Vardas P, Hoffman E, et al: EHRA Scientific Documents Committee: Indications for the use of diagnostic implantable and external ECG loop recorders. *Europace* **11**: 671-687, 2009
- 8) Boersma L, Mont L, Sionis A, et al: Value of the implantable loop

- recorder for the management of patients with unexplained syncope. *Europace* **6**: 70–76, 2004
- 9) Brignole M, Sutton R, Menozzi C, et al.: International Study on Syncope of Uncertain Etiology 2 (ISSUE2) Group: Early application of an implantable loop recorder allows effective specific therapy in patients with recurrent suspected neurally mediated syncope. *Eur Heart J* **27**: 1085–1092, 2006
- 10) Pierre B, Fauchier L, Breard G, et al.: Implantable loop recorder for recurrent syncope: Influence of cardiac conduction abnormalities showing up on resting electrocardiogram and of underlying cardiac disease on follow-up developments. *Europace* **10**: 477–481, 2008
- 11) Krahn AD, Klein GJ, Yee R, et al.: Cost implication of testing strategy in patients with syncope: Randomized assessment of syncope trial. *J Am Coll Cardiol* **42**: 495–501, 2003

# 失神の診断に難渋し植え込み型ループレコーダ (ILR) から 徐脈頻脈症候群への診断に至った1例

藤野 紀之      池田 隆徳      湯澤ひとみ  
佐藤 秀之      阿部 敦子      福永 俊二  
小林建三郎      岡野 喜史      山崎 純一

東邦大学医学部内科講座 (大森) 循環器内科

---

**要約**：症例は、前失神発作を何度も認め、前医で診断に至らなかった83歳の女性。Holter心電図、12誘導心電図、Tilt試験、電気生理学検査 (electrophysiological study : EPS) 等の従来の検査を再度当院で行ったが、すべて正常であった。初発発作を認めてから10カ月間診断に至らず、失神を認めるため植え込み型ループレコーダ (implantable loop recorder : ILR) を植え込む方針とした。植え込み4カ月後に失神し、ILRで心房粗細動とその停止後に5.8秒の洞停止を認め、初めて「徐脈頻脈症候群」と診断した。診断後すぐにペースメーカー植え込み術を行い、術後は1度も失神せずに経過している。今回、従来の検査では診断できず、ILR植え込みにより診断に繋がった徐脈頻脈症候群の1例を経験したので、症例報告する。

東邦医会誌 59(2) : 68-72, 2012

---

**索引用語**：失神, 植え込み型イベントレコーダー (ILR), 徐脈頻脈症候群